

Round Acupuncture for the Treatment of Recurrent Carpal Tunnel Syndrome

Ju-ran Kim¹, Yun Kyu Lee¹, Hyun-Jong Lee¹, Jae Soo Kim^{1*}

¹ Department of Acupuncture & Moxibustion medicine, College of Korean medicine, Daegu Haany University, Republic of Korea

Key Words

Round Acupuncture, recurrent carpal tunnel syndrome, carpal tunnel syndrome

Abstract

Objectives: Round Acupuncture having blunt end has developed from acupotomy. This case report is to find out that Round Acupuncture is effective in treating patients with recurrent carpal tunnel syndrome (CTS), which has not improved by steroid injection or acupotomy.

Methods: Round Acupuncture was inserted into the distal fibers of transverse carpal ligament and released toward the proximal fibers. Treatment was performed three times in total. Tingling, numbness, night pain and swelling sensation were assessed, and provocative maneuvers were also used.

Results: After treatment, all symptoms completely disappeared and the patient had no recurrence until 3 months after treatment.

Conclusion: Round Acupuncture could be an effective treatment for recurrent CTS.

1. Introduction

Carpal tunnel syndrome(CTS) is the most frequent compression neuropathy in the hand [1]. It causes

symptoms such as numbness, tingling, pain, abnormal sense and muscular atrophy of the thenar area in the median nerve region of the hand [2]. CTS is more prevalent in females than males, and the average age is 40 to 60 years [3]. Although the exact cause is unknown, CTS can occur when mechanical stress or increased compression force decreases the space of the carpal tunnel and compresses the median nerve [3, 4]. In addition, it can secondarily occur due to diabetes or pregnancy [3].

CTS is primarily administered conservative treatment through drug, injection such as steroid, splint treatment, etc. But if the symptoms are severe or the improvement is insignificant, surgery is considered [3]. Surgery is often performed with a carpal tunnel release (CTR), with a 75 - 90% success rate. CTR is a surgery to cut the transverse carpal ligament (TCL) to reduce the pressure in the carpal tunnel and create more space [5]. Complications or failure rates after CTR have been reported as 3 - 19%. The failure of treatment after the first CTR is defined as recurrent CTS and is classified as persistent, recurrent, or new CTS [1,6]. These patients require revision surgery but results following revision surgery are disappointing, with up to 40% as unfavorable and up to 95% having persistent symptoms [7]. There are no papers on recurrent CTS in Korean oriental medicine. In medicine, most of papers have been reported on revision surgery using flap, or a review about recurrent CTS [1, 8]. This suggests that there is no clear treatment for patients with recurrent CTS.

Round Acupuncture is one of the 'nine classical needles', with columnar body and having round and egg shaped end. It is about 42mm long and is primarily said to have been used to massage between muscles

Received: Nov 11, 2019 Reviewed: Feb 21, 2020 Accepted: Feb 25, 2020

[9]. The Round Acupuncture used in this paper is a needle designed based on the Round Acupuncture written in the literature and the acupotomy. In this paper, we report a case of recurrent CTS patient who completely improved using Round Acupuncture, with no improvement through steroid injection and acupotomy before.

2. Case report

A 55-year-old woman had experienced CTR for bilateral CTS nine years ago. There were no other medical, family, and psycho social history including relevant genetic information. After CTR, symptoms disappeared, but right CTS recurred after using the right wrist excessively. She received one steroid injection and two times of acupotomy,

but there was no improvement. So she was treated by using Round Acupuncture. Round Acupuncture made by Dongbang medical company, is 0.8mm in diameter, 105 mm in overall length, 80 mm in length of needle body, and 25 mm in length of handle and with a round end (Fig. 1).

The operator wore a disposable mask and surgical latex gloves, and sterilized with boric acid 2% and povidone iodine 9 - 12% at 0.5 cm outside of PC 7 (Round acupoint), located on the proximal fibers of TCL (Fig.2). Without anesthesia with the patient's consent, the acupotomy first pierced through the skin at Round acupoint and then used Round Acupuncture toward the distal fibers of TCL in all directions at the same site (Fig. 3). This procedure released the scar and adhesion of the TCL and loosened the lesion tissue.

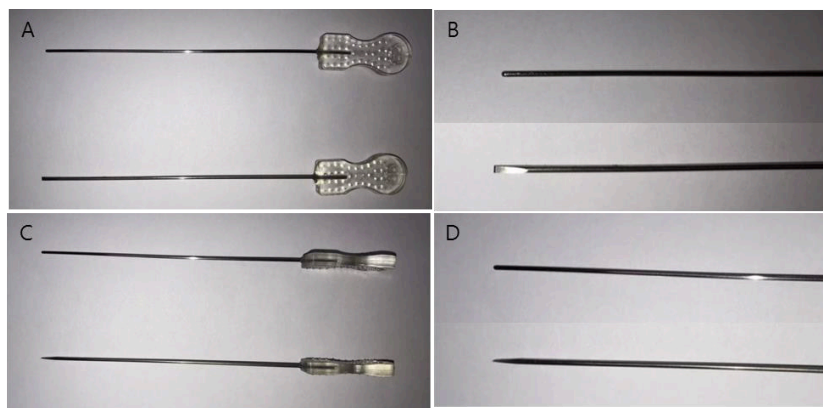


Figure 1 Round Acupuncture and acupotomy

In all the images, the above one is Round Acupuncture and the below one is acupotomy. A and B are acupunctures from the front C and D are acupunctures from the side.

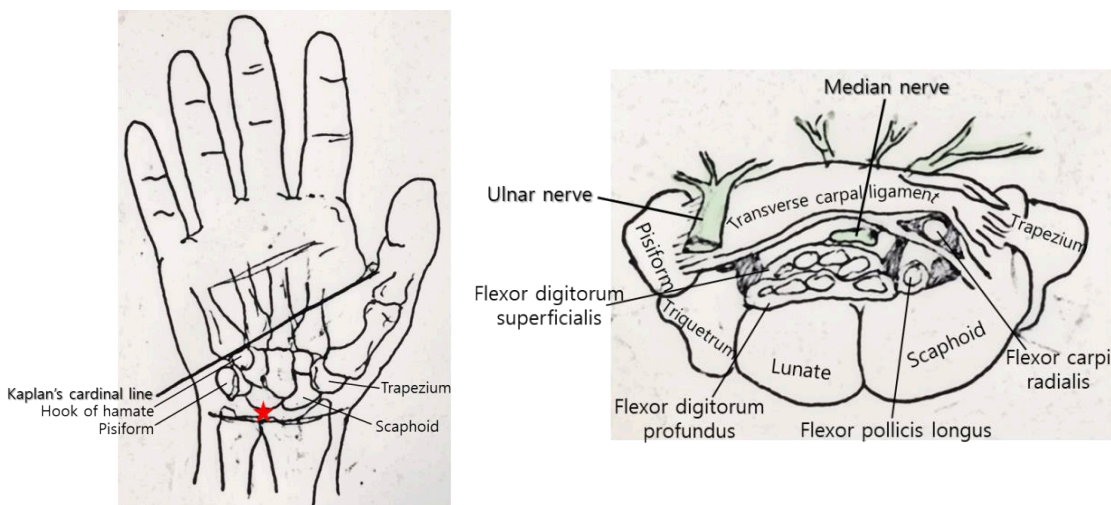


Figure 2 Round acupoint (A) and cross sectional view (B) of the carpal tunnel

A: Kaplan's cardinal line is from the first web space parallel to the proximal transverse palmar crease. Round acupoint is marked with star. B: B is a cross sectional view of the carpal tunnel. When treating the carpal tunnel syndrome, be careful of median nerve and ulnar nerve.

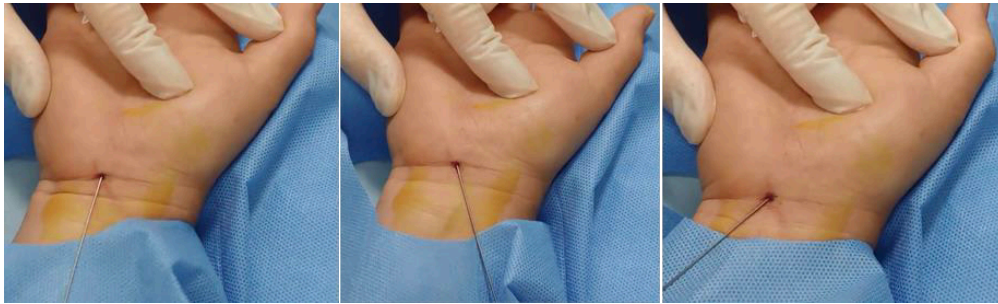


Figure 3 Procedure of releasing the transverse carpal ligament with the Round Acupuncture

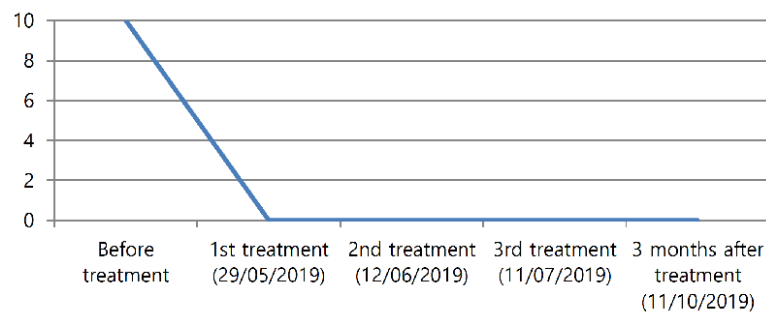


Figure 4 The change of visual analogue scale about the patient's night pain during treatment

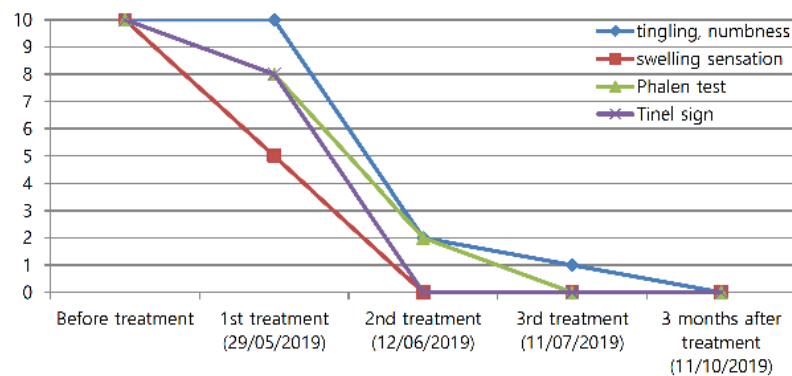


Figure 5 The change of numeral rating scale about the patient's symptoms during treatment period

Patients complained of tingling, numbness, night pain, and swelling sensation, and were positive in the Phalen test and Tinel sign. Before and after treatment, the patient's night pain was assessed using the Visual Analogue Scale, and tingling, numbness, and swelling sensation were assessed using the Numeral Rating Scale (NRS). NRS assessed the patient's symptoms by setting 0 for when the patient felt there're no symptoms and 10 for when the patient felt unbearable. The Phalen test and Tinel sign used NRS to observe the degree of tingling during the test. During the procedure of the Round Acupuncture, no other treatment was performed and the treatment was per-

formed three times in total.

After the first treatment, night pain completely disappeared (Fig. 4), swelling sensation was reduced by half, but tingling and numbness didn't improve. After the second treatment, two weeks after the first treatment, the Phalen test, Tinel sign, and swelling sensation were completely disappeared, and tingling and numbness fell from 10 to 2 in NRS. After the third treatment, six weeks after the first treatment, some tingling and numbness remained, but all symptoms disappeared a month after the last treatment (Fig. 5). It also remained unrecurred until three months after the last treatment.

3. Discussion

Recurrent CTS refers to a case when treatment fails after the first CTR. It's classified as persistent, recurrent, or new [1]. Persistent is a case where there is no symptom improvement immediately after CTR because TCL is not released completely. 'Recurrent' is a case where the symptoms disappear temporarily after CTR, but reoccur by TLC fibrosis or reconstitution after about 6 months. 'New' is a case where new symptoms occur that the patient didn't have before, after CTR [10,11]. These patients require revision surgery, but 40% of patients are unfavorable and up to 95% have persistent symptoms [7]. Because of the low success rate of revision surgery, both patients and doctors feel the burden with revision. There have been many efforts to release the fibrous tissue of the TCL with minimal invasion. Therefore, in medicine, incision of the carpal tunnel using scalpel blade or flap surgery are performed to prevent postoperative complications and recurrence [12, 13]. But there is still no clear treatment for recurrent CTS.

In this case, Round Acupuncture was performed in a recurrent CTS patient who didn't improve after steroid injection and acupotomy. Round acupoint was on the TCL, which is the most problematic site. TCL is the ligament between the ulnar sided hamate and pisiform bones and the radial sided scaphoid and trapezium bones [14]. CTR is most frequently performed at the distal fibers of TCL, especially at the point, regarded as safety zone, where the Kaplan's cardinal line meets the ulnar border of the ring finger. In addition, CTR can be also applied to the proximal fibers of TCL when symptoms are severe or confirmed there is a adhesion in the proximal region [6, 5, 16]. So, Round Acupuncture was performed by releasing the TCL toward the distal fibers of TCL in all directions (toward the hamate, pisiform, scaphoid and trapezium) at Round acupoint, which is the proximal region of TCL. Through this procedure, the adhered part of TCL was released to expand the narrow space. As a result, the patient's symptoms completely disappeared and the patient's satisfaction was also very high. Also, the patient lived well without recurrence until three months after treatment.

Recently, blunt cannula has been reported to be more effective than Nokor needle for acne scar treatment in terms of complications and satisfaction rates [In line with this, because Round Acupuncture has blunt end, unlike the acupotomy, it can be expected to be more effective in the treatment. On the other hand, Bigeleisen et al. [18] reported that no nerve injury occurred in any of the 22 patients when 22 gauge needles were inserted directly into the axillary part of the patient under ultrasound guidance. And, they also revealed that when the needle touched the nerve, the nerve moved about 1 - 2 cm. In addition, since half of the nerve consists of connective and adipose tissue, and the other half consists of bundles of nerves, suggesting that needle contact with nerve does not lead to immediate nerve damage. The most common complication of acupotomy is nerve damage. But, it's considered that there will be no nerve damage if the needle is inserted in a direction parallel to the nerve, and if the needle stimulated the nerve, retreat and reinject. If we use acupotomy to treat the CTS, we should be concerned about damage to

the ulnar and median nerve. However, in the case of the Round Acupuncture, the end is blunt unlike acupotomy. So, it's thought to be safer from the risk of nerve damage. There have been many efforts to develop treatments with minimal invasion to reduce the burden on patients and to reduce side effects such as scars and adhesions after surgery. That is, it is thought that the Round Acupuncture may be an alternative in terms of safety and efficacy.

However, since there are no reports on the Round Acupuncture, it's considered that large scale follow up studies will be needed to prove the efficacy, safety and repeatability of the Round Acupuncture. In addition, there is no comparison with other treatments directly, and it is difficult to generalize because of only one case. But, since only Round Acupuncture used to treat the CTS and obtained an effective result, it is expected to be a new treatment method with minimal invasion compared to the existing treatment.

Conflicts of interest

The authors declare no conflict of interest regarding the publication of this article.

Patient consent

Obtained. This paper was retrospective study, and got a formal review and waiver by institutional review board of Daegu Haany University Korean Medicine Hospital (grant number: DHUMC-D-19021-ETC-01)

Funding/Support

This paper was supported by a grant of the Korea Health Technology R&D Project through the Korea Health Industry Development Institute (KHIDI), funded by the Ministry of Health & Welfare, Republic of Korea (grant number: HI18C1947010019).

ORCID

Ju-ran Kim. 0000-0001-5777-8276

Yun Kyu Lee. 0000-0001-8806-9501

Hyun-Jong Lee. 0000-0003-1260-0778

Jae Soo Kim. 0000-0003-4101-8058

References

1. Mosier BA, Hughes TB. Recurrent carpal tunnel syndrome. *Hand Clin.* 2013;29(3):427-34.
2. Phalen GS. The carpal tunnel syndrome. Seventeen years' experience in diagnosis and treatment of six hundred fifty four hands. *J Bone Joint Surg Am.* 1966;48(2):211-28.
3. Zamborsky R, Kokavec M, Simko L, Bohac M. Carpal Tunnel Syndrome: Symptoms, Causes and Treatment Options. *Literature Review. Ortop Traumatol Reh abil.* 2017;19(1):1-8.
4. Uchiyama S, Itsubo T, Nakamura K, Kato H, Yasutomi T, Momose T. Current concepts of carpal tunnel syn-

- drome: pathophysiology, treatment, and evaluation. *J Orthop Sci.* 2010 ;15(1):1-13.
5. Louie D, Earp B, Blazar P. Long term outcomes of carpal tunnel release: a critical review of the literature. *Hand (N Y).* 2012 ;7(3):242-6.
 6. Stütz N, Gohritz A, van Schoonhoven J, Lanz U. Revision surgery after carpal tunnel release analysis of the pathology in 200 cases during a 2 year period. *J Hand Surg Br.* 2006 ;31(1):68-71.
 7. Tollestrup T, Berg C, Netscher D. Management of distal traumatic median nerve painful neuromas and of recurrent carpal tunnel syndrome: hypothenar fat pad flap. *J Hand Surg Am.* 2010 ;35(6):1010-4.
 8. Hutting KH, van Uchel en JH. Treatment of Recurrent and Persistent Carpal Tunnel Syndrome: The Fasciocutaneous Dorsal Ulnar Artery Flap. *J Hand Surg Am.* 2018 ;43(7):686.e1-686.e5.
 9. Sohn IC, Kwon OS, Kim YL, Ahn SH, Kim JH. Literature study on the conformation and application of nine classical needles. *Korean Journal of Acupuncture.* 2011;28(1):157-69.
 10. Tung TH, Mackinnon SE. Secondary carpal tunnel surgery. *Plast Reconstr Surg.* 2001 ;107(7):1830-43.
 11. Zieske L, Ebersole GC, Davidge K, Fox I, Mackinnon SE. Revision carpal tunnel surgery: a 10 year review of intraoperative findings and outcomes. *J Hand Surg Am.* 2013 ;38(8):1530-9.
 12. Boya H, Özcan Ö, Özteki N HH. Long term complications of open carpal tunnel release. *Muscle Nerve.* 2008 ;38(5):1443-6.
 13. Kwon YJ. Limited mini open carpal tunnel release. *Korean J Spine.* 2008;5(1):18-23.
 14. Vanhees M, Verstreken F, van Riet R. What does the transverse carpal ligament contribute to carpal stability? *J Wrist Surg.* 2015 ;4(1):31-4.
 15. Panchal AP, Trzeciak MA. The Clinical Application of Kaplan's Cardinal Line as a Surface Marker for the Superficial Palmar Arch. *Hand (N Y).* 2010 ;5(2):155-9.
 16. Jones NF, Ahn HC, Eo S. Revision surgery for persistent and recurrent carpal tunnel syndrome and for failed carpal tunnel release. *Plast Reconstr Surg.* 2012 ;129(3):683-92.
 17. Gheisari M, Iranmanesh B, Saghi B. Blunt cannula subcision is more effective than Nokor needle subcision for acne scars treatment. *J Cosmet Dermatol.* 2019 ;18(1):192-6.
 18. Bigeleisen PE. Nerve puncture and apparent intraneural injection during ultrasound guided axillary block does not invariably result in neurologic injury. *Anesthesiology.* 2006 ;105(4):779-83.