



Case Report

Effects of Korean Medicine Treatment on a Patient with Functional Scoliosis with an Abnormal Gait Pattern After Hip Injury: A Case Report



Yu-Mi Gi^{1,*}, Tae-Gyu Kim¹, Hoo-In Jo¹, Jong-Ho Choi¹, Eun-Young Park¹, Soo-Kyung Lee¹, June-Haeng Lee¹, Min-Kyu Kim², Keun-Jae Lee², Ok-Cheol Yu³

1 Department of Acupuncture and Moxibustion, Jaseng Hospital of Korean Medicine, Seoul, Korea

2 Department of Korean Medicine Rehabilitation, Jaseng Hospital of Korean Medicine, Seoul, Korea

3 Department of Oriental Neuropsychiatry, Jaseng Hospital of Korean Medicine, Seoul, Korea

ABSTRACT

Article history:

Submitted: September 18, 2019

Revised: October 2, 2019

Accepted: October 15, 2019

Keywords:

traditional medicine, Korean, scoliosis, acupuncture therapy, manual therapy, foot orthosis

Scoliosis is a 3-dimensional spinal deformity defined as lateral curvature of the spine in the coronal plane of more than 10°. This study describes a case of functional scoliosis after hip injury. In this case, the patient fell whilst inline skating (June 2015) causing severe tilting of her spine, and left hip pain. She received outpatient treatment from July 14, 2015 to December 28, 2015. For approximately 5 months, acupuncture therapy was performed to relax the tension in both hips, Chuna therapy, and foot orthosis were applied to reduce the body's imbalance. Based on X-ray images, the Cobb angle had decreased from 14.73° (pretreatment) to 1.90° (posttreatment). This case report suggested that Korean medicine treatment could be an effective therapeutic choice for functional scoliosis.

<https://doi.org/10.13045/jar.2019.00213>
pISSN 2586-288X eISSN 2586-2898

©2019 Korean Acupuncture & Moxibustion Medicine Society. This is an open access article under the CC BY-NC-ND license (<http://creativecommons.org/licenses/by-nc-nd/4.0/>).

Introduction

Scoliosis is a 3-dimensional spinal deformity where lateral curvature of the spine in the coronal plane is more than 10° [1] and it is one of the most common types of spinal deformities. It is classified (structural, non-structural) according to the shape and reversibility of the curvature. Non-structural scoliosis (functional scoliosis), is reversible in curvature and is not accompanied by rotational and asymmetrical changes in the vertebral body. It is caused by temporary postural instability or pelvic inclination, due to a difference in leg length and it is usually treated by correcting the underlying causes [2]. Structural scoliosis is accompanied by a morphological change. Scoliosis of unknown origin idiopathic accounts for 85% of cases of structural scoliosis [3].

Orthotic therapy, exercise therapy, and surgery may be offered in the treatment of scoliosis, depending upon the degree of

scoliosis [4], and structural improvement of scoliosis is observed radiographically. In Korean medicine, conservative treatments for scoliosis such as acupuncture therapy [5], Chuna therapy [6], and exercise therapy [7] are performed. Patients who do not require or want surgery, visit Korean medicine hospitals. Therefore, Korean medicine treatment of scoliosis needs to be comprehensive and systematic [8]. Although there have been several studies of scoliosis treated with Korean medicine, most reports are concerned with idiopathic scoliosis. More published cases of functional scoliosis are needed. The methods that have been used to treat functional scoliosis include a developed McKenzie Method by Kim et al [9], induced lateral pelvic tilting using the ashi points of the muscles to treat functional scoliosis [10], and fascial relaxation therapy which was shown to improve the degree of pelvic inclination and functional scoliosis [11].

In this study, the results of a patient who was diagnosed with

*Corresponding author.
Department of Acupuncture and Moxibustion, Jaseng Hospital of Korean Medicine, Seoul, Korea
E-mail : yumigi71@jaseng.co.kr
ORCID : Yu-Mi Gi <https://orcid.org/0000-0003-3996-5865>

functional scoliosis after hip injury and was treated with Korean medicine at a Jaseng Korean medicine hospital, were reported.

Case Report

Medical history

An 8-year-old female presented with severe tilting of her spine which caused difficulty assuming a sitting position, and left hip pain which limited her gait resulting in difficulty in running or walking fast. The patient's spine and pelvis were tilted.

In June 2015, the patient fell whilst inline skating, and that was when her symptoms began. She had an X-ray at a local orthopedic surgery and was diagnosed as having a "hip problem" and was treated with analgesics to relieve the pain. A few days later, the patient visited the Severance Hospital and had computed tomography and sonography scans and was informed there was no big problem. The patient took pain relief and underwent physical therapy and acupuncture therapy for 1 month. However, the pain did not subside, and the scoliosis worsened. The patient visited the Jaseng hospital of Korean Medicine on July 14, 2015.

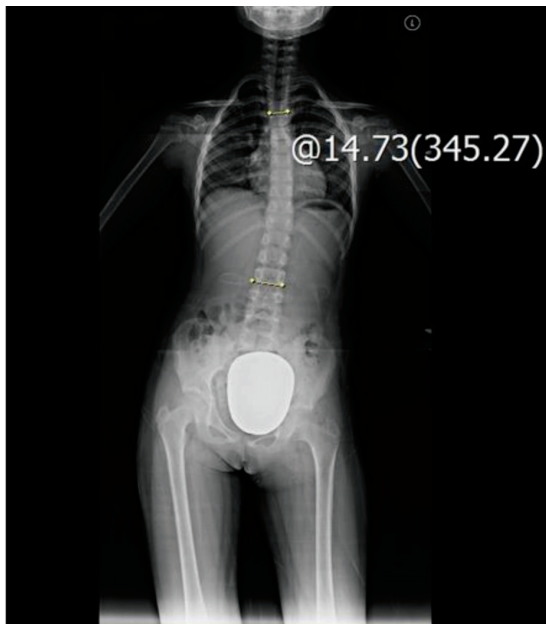

Fig. 1. Whole spine x-ray (July 14, 2015). The image shows scoliosis of the thoracolumbar spine curvature (left side) and 14.73° Cobb angle.

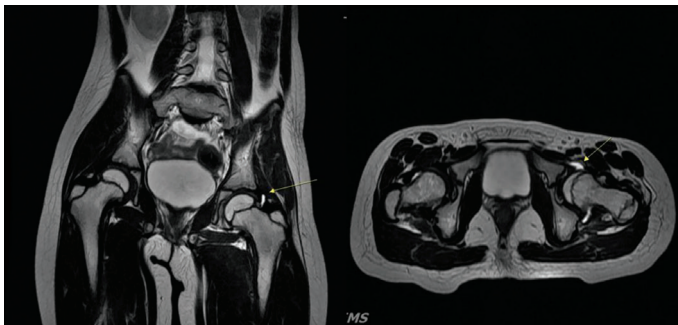


Fig. 2. Magnetic resonance imaging (July 18, 2015). Both hips show an over coverage of the left acetabulum and prominent joint effusion in the left hip joint (arrow).

Radiography and magnetic resonance imaging results

On July 14, 2015, the patient underwent a whole spine X-ray. No significant bony abnormality was noted, but left-side scoliosis with thoracolumbar spine curvature, and associated pelvic height differences were noted (Fig. 1). On July 18, 2015, the patient underwent X-ray and magnetic resonance imaging of both hips. Over coverage of the left acetabulum and prominent joint effusion in the left hip joint were noted. However, there were no remarkable abnormalities at her left labrum (Fig. 2). To evaluate the scoliotic angle throughout the treatment, 4 whole spine X-rays were performed (Fig. 3).

Treatment methods

Acupuncture therapy

The needles were 0.25 × 40 mm stainless steel needles (The Eastern Acupuncture Equipment Manufacturer, Boryung, Korea), standardized, and disposable. Electro-acupuncture (1 Hz) was performed twice a week, for 15-minutes at GB29, GB30, GB31 and the lateral line of the myofascial track for the duration of the treatment.

Herbal medicine

Herbal medicine was prescribed for the patient's chief complaints of severe tilting of her spine and hip pain, and any further symptoms early in the treatment. Decoction of Shogunjung-tang helped her muscles relax and treated symptoms of anorexia. The prescribed decoction for the patient was made at the Jaseng Hospital of Korean Medicine. The schedule, daily doses and herbal

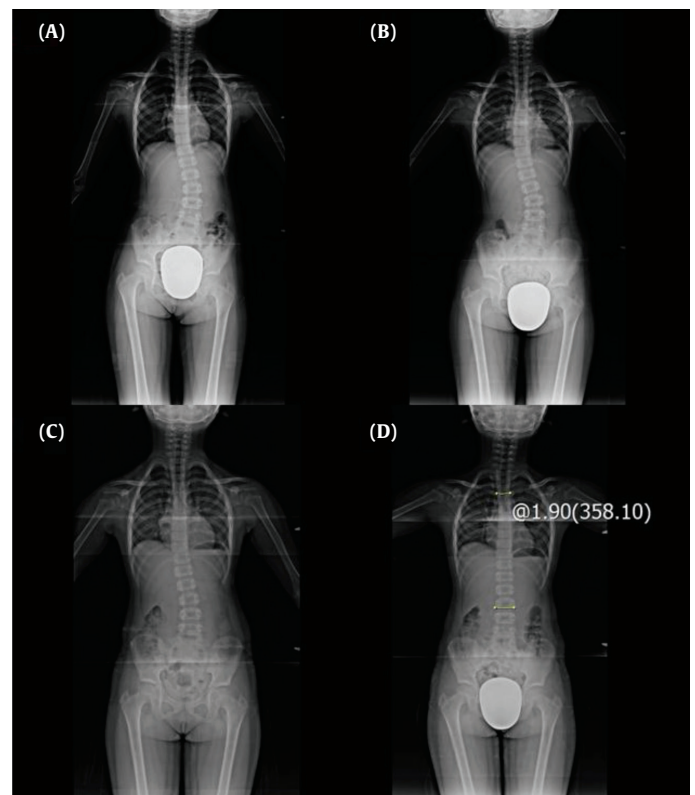


Fig. 3. Radiograph images during the 5-month course of treatment. (A) 2015.08.18, (B) 2015.09.04, (C) 2015.10.16, (D) 2015.12.18 (Cobb angle: 1.90°).

Table 1. Traditional Korean Medicine Herbal Prescriptions Administered to the Patient.

Herbal prescription	Herbal components (g)	Administered	Daily dose
Shogunjung-tang	Saccarum Granorum 20 Radix Paeoniae Lactiflorae 20 Cinnamomum louerii Nees 12 Rhizoma Zingiberis 6 Radix Glycyrrhizae 4	Day 1 to Day 15	Extract of 120 mL, 3 × /d

ingredients are described in Table 1.

Chuna therapy

The patient underwent Chuna therapy for the 5-month treatment period. Chuna therapy was performed for 10 to 15-minutes to reduce tension, shorten the bilateral femoral muscles, and correct spinal asymmetry. The techniques used included pelvic mobilization, spinal joint distraction, and hip joint articulation.

Foot orthosis

A foot orthosis supports gait instability by mimicking the shape of the patient's foot (a positive cast was formed to mold a sole which could act as a heel lift). The patient was prescribed a foot orthosis and was trained to use it. As her gait balance improved, the height of the heel lift was gradually reduced over the 5-month treatment period. When the gait pattern normalized, the foot orthosis was removed.

Assessment

Numerical Rating Scale

The Numerical Rating Scale (NRS) [12] is used to measure subjective pain. The most pain has a score of 10, and the absence of pain is 0. The patient was evaluated on the first day (July 14, 2015) and the last day of treatment (December 29, 2015).

Cobb angle

On a full length posteroanterior plain radiograph, the magnitude of a scoliosis curvature was determined using the Cobb technique [1,13]. Firstly, it was important to identify the superior and the inferior end vertebrae (the vertebrae with the greatest tilt at the proximal and distal ends of the curve). The angle between them was measured by drawing a line from the top of the superior end vertebra parallel to the upper endplate, and another line from the bottom of the inferior end vertebra parallel to the lower endplate. Perpendicular lines were then constructed at right angles to the lines along the endplates. The angle formed by the intersection of the perpendicular lines was the Cobb angle.

Correctability

Correctability [14] was calculated and used as the index for treatment effect. The percentage was calculated using the Cobb angle from before the treatment as the denominator, and the difference between the angle before and after the treatment as the numerator.

* Correctability (%) = {(angle before treatment-angle after treatment)/angle before treatment} ×100

Ethics statement

In order to protect the patient's personal information, the patient's medical record was obtained from the Institutional Review Board of Jaseng Korean medical hospital (IRB File no.: 2019-09-006).

Progress of the patient under treatment

The NRS score evaluated on the first day (July 14, 2015) was 5. After the first treatment, the patient reported an increased range of hip movement, and reduction at the curvature angle of the spine was noted. When the patient visited for the fourth time, the insole heel lift was applied. After applying of insole heel lift, the gait balance was improved. On August 4, 2015, the patient said that she could perform light running but felt slight pain in both thighs. The patient's gait pattern continued to become smoother until the end of treatment. On October 16, 2015, decrease in the scoliotic angle was observed (Fig. 3C). On November 13, leg length discrepancy was measured and had decreased by approximately 1/2 from the initial visit. On December 18, 2015, the patient underwent a whole spine X-ray, and normal spinal curvature was noted (Fig. 3D), Cobb angle was 1.90°. It was noted that following excessive exercise, the appearance and disappearance of pain in the right hip occurred and this repeated several times. However, by the end of treatment on December 29, 2015, the pain had completely disappeared. The NRS score on the final day was 0 (Fig. 4), and correctability was 87%.

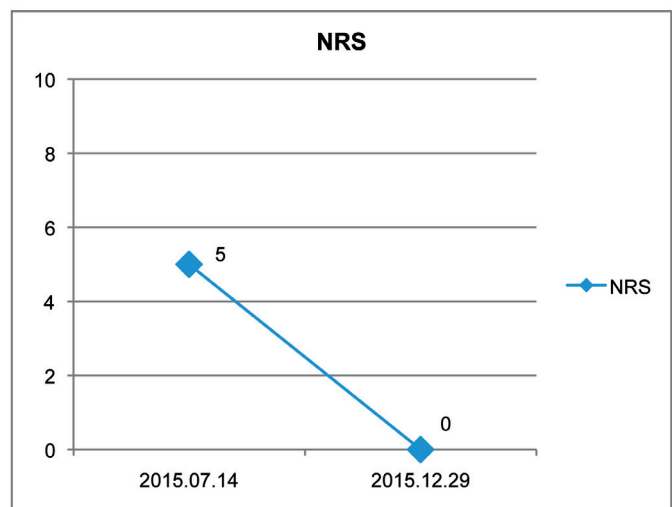


Fig. 4. Changes over time in the numerical rating scale (NRS) score.

Discussion

The primary function of the spine is to support the body weight and appendicular skeleton. Its structure and flexibility allow normal activity whilst maintaining the body's center of gravity at a fairly constant location. Spinal deformity can limit the flexibility of the spine and alter the center of gravity of the body. The location, magnitude, and type of curvature of the spine may affect the plantar weight-bearing pattern. Additionally, bracing and surgical treatment may affect the plantar weight-bearing pattern because they cause changes in magnitude and compensation of curvature [15].

Functional foot orthosis (whilst wearing shoes), allowed direct contact with the sole of the foot, which improved and recovered the abnormality of lower limb musculoskeletal imbalance. This provided primary support for the foot, which enabled support for the weakened region, thereby maintaining a balanced body in a standing position [16]. In a previous study [17], using a shoe lift resulted in acute postural adaptations which specifically affected the spine, and the 3-dimensional position and orientation of the pelvis and shoulder girdle. Recently, efforts in Korean medicine to improve scoliosis by correcting pelvic balance [18] and improving chronic pain by using a foot orthosis have been observed [19]. This study was a case of functional scoliosis where scoliotic curvature developed as a result of compensative postural adaptations, to gain an upright position while avoiding pain. Hence, the static and dynamic stability of the patient's body was improved by decreasing the pelvic height difference in an upright position, and normalizing the height of the medial arch of the foot that created asymmetrical deformation of the pelvis, regardless of the actual leg length.

Chuna manual therapy, a traditional Korean medicine treatment, is a therapeutic modality that addresses biomechanical function, pathology, diagnostics, and theories related to treatment to create a balance in orthopedic structure and function. Chuna states that both function and structure are systemically correlated. Chuna techniques include stimulating the meridian system, correcting the displacement of the osteoarticular structure, and prescribing exercises based on patient-reported symptoms and the results of a functional anatomical assessment. Representative techniques of Chuna are thrust, mobilization, manipulation of the spine and joints, soft tissue release, visceral manipulation, craniosacral therapy, and the diaplasis technique [20].

In this case, the patient fell whilst inline skating in June 2015, and she complained of hip pain and had tilting of the spine. From July 14, 2015 to December 28, 2015, she received outpatient treatment at Jaseng Korean medicine hospital. Inconsistent with idiopathic structural scoliosis, the patient had a hip injury due to an external impact and showed limited physical function. Abnormal posture and gait pattern caused functional scoliosis. For approximately 5 months, acupuncture therapy was applied to relax the tension of both hips, Chuna therapy, and foot orthosis were applied to reduce the body's imbalance. Hence, the NRS score decreased from 5 to 0. Based on the X-ray follow-up, the Cobb angle also decreased from 14.73° to 1.90°, giving a final correctability of 87%.

This study was significant because it was the first study to show the effectiveness of Korean medicine treatment of functional scoliosis resulting from traumatic injury. The patient's symptoms did not improve after physical therapy and pain relief, but showed significant improvement after Korean medicine treatment. The patient in this case had no underlying pathology of the spine, so it was possible to correct the scoliosis by resolving the underlying hip condition. Additionally, foot orthosis supplemented the traditional Korean medicine treatment of electro-acupuncture therapy and Chuna therapy.

For functional scoliosis in patients who do not require surgical treatment, this was a good example of conservative treatment. However, this study was limited to only 1 patient hence, more studies should be conducted. Moreover, a comparison of the single treatments compared with the combination of treatments (acupuncture treatment, Chuna treatment, and foot orthosis) could not be performed. Thus, further study, including control groups is required.

Conflicts of Interest

The authors have no conflicts of interest to declare.

References

- [1] Farhaan A, Alexander G, Zaher D, Hilali N. Adolescent idiopathic scoliosis. *BMJ* 2013;346:30-34.
- [2] Suk SI, Song HS. A Clinical Observation on Idiopathic Scoliosis. *J Korean Orthop Assoc* 1981;16:245-256. [in Korean].
- [3] Suk SI. *Textbook of Spinal Surgery*, 2nd ed. Seoul (Korea): Newmed; 2004. p. 312-344.
- [4] Lee MK, Lee GJ, Song YK, Lim HH. Review on Conservative Treatment of Spinal Scoliosis. *J Korea Chuna Man Med Spine Nerves* 2009;4:103-118. [in Korean].
- [5] Jo JY. Adult Idiopathic Scoliosis Treated by Acupuncture: A case report. *J Korea Chuna Man Med Spine Nerves* 2012;7:21-25.
- [6] Kim Y, Park JM, Yun MS, Kim SY, Sin JS. A Clinical Case Study on Cobb's angle Decrease through Chuna therapy with Scoliosis Patient. *J Orient Rehabil Med* 2004;14:143-147. [in Korean].
- [7] Yeom DS, Song YK, Lim HH. A Study of Exercise treatment based on Schroth method of Idiopathic Scoliosis. *J Korea Chuna Man Med Spine Nerves* 2010;5:181-191. [in Korean].
- [8] Han UJ, Lee MJ. Management Plan of Scoliosis in Oriental Medical Hospital. *J Orient Rehabil Med* 2001;11:143-154. [in Korean].
- [9] Kim DF, Keum DH. Effects of Mckenzie Method Treatment on Functional Lumbar Scoliosis by Herniated Lumbar Disc; Three Cases Report. *J Orient Rehabil Med* 2006;16:167-179. [in Korean].
- [10] Chang JH, Jung JE, Park HH, Kim SH, Kim MC. A Clinical Study of Patient with Lumbar Herniation of Intervertebral Disc Combined with Functional Scoliosis by Treating Ah-Shi Points of the Muscles that Induce Unilateral Pelvic Obliquity. *J Orient Rehabil Med* 2007;17:223-231. [in Korean].
- [11] Kim SU, Kang YH, Lee SH, Kwon HY, Cho TS, Song CH et al. Myofascial Release and Electroacupuncture Treatment in Functional Scoliosis. *J Dong-Eui Orient Med* 2001;5:59-66. [in Korean].
- [12] Ha IH, Park WS, Woo I, Kim HN, Kho DH, Yoon YS. Correlation between Horizontal Visual Analogue Scale, Vertical Visual Analogue Scale and Numerical Rating Scale for Pain Measurement. *J Orient Rehabil Med* 2006;16:125-133. [in Korean].
- [13] Kim HN, Kim HS, Moon ES, Yoon CS, Chung TS, Song HT et al. Scoliosis imaging: What radiologists should know. *Radiographics* 2010;30:1823-1842.
- [14] Cobb J. Outline for the study of scoliosis. *Instr Course Lect* 1948;5:261-275.
- [15] Hoppenfeld S, Lopez RA, Molnar G. Plantar weight-bearing Pattern in Idiopathic Scoliosis. *Spine* 1991;16:757-760.
- [16] Danaberg HJ, Guiliano M. Chronic low-back pain and its response to custom made foot orthosis. *J Am Podiatr Med Assoc* 1999;89:109-117.
- [17] Zabjek KF, Leroux MA, Coillard C, Martinez X, Griffet J, Simard G et al. Acute postural adaptations induced by a shoe lift in idiopathic scoliosis patients. *Eur Spine J* 2001;10:107-113.
- [18] Bang SP, Kim SP, Kim JW, Ryu HS, Chun HS, Ryu MS et al. A Case Study of Scoliosis with Sciatic Pain Patient Treated by Korean Medicine and Shoe Lift. *J Acupunct Res* 2010;27:135-143. [in Korean].
- [19] Ahn HB, Kim SJ, Jeong SH. The Application of Foot Orthotic to Chronic Pain Patient with Pelvic Obliquity: 4 Cases Report. *J Orient Rehabil Med* 2011;21:309-318. [in Korean].
- [20] Park TY, Moon TW, Cho DC, Lee JH, Ko YS, Hwang EH et al. An introduction to Chuna manual medicine in Korea: History, insurance coverage, education, and clinical research in Korean literature. *Integr Med Res* 2014;3:49-59.