



# Journal of Acupuncture Research

Journal homepage: <http://www.e-jar.org>

## Review Article

## A Facial Chuna Manual Therapy for Peripheral Facial Nerve Palsy

Yu-Kyeong Park<sup>1</sup>, Cho In Lee<sup>1</sup>, Jung Hee Lee<sup>1</sup>, Hyun-Jong Lee<sup>1</sup>, Yun-kyu Lee<sup>2</sup>, Jung-Chul Seo<sup>3</sup>, Jae Soo Kim<sup>1,\*</sup>

<sup>1</sup> Department of Acupuncture & Moxibustion, College of Korean Medicine, Daegu Haany University, Daegu, Korea

<sup>2</sup> Department of Acupuncture & Moxibustion, College of Korean Medicine, Daegu Haany University, Pohang, Korea

<sup>3</sup> Woori Kyunghee Korean Medical Clinic, Kumi, Korea



### ABSTRACT

#### Article history:

Submitted: October 14, 2019

Accepted: October 21, 2019

#### Keywords:

manual therapy, guideline,  
facial palsy

The purpose of this study was to investigate useful manual therapy techniques for peripheral facial nerve palsy and to propose guidelines to be applied for current manual therapy techniques. Several databases were searched to find manual therapies for facial palsy. These therapies included cervical, and temporomandibular joint chuna manual therapy, proprioceptive neuromuscular facilitation, neuromuscular re-education, facial exercise, and mime therapy. Both cervical, and temporomandibular joint chuna manual therapy release nerve compression, helping blood circulation and nerve conduction. Proprioceptive neuromuscular facilitation uses irradiation, bilateral activation, and eccentric facilitation to improve muscle power and symmetry. Neuromuscular re-education, as a retraining tool for facial movement patterns, enhances neuromuscular feedback. Facial exercise helps the patient continuously move and massage facial muscle themselves. Mime therapy aims to develop a conscious connection between the use of certain muscles and facial expressions. The use of facial chuna manual therapy for peripheral facial nerve palsy can stimulate the proprioceptive neuromuscular receptors in the face. Peripheral facial nerve palsy has 4 phases; progress phase, plateau phase, recovery phase, and sequelae phase. Each phase needs different treatments which include relaxation, assistance, resistance, origin-insertion extension, and nerve pathway expansion.

<https://doi.org/10.13045/jar.2019.00283>  
pISSN 2586-288X eISSN 2586-2898

©2019 Korean Acupuncture & Moxibustion Medicine Society. This is an open access article under the CC BY-NC-ND license (<http://creativecommons.org/licenses/by-nc-nd/4.0/>).

## Introduction

Seventh cranial nerve palsy, or peripheral facial nerve palsy (FNP) weakens facial muscles, altering facial symmetry and function [1]. The facial nerve passes through the internal auditory canal that lies in the temporal bone and exits between the inner ear and posterior cranial fossa [2]. The most prevalent causes of peripheral FNP are viral infections, trauma, surgery, diabetes, tumors, immunological disorders, or drug use [3]. These specific causes lead to swelling of the facial nerve trunk in the internal auditory canal and around the styloid process [2]. This leads to severe compression of nerve branches, and consequently, the ability of the nerve to initiate muscle movement will be impaired or lost [4]. As a result, patients may suffer from facial asymmetry, impaired expressions, drooling, difficulty eating, and incomplete eye closure [5]. There are many methods to recover facial nerve impairment using medicine, physical treatment, or surgery [6] and alternative treatments including acupuncture [7], moxibustion [8], taping [9], and others [6]. There is also a lesser known method for

recovering peripheral FNP which is facial chuna manual therapy (FCMT). Chuna manual therapy (CMT) is a manual therapy performed by Korean traditional medicine doctors. It is based on traditional Korean medicine theory, which encompasses concepts such as meridian theory and anatomy based on radiology. It is a technique that uses the practitioner's hand, and other parts of the body, or equipment to adjust the body's imbalance [10]. A variety of manual therapies are currently used to treat facial palsy in patients, including patients who have suffered a stroke. However, in applying treatment, the distinction between peripheral FNP and central paralysis is ambiguous, and in Chinese Chuna therapy, which has a meridian concept, it has been commonly used to massage facial muscles or press acupuncture points on the face [11]. The effects of adjustment to cervical spine and temporomandibular joint for peripheral FNP patients using CMT has been investigated, but there is no systematic facial chuna technique for facial muscles [12,13]. This review firstly examined useful manual therapies including CMT, proprioceptive neuromuscular facilitation (PNF) [14], neuromuscular re-education [14], mime therapy [15], and

\*Corresponding author.

Department of Acupuncture & Moxibustion, College of Korean Medicine, Daegu Haany University, Daegu, Korea

E-mail : [jaice@daum.net](mailto:jaice@daum.net)

ORCID: Yu-Kyeong Park <https://orcid.org/0000-0003-0087-953X>, Jae Soo Kim <https://orcid.org/0000-0003-4101-8058>

©2019 Korean Acupuncture & Moxibustion Medicine Society. This is an open access article under the CC BY-NC-ND license (<http://creativecommons.org/licenses/by-nc-nd/4.0/>).

facial exercise [15]. Secondly, with reference to this information, a facial CMT guideline was proposed according to the clinical phase of peripheral FNP [13,16].

## Materials and Methods

To investigate manual therapy techniques for peripheral FNP, articles in databases such as PubMed, Google Scholar, The Cochrane Library, The Research Information Sharing Service, The National Digital Science Library, and The China Knowledge Resource Integrated Database were searched. The search terms used were (“neuromuscular re-education” or “manual therapy” or “neuromuscular retraining” or “mime therapy” or “Kabat rehabilitation” or “proprioceptive neuromuscular facilitation” or “Abhishek Sharma” or “tuina/chuna” or “exercise”) and (“facial nerve palsy” or “facial palsy” or “Bell’s palsy”). Included in this review are randomized controlled trials, case studies, systematic reviews, literature reviews, articles, and information from YouTube, blogs, news articles, and books that reported the use of manual therapy for peripheral FNP. The studies and articles only included those which were written in English, Korean, or Chinese. Excluded from this review were studies and articles about facial palsy due to stroke, brain damage or bilateral facial palsy, and treatments that are not manual therapy. Studies with only abstracts available or whose original text was unavailable were also excluded.

## Results

Previously, in Chinese medicine, chuna/tuina therapy was traditionally used for peripheral FNP, by massaging the facial muscles or pressing acupoints on the face [11,17,18] (Fig. 1). Before starting chuna/tuina treatment, the entire face of the patient was steamed to relax the facial muscles, ligaments and tendons. The following acupoints were then pressed using the thumbs and other fingers [19]: (Shen Ting (DU-24), Tou Wei (ST-8), Yang Bai (GB-14), Si Zhu Kong (SJ-23), Zan Zhu (BL-2), Jing Ming (BL-1), Tong Zi Ziao (GB-1), Si Bai (ST-2), Ting gong (SI-19), Yi Feng (SJ-17), Jia Che (ST-6), Da Ying (ST-5), and Di Cang (ST-4).

CCMT uses cervical traction, suboccipital muscle fascia relaxation, and cervical subluxation correction. It has a positive effect on improving the blood flow in the vertebral arteries and stimulating the dura of the brain, and restore the facial nerves which are wrapped by extended dura meter [20-22].

Treatment of the temporomandibular joint with CMT has been shown to help improve mandibular range [12]. The mandibular range of motion in patients with facial palsy is an essential factor

because mandible movements enable changes in the intraoral spaces, allowing for free movements of the tongue and the soft tissue [23]. In addition, some articles denote that patients with facial palsy have a significant reduction in the mandibular range of motion when compared to the control group [12]. Therefore, treating the temporomandibular joint using an accurate balancing appliance and functional cerebrospinal therapy, releases nerve compression in the mandibular region, helping blood circulation and nerve conduction, resulting in improved peripheral FNP [12,16].

PNF is a modality of manual stimulation in peripheral FNP, inspired by the proprioceptive stimulation concept of H. Kabat [14,24]. Abhishek Sharma said that irradiation, bilateral activation, and eccentric facilitation can be used during exercise to achieve faster recovery in muscle power and symmetry in peripheral FNP patients [20]. The stimulation includes rhythmic initiation, repeated stretches and contractions, and a combination of isotonic movement and percussion of tendons or marginal fascia of the muscle [14]. This method considers that harmony, coordination, and optimal strength of body movements are performed following diagonal lines around the sagittal axis of the body, thus implying a ‘rotational’ effect [21]. PNF consists of facilitating a voluntary response of an impaired muscle through a global pattern of an entire muscular section which undergoes resistance [14].

Neuromuscular re-education is conducted using a mirror, camera, or surface electromyographic biofeedback as a retraining tool of facial movement patterns in physical therapy [22]. Although the facial muscles are skeletal muscles, they differ because of their limited ability to provide feedback. Intrinsic muscle sensory receptors, the primary feedback to the central nervous system, are few or absent in facial muscles [14]. Therefore, individuals are left with only a vague idea of their facial muscle action and inaction [25]. However, by using visual feedback via a mirror, camera, or electromyographic biofeedback, patients can learn movement patterns and control movement even if synkinesis is affecting their face [26].

Facial exercise can be used to strengthen the facial muscles [27]. For increasing the strength of the lips, tongue, eye muscles, and the range of motion of the mandibular joint, patients are instructed by their therapist to move by making facial expressions and massaging their face [28]. The patient can repeat the exercise in their home or anywhere at their leisure, so they can work continuously to recover from peripheral FNP and prevent sequelae [27].

Mime therapy is a combination of mime and physiotherapy which aim to promote symmetry of the face and to control synkinesis. It consists of self-massaging the face and neck, performing breathing and relaxation exercises, eye and lip closure exercises, letter and word exercises, expression exercises, and using specific exercises to coordinate both halves of the face and to decrease synkinesis. A mirror is used as a feedback instrument, as it is necessary to see how exercises are performed and whether synkinesis is present when treatment begins. The aim of these techniques is to develop a conscious connection between the use of certain muscles and facial expressions [15].

SJS non-resistance therapy is a new method developed by JS Shin (honorary president of The Koreans Society of Chuna Manual Medicine for Spine and Nerves), for recovering peripheral FNP using a neuromuscular re-education technique [29]. He observed that lightly assisting or using no resisting power on the weaker (paralyzed) side of a patient with peripheral FNP, stimulates the proprioceptive neuromuscular receptor in the face so that the brain does not recognize the sensory stimulation on the face. As a result, this therapy can help the facial nerve communicate with muscles correctly [29,30].

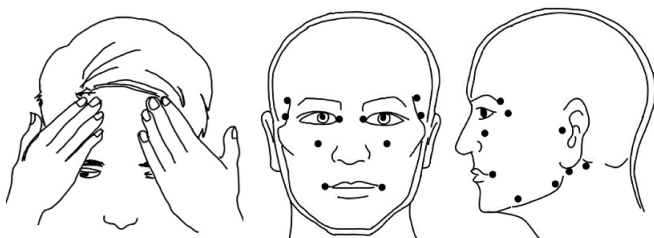


Fig. 1. Facial chuna/tuina treatment. The figure shows how to massage the face and stimulate several acupoints: Shen Ting (DU-24), Tou Wei (ST-8), Yang Bai (GB-14), Si Zhu Kong (SJ-23), Zan Zhu (BL-2), Jing Ming (BL-1), Tong Zi Ziao (GB-1), Si Bai (ST-2), Ting gong (SI-19), Yi Feng (SJ-17), Jia Che (ST-6), Da Ying (ST-5), Di Cang (ST-4). The black dot shows an acupoint which is used in facial nerve palsy treatment.

## Discussion

Generally, peripheral FNP changes follow 4 phases [3,6,31]. The first is the progress phase, which is from onset to complete progression. The second is the plateau phase, occurring after complete progression until initiation of recovery. When in this phase, the prognosis of recovering from peripheral FNP is predicted. This phase changes through 2 periods. First, the strength of muscles does not change from the previous phase, and then the muscles of the face start moving more actively than the previous phase. In recovery phase, the muscles of the face are stronger and strive to move at their maximum, even making expressions naturally. Unless the appropriate treatment is conducted during the first 3 phases, peripheral FNP will progress to sequela [32-35]. The physiological characteristics of peripheral FNP differ in each phase, so treatment should be applied differently at each phase.

Exercise, massage, and breathing techniques throughout the 4 phases are helpful in activating facial muscles and nerves by stimulating acupoints and meridians.

The patient can exercise to increase the strength of the lips, tongue, eye muscles, and range of motion of the mandibular joint [28], which maximizes the facial muscle movement. The patient needs to repeat the exercise method [36]; “Turn the corners of the mouth up,” “Push the upper lip forward,” “Suck in the cheeks and push the lips forward,” “Wrinkle the nose,” “Screw up the eyes tightly,” “Turn the corners of the mouth down and tighten the muscles on the front of the neck,” “Push the lower lip forward,” and “Raise the eyebrows.” The patient can use this exercise from the onset of their symptoms to complete recovery, but needs to be aware not to make large movements at the progress phase because quick gross movements induce mass movement of flaccid side muscles [3].

The practitioner gently massages the face according to the branch of the facial nerve to make the facial muscle more pliable and soft [36]. The meridian that flows in the face is also helpful in activating facial muscles and nerves [19,37] (Fig. 2). However, the practitioner needs to avoid unnecessary stimulation (such as friction) to prevent nerve degeneration and inflammation until the plateau phase [6].

The practitioner manipulates the patient's face following the breath of the patient. During inhalation, the practitioner assists or resists to the patient's facial movement. During exhalation, the practitioner holds the movement so as not to cause friction on the patient's face. Breathing helps the practitioner's manipulation by

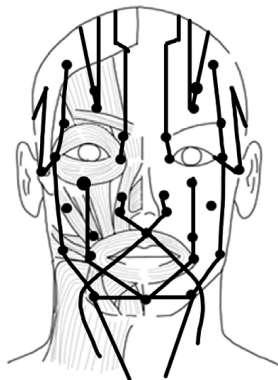


Fig. 2. The meridians. The figure shows the meridians that can affect the facial muscles and nerves.

releasing the facial muscle of the patient [38,39].

The progress phase lasts from the onset for 1-7 days [3], during which facial muscles become flaccid and asymmetry develops until complete progression [40]. The House-Brackmann grading system (HBGS) is below Grade 6 (Table 1) in this phase [41]. Relaxation and assist techniques for the face are necessary to prevent the progression of facial palsy and to stimulate the muscles and nerves (Fig. 3). To relax facial nerves and muscles, a practitioner gives acupressure on a facial acupoint using their fingers to apply slight pressure for several seconds. Stimulating acupoints of the face activates the muscles and improves the conduction of nerves, consequently delaying the progression of facial palsy [42]. Moreover, stimulating the meridian that flows in the face is also helpful in activating facial muscles and nerves [37,43]. The assist technique is where the practitioner actively assists the facial muscles in the direction in which the agonist muscle moves when the patient makes a facial expression, using the PNF method [14]. It helps the flaccid muscles of the weaker side to move in the manner of healthy muscles [14,30]. When patients move their facial muscles, they should avoid quick gross movement, because it induces passive mass movement of the flaccid side of the face.

The plateau phase spans from complete progression to about 2-3 weeks. This phase is divided into 2 parts: first, the muscle strength of the weaker side doesn't change (the HBGS is between Grade 5 and Grade 6; Table 1), then the strength begins to increase (the HBGS is under Grade 5) [40,41]. To improve the strength of muscles and conduction of nerves, assistance and resistance techniques are needed (Fig. 4). If the muscles of the weaker side can oppose the

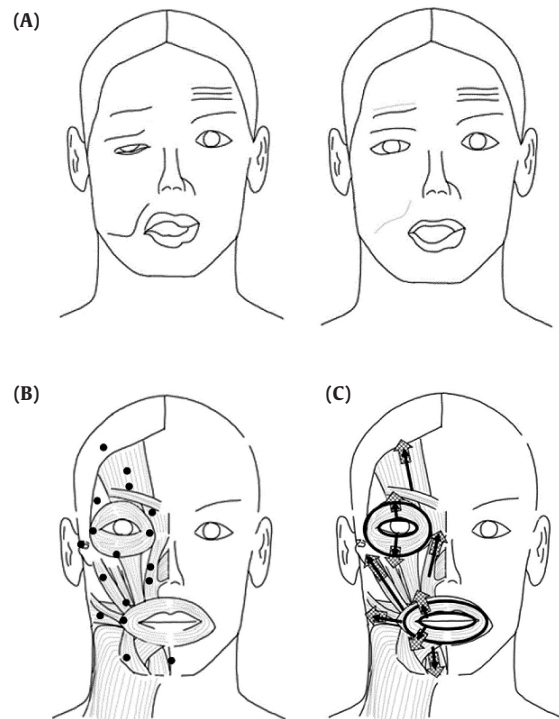


Fig. 3. FCMT in the progress phase. The image of FCMT in the progress phase is presented. The black dots indicate the facial acupoints for patient to relax. The black arrows indicate the directions of agonist muscle when the patient moves their face. The grid pattern arrows indicate assisting facial muscle origin region. (A) HBGS  $\leq$  6, (B) slight pressure with relaxation, (C) active assistance. FCMT, facial chuna manual therapy; HBGS, House-Brackmann grading system.

Table 1.The House-Brackmann Grading System.

Grade	Characteristic	Estimated function (%)
1	Normal function	100
2	Mild dysfunction	80
3	Reduced forehead movement, noticeable synkinesis and contracture	60
4	No forehead movement, incomplete eye closure, asymmetric mouth, disfigure in asymmetry	40
5	Minimal movement	20
6	No movement	0

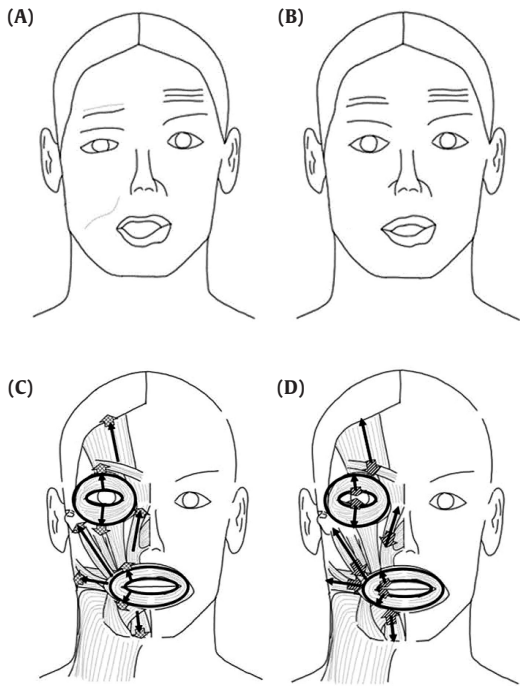


Fig. 4. FCMT in the plateau phase. The the image of FCMT in the plateau phase is presented. The black arrows indicate the directions of agonist muscle when the patient moves their face. The grid pattern arrows indicate assisting the origin region. The diagonal pattern arrows indicate resisting the insertion region. (A)  $5 \leq \text{HBGS} < 6$ , HBGS  $< 5$ , (C) facilitative assistance, (D) slight resistance. FCMT, facial chuna manual therapy; HBGS, House-Brackmann grading system.

power of the practitioner when pressure is applied, the practitioner needs to maintain an assist technique in the same manner of the previous phase but at weaker strength, in a more facilitative manner since the weaker side no longer needs to assist passively [14]. If the muscle tends to move, the practitioner needs to slightly oppose facial agonist muscles when making facial expressions, in a manner of increasing proprioceptive neuromuscular response [14,35].

During the recovery phase, the muscles become more active than in the previous 2 phases (the HBGS is under Grade 4) [40,41].

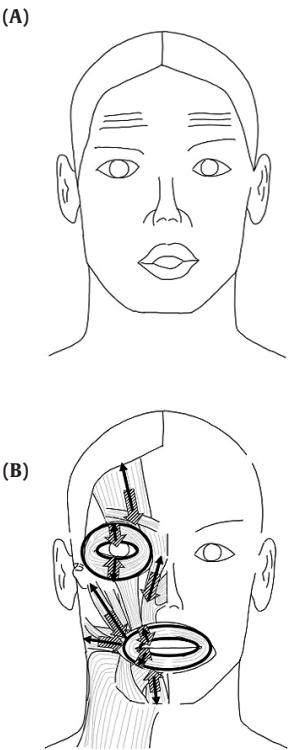


Fig. 5. FCMT in the recovery phase. The image of FCMT in the recovery phase is presented. The black arrows indicate the directions of agonist muscle when the patient moves their face. The diagonal pattern arrows indicate resisting the insertion region. (A) HBGS  $< 4$ , (B) active resistance. FCMT, facial chuna manual therapy; HBGS, House-Brackmann grading system.

To help muscles move more accurately and naturally, a practitioner uses an active resistance technique with more pressure as the weaker side muscles become stronger (Fig. 5). The practitioner opposes muscle movement, but with more resistance to induce the maximum muscular response [14]. The practitioner uses this technique until the weaker muscles reach complete recovery.

If facial nerve recovery is not complete, the muscles of the face maintain a state of decreasing strength, shortening length, and diminishing elasticity in the sequelae phase. In severe cases, this becomes complete paralysis. Furthermore, muscle-nerve adhesion, facial nerve entrapment, and loss of nerve excitability may occur [33]. As a result, the patient may complain of synkinesis, contracture, crocodile tears syndrome, spasm, tinnitus, and hearing loss [5].

Peripheral FNP provokes nerve degeneration. It induces regeneration of the zygomatic branches and buccal branches of the facial nerve, so unintentional face movement occurs when the patient intends to move the other side. The synkinesis usually occurs in the eyes and lip regions [33]. When the eye region moves, the lip, zygomatic, buccal, and platysma parts move unintentionally. Moreover, when the lip region moves, the superior, inferior, medial, lateral palpebral parts move unintentionally [44]. The patient should move facial muscles slowly to control unintentional muscle movement because quick motion can induce mass movement. The practitioner targets the facial site that synkinetic movement occurs by resisting unnecessary muscle contraction (Fig. 6) [14].



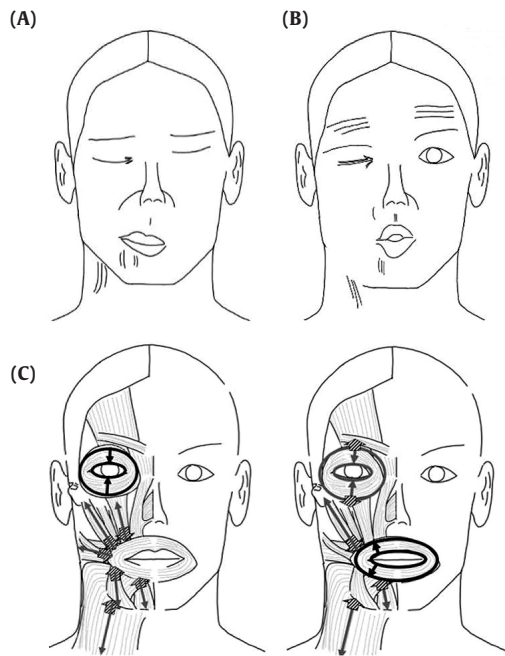


Fig. 6. FCMT for synkinesis in the sequelae phase. The image presents FCMT for synkinesis in the sequelae phase. The black arrows indicate the directions of agonist muscle when the patient moves their face. The gray arrows indicate the directions of the involuntary synkinetic movement of muscles. The diagonal pattern arrows indicate resisting the insertion region. Synkinesis (A) when eyes moving, (B) when lip moving, (C) Resistance (not to occur synkinetic movement). FCMT, facial chuna manual therapy.

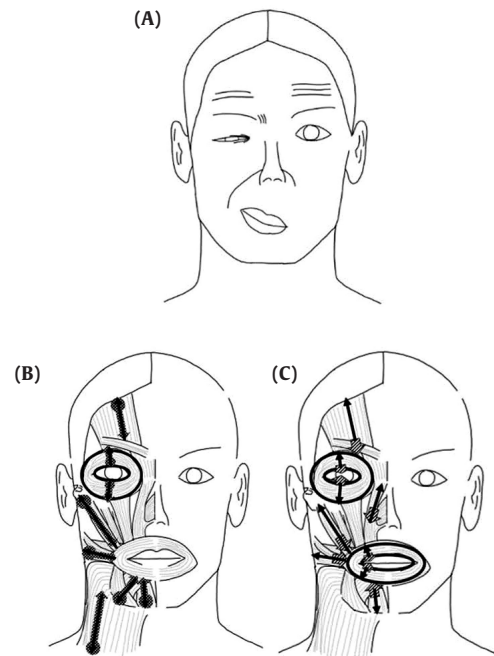


Fig. 7. FCMT for contracture in the sequelae phase. The image of FCMT for the contracture in the sequelae phase shows the black arrows that indicate the directions of agonist muscle when the patient moves their face. The dot pattern circles indicate the origin region of the facial muscle. The dot pattern arrows indicate that the practitioner draws to the direction of the insertion region to extend the length of the shrink muscle. The diagonal pattern arrows indicate resisting the insertion region. (A) Contracture, (B) origin-insertion extension, (C) resistance.

Incomplete recovery of the nerve induces the contracture of facial muscle groups [45]. It makes the patient feel stiffness and in severe cases, may cause the gap of the eyelids to narrow, corners of the mouth to rise, and abnormally deep facial wrinkles (especially nasolabial folds) to form [46]. The contracture can apply the origin-insertion extension and resistance technique. To extend muscle length, the practitioner presses the facial muscle origin region with 2 fingers then draws to the direction of the insertion region with 1 finger, holding the other on the origin region (Fig. 7). Also, the practitioner resists to the direction of muscle contraction of either facial muscle while resting or moving [14].

The crocodile tears syndrome, theoretically, after facial nerve injuries, branching axons of the regenerating salivary fibers of the facial nerve could ultimately reach both the salivary and the lacrimal glands and thus cause lacrimation during salivation [31,32]. The interaction of a fiber of the facial nerve, chorda tympani, and a larger superficial petrosal nerve, may cause lacrimation simultaneous with salivation. Therefore, the practitioner releases the fascia of the occipital head and adjusts subluxated upper cervical vertebra so that the facial nerve passes through the styloid process region more freely (Fig. 8) [13]. It stimulates the neuromuscular receptor of facial muscles by resisting cervical movement when facial muscles move in the same direction. Furthermore, during FCMT, the trigeminal sensory nerve fibers receive proprioceptive inputs from the facial muscles, communicating between CN, V, and the 7th cranial nerve [47].

When peripheral FNP progresses completely, the muscles and skin of the weaker side become flaccid and thick, because muscle strength continues to decrease, muscle length shrinks, and elasticity diminishes [5]. The practitioner gently massages

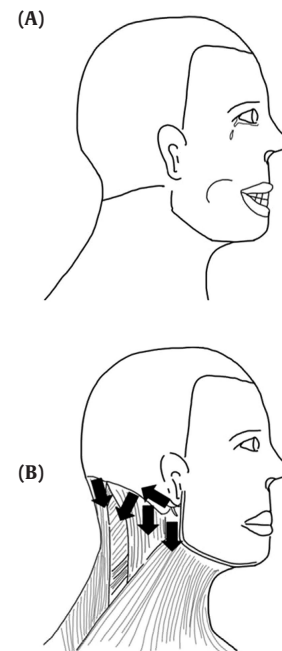


Fig. 8. FCMT for the crocodile tears syndrome in the sequelae phase. The image presents FCMT for the crocodile tears syndrome in the sequelae phase. The black arrows indicate the direction of releasing the fascia of the muscle. (A) Crocodile tears syndrome, (B) nerve pathway expansion. FCMT, facial chuna manual therapy.

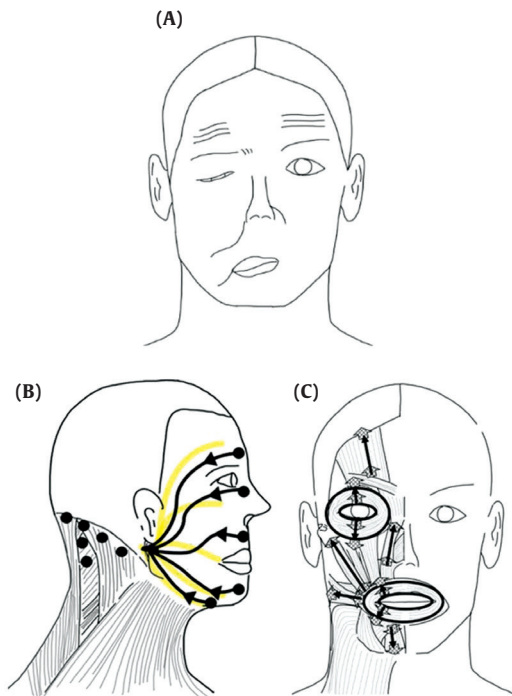


Fig. 9. FCMT for the complete paralysis in the sequelae phase. This is the image of FCMT for complete paralysis in the sequelae phase. In relaxation the black dots with black arrows indicate the direction of the massage. The yellow lines indicate the facial muscle branches. In assistance, the black arrows indicate the directions of agonist muscle when the patient moves their face. The grid pattern arrows indicate assisting both the origin region and insertion region. (A) Complete paralysis, (B) relaxation, (C) assistance.

FCMT, facial chuna manual therapy.

the face according to the branch of the facial nerve (temporal, zygomatic, buccal, marginal mandibular, and cervical) [4]. It will contribute that area of the face becoming more elastic and softer. This can also help to reduce muscle-nerve adhesion, facial nerve entrapment, and loss of nerve excitability (Fig. 9) [43]. In addition, the practitioner assists the flaccid side muscle by helping both the origin and insertion of muscle to move (Fig. 9).

## Conclusion

The aim of treating peripheral FNP by using FCMT is to stimulate the proprioceptive neuromuscular receptors in the face. Because the trigeminal sensory nerve fibers receive proprioceptive inputs from the facial muscles, they communicate between CN, V, and the 7th cranial nerve [47], inducing a nerve reaction and recovering muscle strength. Nevertheless, because there are insufficient intrinsic sensory nerves in the face, compared to other parts of the body, it is difficult for patients to offer feedback on how normal muscle spindles are acting while moving [14]. Therefore, a practitioner's clinical intervention is needed to provide effective neurofeedback for the patient's muscle movement by assisting the origin and resisting the insertion region of the facial muscles. This review presents the guideline for FCMT applied using current manual therapy techniques. Peripheral FNP has 4 phases: the progress phase, the plateau phase, the recovery phase, and the sequelae phase. Exercise, massage, and breath throughout the 4 phases are helpful in activating facial muscles and nerves by

stimulating acupoint and meridian. Moreover, the physiological characteristics of peripheral FNP differ in each phase, so treatment should be applied differently at each phase: relaxation, resisting, extending origin-insertion, and expanding nerve pathway techniques, respectively.

## Conflicts of Interest

The authors have no conflicts of interest to declare.

## References

- [1] Baricich A, Cabrio C, Paggio R, Cisari C, Aluffi P. Peripheral facial nerve palsy: How effective is rehabilitation? *Otol Neurotol* 2012;33:1118-1126.
- [2] Panara K, Hoffer M. Anatomy, Head and Neck, Ear Internal Auditory Canal (Internal Auditory Meatus, Internal Acoustic Canal) In: StatPearls. Treasure Island (FL): StatPearls Publishing LLC; 2019.
- [3] Garro A, Nigrovic LE. Managing peripheral facial palsy. *Ann Emerg Med* 2018;71:618-624.
- [4] Sunderland S, Cossar DF. The structure of the facial nerve. *Anat Rec* 1953;116:147-165.
- [5] Husseman J, Mehta RP. Management of synkinesis. *Facial Plast Surg* 2008;24:242-249.
- [6] Shafshak T. The treatment of facial palsy from the point of view of physical and rehabilitation medicine. *Eura Medicophys* 2006;42:41-47.
- [7] Chen N, Zhou M, He L, Zhou D, Li N. Acupuncture for bell's palsy. *Cochrane Database Syst Rev* 2010;8:1-24.
- [8] Li Y, Liang FR, Yu SG, Li CD, Hu LX, Zhou D et al. Efficacy of acupuncture and moxibustion in treating bell's palsy: A multicenter randomized controlled trial in china. *Chin Med J* 2004;117:1502-1506.
- [9] Svensson BH, Christiansen LS, Jepsen E. Treatment of central facial nerve paralysis with electromyography biofeedback and taping of cheek. A controlled clinical trial. *Ugeskr Laeger* 1992;154:3593-3596. [in Danish].
- [10] Lim KT, Hwang EH, Cho JH, Jung JY, Kim KW, Ha IH et al. Comparative effectiveness of chuna manual therapy versus conventional usual care for non-acute low back pain: A pilot randomized controlled trial. *Trials* 2019;20:216.
- [11] Lee SG, editor. Chinese Chuna Treatment. Byeon Y, translator. Seoul (Korea): Korea Textbook Co., Ltd.; 1994. p. 31-32. [in Korean].
- [12] Seo JC, Kim SY, Seo YJ, Park JH, Lee YJ, Yoo HM et al. The effect of korean medical treatments with postural yinyang correction of temporomandibular joint on bell's palsy. *J Acupunct Res* 2016;33:183-193. [in Korean].
- [13] Jeong JY, Lee ES, Seo DG, Shin SY, Kim SY, Kwon Hk et al. The clinical research of cervical treatment's effects on bell's palsy. *J Acupunct Res* 2014;31:45-55. [in Korean].
- [14] Sardaru D, Pendefunda L. Neuro-proprioceptive facilitation in the re-education of functional problems in facial paralysis. A practical approach. *Rev Med Chir Soc Med Nat Iasi* 2013;117:101-106.
- [15] Beurskens CH, Heymans PG. Mime therapy improves facial symmetry in people with long-term facial nerve paresis: A randomised controlled trial. *Aust J Physiother* 2006;52:177-183.
- [16] Park JH, Lee CH, Lee YH, Kwon GS, Youn HM, Jeun DS et al. The clinical research of the effectiveness of "danmuji anchu traction technique" on acute peripheral facial paralysis. *Korean Soc Chuna Man Med Spine Nerves* 2011;6:43-52. [in Korean].
- [17] Kong LJ, Fang M, Zhan HS, Yuan WA, Pu JH, Cheng YW et al. Tuina-focused integrative chinese medical therapies for inpatients with low back pain: A systematic review and meta-analysis. *Evid Based Complement Alternat Med* 2012;2012:578305.
- [18] Kwak MK, Kim MW, Jeong SJ, Kim SA, Jeong MY, Kim JH. Systematic review of chuna manipulative treatment for ankle sprain. *J Acupunct Res* 2018;35:61-68.
- [19] Wu X, Li Y, Zhu Y, Zheng H, Chen Q, Li X. Clinical practice guideline of acupuncture for bell's palsy. *World J Tradit Chin Med* 2015;1:53-62.
- [20] Mahesh SG, Nayak DR, Balakrishnan R, Pavithran P, Pillai S, Sharma A. Modified stennert's protocol in treating acute peripheral facial nerve paralysis: Our experience. *Indian J Otolaryngol Head Neck Surg* 2013;65:214-218.
- [21] Barbara M, Antonini G, Vestri A, Volpini L, Monini S. Role of kabat physical rehabilitation in bell's palsy: A randomized trial. *Acta Otolaryngol* 2010;130:167-172.

- [22] Choi JB. Effect of neuromuscular electrical stimulation on facial muscle strength and oral function in stroke patients with facial palsy. *J Phys Ther Sci* 2016;28:2541-2543.
- [23] Sassi FC, Mangilli LD, Poluca MC, Bento RF, Andrade CR. Mandibular range of motion in patients with idiopathic peripheral facial palsy. *Braz J Otorhinolaryngol* 2011;77:237-244.
- [24] Monini S, Iacolucci CM, Di Traglia M, Lazzarino AI, Barbara M. Role of kabat rehabilitation in facial nerve palsy: A randomised study on severe cases of bell's palsy. *Acta Otorhinolaryngol Ital* 2016;36:282-288.
- [25] Brach JS, VanSwearingen JM, Lenert J, Johnson PC. Facial neuromuscular retraining for oral synkinesis. *Plast Reconstr Surg* 1997;99:1922-1931.
- [26] Robinson MW, Baiungo J. Facial rehabilitation: Evaluation and treatment strategies for the patient with facial palsy. *Otolaryngol Clin North Am* 2018;51:1151-1167.
- [27] Cardoso JR, Teixeira EC, Moreira MD, Favero FM, Fontes SV, Bulle de Oliveira AS. Effects of exercises on bell's palsy: Systematic review of randomized controlled trials. *Otol Neurotol* 2008;29:557-560.
- [28] Cederwall E, Fagevik Olsén M, Hanner P, Fogdestam I. Evaluation of a physiotherapeutic treatment intervention in "Bell's" facial palsy. *Physiother Theory Pract* 2006;22:43-52.
- [29] Park JR [Internet]. SJS non-resistance therapy for peripheral facial palsy is very effective! Korea: akomnews; 09 Apr 2019 [1-1]. Available from: [http://www.akomnews.com/bbs/board.php?bo\\_table=news&wr\\_id=15536](http://www.akomnews.com/bbs/board.php?bo_table=news&wr_id=15536). [in Korean].
- [30] Calisgan E, Senol D, Cay M. Physiotherapy outweighed multiple therapy methods of bell's palsy: A review study. *J Turgut Ozal Med Cent* 2017;24:375-380.
- [31] Kim NK. The clinical observation of facial palsy sequela. *J Korean Orient Med* 2002;23:100-111. [in Korean].
- [32] Chorobski J. The syndrome of crocodile tears. *JAMA Psychiatry* 1951;65:299-318.
- [33] Crumley RL. Mechanisms of synkinesis. *Laryngoscope* 1979;89:1847-1854.
- [34] Husseman J, Mehta RP. Management of synkinesis. *Facial Plast Surg* 2008;24:242-249.
- [35] Terzis JK, Karypidis D. Therapeutic strategies in post-facial paralysis synkinesis in pediatric patients. *J Plast Reconstr Aesthet Surg* 2012;65:1009-1018.
- [36] Choi HJ, Shin SH. Effects of a facial muscle exercise program including facial massage for patients with facial palsy. *J Korean Acad Nurs* 2016;46:542-551. [in Korean].
- [37] Kwon NH, Kim CY, Shin YJ, Seo S, Song JH, Baek YH et al. Clinical study on facial skin furrow measurement change after miso facial rejuvenation acupuncture. *J Acupunct Res* 2009;26:133-140. [in Korean].
- [38] Sin MS, Kim YS, Lee MH. Effects of doin gigong exercise on recovery from facial paralysis, pain and anxiety of bell's palsy patients. *Clin Nurs Res* 2012;18:52-62. [in Korean].
- [39] Yoon KH, Lee SM, Lim JS, Cho YE, Lee HJ, Kim JH et al. Experience of bell's palsy patients on facial Qigong exercise and efficient educational program: A qualitative study. *J Acupunct Res* 2015;32:67-78. [in Korean].
- [40] van Landingham SW, Diels J, Lucarelli MJ. Physical therapy for facial nerve palsy: Applications for the physician. *Curr Opin Ophthalmol* 2018;29:469-475.
- [41] Sun MZ, Oh MC, Safae M, Kaur G, Parsa AT. Neuroanatomical correlation of the house-brackmann grading system in the microsurgical treatment of vestibular schwannoma. *Neurosurg Focus* 2012;33:E7.
- [42] Wang M, Loo WT, Chou JW. Electromyographic responses from the stimulation of the temporalis muscle through facial acupuncture points. *J Chiropr Med* 2007;6:146-152.
- [43] Jang JU, Kim KO, Yang JC, Mun KS, Lee KY. The clinical study on yangdorang change with idiopathic facial palsy patients. *J Acupunct Res* 2005;22:201-209. [in Korean].
- [44] Moran CJ, Neely JG. Patterns of facial nerve synkinesis. *Laryngoscope* 1996;106:1491-1496.
- [45] Spiller WG. Contracture occurring in partial recovery from paralysis of the facial nerve and other nerves. *JAMA Psychiatry* 1919;1:564-566.
- [46] V Euler US, Gaddum JH. Pseudomotor contractures after degeneration of the facial nerve. *J Physiol* 1931;73:54-66.
- [47] Cobo J, Solé-Magdalena A, Menéndez I, De Vicente J, Vega J. Connections between the facial and trigeminal nerves: Anatomical basis for facial muscle proprioception. *JPRAS Open* 2017;12:9-18.