

Case Report



Novel Non-Surgical Interventions for Benign Inflammatory Biliary Strictures in Infants: A Report of Two Cases and Review of Current Pediatric Literature

Pooja Reddy ¹, Yolanda Rivas,² Yosef Golowa,³ Deborah Kogan Liberman,² Sammy Ho,⁴ Dominique Jan,⁵ and Nadia Ovchinsky ²

¹Division of Pediatric Gastroenterology and Nutrition, Columbia University Medical Center, New York, NY, USA

²Division of Pediatric Gastroenterology and Nutrition, Children's Hospital at Montefiore, Bronx, NY, USA

³Department of Radiology, Montefiore Medical Center, Bronx, NY, USA

⁴Department of Medicine, Montefiore Medical Center, Bronx, NY, USA

⁵Division of Pediatric Surgery, Children's Hospital at Montefiore, Bronx, NY, USA

OPEN ACCESS

Received: May 21, 2019

Accepted: Aug 31, 2019

Correspondence to

Pooja Reddy

Division of Pediatric Gastroenterology and Nutrition, Columbia University Medical Center, 622 West 168th Street, PH 17, New York, NY 10032, USA.

E-mail: PR2577@Cumc.columbia.edu

Copyright © 2019 by The Korean Society of Pediatric Gastroenterology, Hepatology and Nutrition

This is an open-access article distributed under the terms of the Creative Commons Attribution Non-Commercial License (<https://creativecommons.org/licenses/by-nc/4.0/>) which permits unrestricted non-commercial use, distribution, and reproduction in any medium, provided the original work is properly cited.

ORCID iDs

Pooja Reddy 

<https://orcid.org/0000-0002-7002-0504>

Nadia Ovchinsky 

<https://orcid.org/0000-0002-1528-1680>

Conflict of Interest

The authors have no financial conflicts of interest related to this paper.

ABSTRACT

Benign biliary strictures are uncommon in children. Classically, these cases are managed surgically, however less invasive approaches with interventional radiology and or endoscopy may have similar results and improved safety profiles. While benign biliary strictures have been described in literature on several occasions in young children, (most older than 1 year and once in an infant 3 months of age), all reported cases were managed surgically. We present two cases of benign biliary strictures in infants less than 6 months of age that were managed successfully with novel non-invasive procedures and a review of all current pediatric cases reported in the literature. Furthermore, we describe the use of a Rendezvous procedure, which has not been reported as a treatment approach for benign biliary strictures.

Keywords: Benign biliary strictures; Inflammatory biliary strictures; Cholestasis: Neonatal; Cholestasis: Extrahepatic/surgery; Cholestasis: Extrahepatic/etiology; Neonatal Jaundice; Infant; Hepatobiliary; ERCP; Cholangiogram

INTRODUCTION

Benign idiopathic biliary strictures are exceedingly rare in infants [1,2]. Patients may present with similar signs and symptoms as other causes of hepatobiliary disease. Clinicians must maintain a high index of suspicion to avoid misdiagnosis. Historically, these cases were managed surgically [1,2], however less invasive treatments utilizing interventional radiology and endoscopic techniques are becoming more common, with similar outcomes and improved safety profiles [3]. Here, we present a report of two infants with benign inflammatory biliary strictures that were successfully managed with a minimally invasive approach and a review of all pediatric cases of idiopathic biliary strictures in current literature.

CASE REPORT

Case 1

A 3 month old girl, with resolved neonatal jaundice, presented with worsening acholic stools and jaundice over 1 week prompting further evaluation. Initial work-up revealed: total bilirubin (TBR) 6.7 mg/dL, direct bilirubin 4.3 mg/dL and gamma glutamyl transferase (GGT) 1,120 U/L. After a hepatobiliary iminodiacetic acid scan showed no excretion into the small bowel, an intraoperative cholangiogram was performed for concern of biliary atresia at outside hospital. Cholangiogram demonstrated dilation of the peripheral right and left hepatic bile ducts with a long segmental stricture of the common hepatic duct (CHD) and common bile duct (CBD). Magnetic resonance imaging (MRI) demonstrated dilated ducts as well, in addition to an ill-defined mass surrounding the strictured duct within the porta hepatis, suggestive of periportal fibrosis. The patient was subsequently transferred to our liver center for further care. Given the extension of the strictures to the portal confluence, we elected to treat this patient from a bi-lobar percutaneous approach. Initial percutaneous transhepatic cholangiogram (PTC) from the left biliary duct confirmed the long segment stricture involving the confluence of the right and left main hepatic ducts (**Fig. 1**). The stricture was crossed with a wire and an internal/external biliary drain was placed. This was followed by serial balloon dilations of the stricture at approximately 2 week intervals. This was done via the left side first, and subsequently via the right side. Biopsy of the surrounding mass revealed fibrosis and collagen deposition with inflammatory cells. Staining for CD-31 to suggest endothelioma and for CD1A and S-100 to suggest histiocytosis were negative. The drain was removed after a cholangiogram demonstrated a patent biliary system and appropriate intra-biliary ductal pressures during stress manometry (**Fig. 2**) [4]. Laboratory values, including TBR 0.2 mg/dL, and GGT 12 U/L normalized 3 months post-procedure and remained normal over 1 year later. US demonstrated complete resolution of the intrahepatic ductal dilation and of the hypoechoic mass in the porta hepatis.

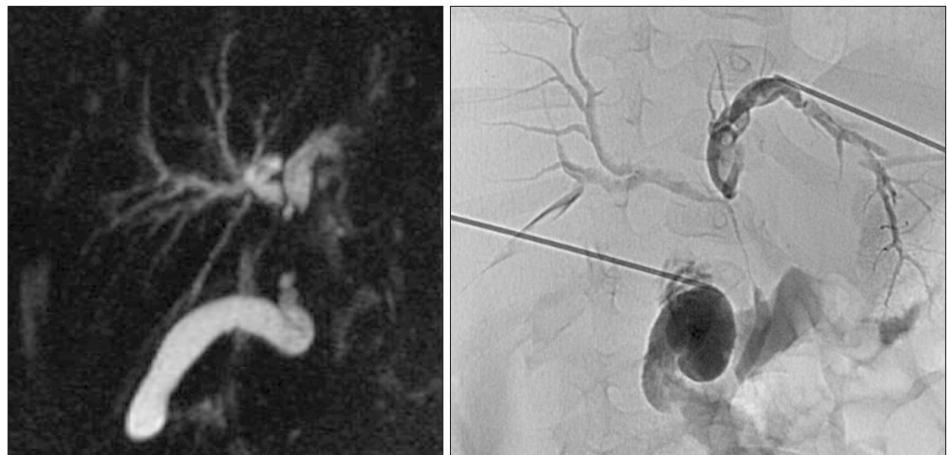


Fig. 1. Initial magnetic resonance cholangiopancreatography and cholangiogram demonstrating biliary stricture and dilatation of intrahepatic bile ducts.

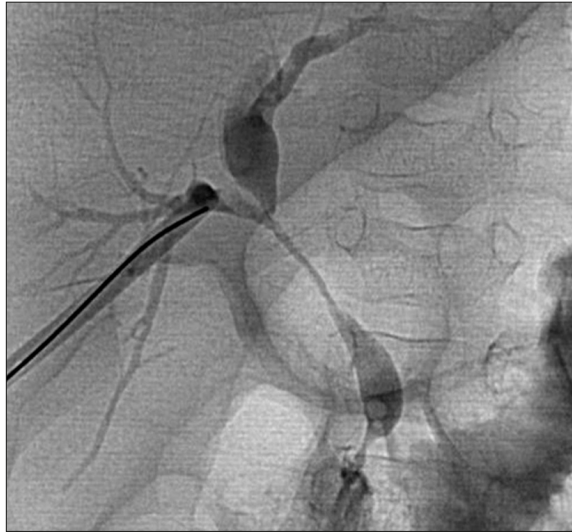


Fig. 2. Final cholangiogram demonstrating resolutions of both common hepatic duct and common bile duct stricture.

Case 2

A 5 month old boy with history of microcephaly and hypoxic ischemic encephalopathy presented with jaundice and acholic stools for several days. Initial work-up revealed: TB 12.4 mg/dL, DB 9.7 mg/dL, and GGT 732 U/L. Ultrasound and magnetic resonance cholangiopancreatography showed diffuse intrahepatic bile duct dilatation suggestive of biliary stricture. Endoscopic retrograde pancreatography (ERCP) was attempted, however cannulation of the CBD was unsuccessful. PTC demonstrated a severe stricture of the CHD. A catheter was left in place for external drainage to allow the decompression of the biliary system. Subsequently, a combined PTC and ERCP procedure was performed, which had been described as a 'Rendezvous technique.' The CBD was easily cannulated and a stent was placed via endoscopy with removal of biliary drain (**Fig. 3**). Patient's laboratory values normalized 6 weeks post-procedure. Resolution of ductal dilatation was confirmed on US.

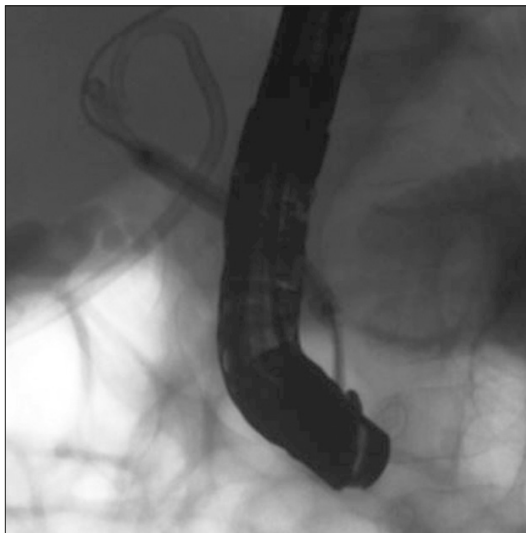


Fig. 3. Balloon dilatation of common bile duct with drainage catheter in place representing 'Rendezvous Procedure.'

DISCUSSION

Benign inflammatory biliary strictures should be considered in the differential diagnosis of an infant with cholestasis and elevated GGT. Although the stricture may not be visible on ultrasound, intrahepatic biliary dilatation may be seen and is suggestive of an obstructive process. Cross-sectional imaging, such as CT or MRI/MRCP may be helpful in identifying the strictured segment. Finally, a percutaneous or endoscopic cholangiogram can be both diagnostic and therapeutic.

Benign inflammatory biliary strictures have been described in the literature on several occasions in patients older than 1 year at time of presentation and in one infant 3 months of age (**Table 1**) [1,2,5,6].

In 1989, Standfield et al. [5] reviewed 12 cases of benign non-traumatic strictures between 1975 and 1986 in patients aged 1.5 to 60 years old. Four of these were pediatric patients aged 1.5 years old, 6 years old, 13 years old and 15 years old. All patients underwent laparotomy. Three of the four pediatric patients had excision with Roux-en-Y reconstruction. The fourth pediatric patient was initially treated with a T-tube, and subsequently a hepaticojejunostomy. Extrahepatic bile duct biopsies were reviewed from all 12 cases and included histologic features of chronic inflammation with lymphocytic and plasma cell infiltrates, ulceration, fibrosis and granulation tissue and changes in bile duct epithelium.

Bowles et al. [1] reports on 7 pediatric patients with benign strictures who underwent successful surgical intervention with biliary-enteric anastomosis. Five patients initially presented with obstructive jaundice, 1 with nonspecific gastrointestinal symptoms, and 1 with pruritus and bruising. Described patients were ages 2.5 years old to 15 years old. Five of these patients underwent resection of the stricture requiring hepaticojejunostomy. One 14 year old patient did have initial stent placement at the porta hepatis without resection, however, she required hepaticojejunostomy 2 years later. Again, denudation of biliary epithelium was observed in all but one lesion. Fibrosis and or signs of chronic inflammation were found in all biopsies and granulation tissue confirmed in 1 biopsy. Biopsy results were not available for review in one patient [1].

In a report of unusual cases of extrahepatic biliary obstruction, Krishna et al. [2] described 136 cases. Three of these were identified as idiopathic benign non-traumatic inflammatory strictures. The patients were ages 15 months, 3 years old and 13 years old. A Roux-en-Y hepaticojejunostomy was performed in all 3 of these cases, with excision of the stricture in the 3 year old and 13 year old. The 15 month old patient required hepaticojejunostomy alone. The 13 year old patient also had hepaticolithiasis at the time of presentation. Histopathology was consistent with prior descriptions of inflammatory biliary stricture with ulcerated biliary epithelium, fibrosis and signs of chronic inflammation [2].

During review of literature, one case of a benign inflammatory stricture in a patient less than 1 year at time of presentation was identified [6]. A 3 month old male presented with new onset diarrhea, progressively pale stools, weight loss and jaundice. Cholangiography confirmed a dilated CBD with sudden narrowing in the distal segment, but no signs of cysts or other extrinsic compression. This patient underwent duodenotomy with transpapillary dilatation of the stenotic segment. However, he later required cholecystectomy with T tube

Novel Non-Surgical Interventions for Benign Inflammatory Biliary Strictures in Infants

Table 1. Prior reported cases of benign biliary strictures

Case No.	Age/sex	Study	Location of lesion	Intervention	Comments	Histopathology of stricture
1	1.5 yr/M	Standfield et al. [5]		Excision, Roux-en-Y reconstruction		
2	6 yr/F	Standfield et al. [5]		Excision, Roux-en-Y reconstruction		
3	13 yr/F	Standfield et al. [5]		Excision, Roux-en-Y reconstruction		
4	15 yr/F	Standfield et al. [5]	Junction of RHD and LHD	T-tube, hepaticojejunostomy	Stricture unresectable, initial intervention T-tube placement and biopsy Partial resolution of mass at 2 yr, permitting hepaticojejunostomy with Roux-en-Y loop of jejunum	Hyperplastic biliary epithelium, granulation tissue with plasma cells and eosinophils
5	2.5 yr/M	Bowles et al. [1]	CHD and confluence	Resection, hepaticojejunostomy to confluence		
6	3.5 yr/F	Bowles et al. [1]	Upper CBD/ CHD/ confluence	Resection, hepaticojejunostomy to 2 ducts		Patchy epithelial loss, moderate fibrosis with sparse chronic inflammatory response
7	4 yr/F	Bowles et al. [1]	Mid-CBD	Resection, hepaticojejunostomy to CHD		Partial to extensive epithelial denudation, moderate fibrosis
8	4 yr/F	Bowles et al. [1]	CHD	No resection, hepaticojejunostomy to LHD	Stricture unresectable, initially good result but peri-portal fibrosis resulted in portal vein thrombosis with subsequent portal hypertension requiring splenorenal shunt 3.5 yr after biliary bypass	Patchy loss of biliary epithelium, fibrosis and chronic inflammation
9	7 yr/F	Bowles et al. [1]	CHD and confluence	Resection, hepaticojejunostomy to 2 ducts	History of leukemia s/p chemotherapy and cranial irradiation at 2.5 yr. Relapse requiring subsequent cranial-spinal irradiation	
10	14 yr/F	Bowles et al. [1]	Mass at porta hepatitis	Stenting, hepaticojejunostomy to LHD	Hepaticojejunostomy performed 2 yr after stent Required revision after 8 yr due to anastomotic stricture	Hyperplastic biliary epithelium with underlying granulation tissue and fibrosis
11	15 yr/F	Bowles et al. [1]	Lower CHD	Resection, hepaticojejunostomy to confluence		Loss of surface epithelium, dense fibrosis, chronic inflammatory cells
12	15 mo/M	Krishna et al. [2]	Mid-CBD	Roux-en-Y hepaticojejunostomy		
13	3 yr/M	Krishna et al. [2]	Mid-CBD	Resection, Roux-en-Y hepaticojejunostomy		Epithelial ulceration, chronic inflammation and mural fibrosis
14	13 yr/M	Krishna et al. [2]	Mid-CBD	Cholecystectomy, choledochoscopy, resection, stented Roux-en-Y hepaticojejunostomy	Hepaticolithiasis requiring percutaneous intervention 1 mo after hepaticojejunostomy	Epithelial ulceration, chronic inflammation and mural fibrosis
15	3 mo/M	Ammadeo et al. [6]	Distal CBD	Duodenotomy with transpapillary dilation of stricture Cholecystectomy and T-tube via remnant cystic duct	T-tube removed after 1 mo	

M: male, F: female, RHD: right hepatic duct, LHD: left hepatic duct, CBD: common bile duct, CHD: common hepatic duct.

placement via the cystic duct remnant to stent the dilated segment. The stent was removed after 1 month and the patient remained well at 9 month follow-up.

In summary, there are few reports cases of inflammatory biliary strictures in children, with only one reported case in an infant less than one year. Furthermore, all reported cases have been managed surgically. The advantages of less invasive intervention in non-traumatic strictures have been described extensively in the literature with respect to adult patients [3], however, there is a paucity of literature discussing non-surgical outcomes with this

disease entity in infants less than one year of age. We make this important age distinction to emphasize the benefits of the option of noninvasive procedures in this fragile age group.

A rendezvous technique describes access to an impervious location by way of two separate entry points. This approach for hepatobiliary dysfunction at the site of surgical anastomosis has been described with success in the pediatric transplant population and in infants with previous surgical intervention [7]. To our knowledge, it has not been described in patients with benign inflammatory strictures.

While we emphasize the benefits of the option of noninvasive procedures in this delicate age group, intervention in this cohort is not without its risks. Small ducts are difficult to cannulate and successful access requires procedural experience and expertise that many providers struggle to achieve with only a few number of cases at even large centers each year. The procedure itself requires specialized equipment including a side-view neonatal endoscope for ERCP that is expensive and not widely produced. Finally, biliary drainage tubes used by interventional radiology are not produced in diameters small enough to cannulate infant bile ducts requiring interventionalists to fashion their own tubes by cutting holes in catheters for 'off label' use. Still, in our experience the advantages of minimal post-procedural pain, infection risk, bleeding risk and ultimately hospitalization render the noninvasive treatment approach superior.

Benign inflammatory biliary strictures in infants may present similarly to other causes of obstructive cholestasis including biliary atresia and extrinsic compression. A high index of suspicion and early distinction may prevent unnecessary surgical procedures. Furthermore, we describe percutaneous access to the biliary tree with or without combined endoscopy, as a feasible approach for infants with benign inflammatory strictures. Less invasive percutaneous and endoscopic interventions may be utilized to treat these patients with excellent outcomes.

REFERENCES

1. Bowles MJ, Salisbury JR, Howard ER. Localized, benign, nontraumatic strictures of the extrahepatic biliary tree in children. *Surgery* 2001;130:55-9.
[PUBMED](#) | [CROSSREF](#)
2. Krishna RP, Lal R, Sikora SS, Yachha SK, Pal L. Unusual causes of extrahepatic biliary obstruction in children: a case series with review of literature. *Pediatr Surg Int* 2008;24:183-90.
[PUBMED](#) | [CROSSREF](#)
3. Davids PH, Tanka AK, Rauws EA, van Gulik TM, van Leeuwen DJ, de Wit LT, et al. Benign biliary strictures. Surgery or endoscopy? *Ann Surg* 1993;217:237-43.
[PUBMED](#) | [CROSSREF](#)
4. Haskal ZJ, Brown RS Jr. Role of biliary stress manometry after biliary stricture dilation in living donor liver transplant recipients. *J Vasc Interv Radiol* 2008;19(2 Pt 1):216-9.
[PUBMED](#) | [CROSSREF](#)
5. Standfield NJ, Salisbury JR, Howard ER. Benign non-traumatic inflammatory strictures of the extrahepatic biliary system. *Br J Surg* 1989;76:849-52.
[PUBMED](#) | [CROSSREF](#)
6. Amaddeo A, Rubinato E, Schleef J, Olenik D, Giglia D, Marchetti F, et al. Obstructive jaundice in a 3-month-old baby. *J Pediatr Gastroenterol Nutr* 2014;59:e31.
[PUBMED](#) | [CROSSREF](#)
7. Negm AA, Petersen C, Schneider A. Rendezvous procedure at 6 weeks of age. *Gastrointest Endosc* 2016;83:670-2; discussion 671-2.
[PUBMED](#) | [CROSSREF](#)