

## Adverse Effect of Nonylphenol on the Reproductive System in F2 Male Mice : A Qualitative Change?

Yong-Bin Kim<sup>1</sup>, Yong-Pil Cheon<sup>2</sup>, Donchan Choi<sup>3</sup>, and †Sung-Ho Lee<sup>1</sup>

<sup>1</sup>Dept. of Biotechnology, Sangmyung University, Seoul 03016, Korea

<sup>2</sup>Division of Developmental Biology and Physiology, Dept. of Lifetechnology, Sungshin University, Seoul 02844, Korea

<sup>3</sup>Dept. of Life Science, College of Environmental Sciences, Yong-In University, Yongin 17092, Korea

**ABSTRACT :** Previously, we reported negative effects of low-dose nonylphenol (NP) exposure on the reproductive organs of F1 male mice. In the present study was further investigated the endocrine disrupting effect of NP exposure to F2 generation male mice. Mice were divided into 2 groups; (1) CON, control animals and (2) NP-50 (50 µg/L), animals were treated with NP via drinking water. NP exposures were continuously conducted from parental pre-mating period until the postnatal day (PND) 55 of F2 offsprings. Mice were sacrificed on PND 55 and the reproductive tissue weights were measured. The initial (at PND 21) and terminal (PND 55) body weights of the NP-50 group animals were not significantly different from those of control group animals. NP exposure fail to induce a significant weight change of the testes, seminal vesicle and prostate except absolute epididymal weight ( $p < 0.05$ ). However, pathohistological studies revealed that NP-treated F2 animals showed evident decrease in seminiferous tubule diameters, reduced luminal area and number of germ cells. Also, sloughing morphologies in the tubules were notable. In the caudal epididymis, fewer mature sperms and swollen epithelial cells were found in the NP-treated group. The present study demonstrated that the subchronic low-dose NP exposure induced pathohistological abnormalities in testis and epididymis of F2 mice, and we assumed that these 'qualitative' changes in reproductive tissues could be derived from the epigenetic modifications such as DNA methylation, histone modification, altered DNA accessibility and chromatin structure. Further studies are needed to achieve a better understanding on the multi- or trans-generational effects of NP on the reproductive health and a human application.

**Key words :** Nonylphenol, F2 generation, Reproductive system, Pathohistology

### INTRODUCTION

Numerous studies have demonstrated that nonylphenol (NP) is an endocrine disrupting chemical (EDC) possessed negative effects on reproductive health (Noorimotlagh et al., 2017; Rattan et al., 2018). In rodents, administration of NP caused dysfunction of postpubertal reproductive function in female rats as well as disrupted development of gonads

in male and female rats (Nagao et al., 2000), decreased epididymal weights and sperm counts (Han et al., 2004), decreased weight/volume of testis and decreased number of germ cell and Sertoli cells (Mehranjani et al., 2009), impaired sperm motility and destruction of sperm function (Uguz et al., 2009), and destruction of blood-testis-barrier in testes (Lu et al., 2014). Previously, we reported that the subchronic low-dose NP exposure resulted in adverse effects

---

Manuscript received July 14, 2019, Received in revised form August 13, 2019, Accepted September 5, 2019

† Corresponding Author : Sung-Ho Lee, Ph.D., Dept. of Biotechnology, Sangmyung University, Seoul 03016, Korea. Tel : +82-2-2287-5139, Fax : +82-2-2287-0070, E-mail: shlee@smu.ac.kr



This is an Open Access article distributed under the terms of the Creative Commons Attribution Non-Commercial License (<http://creativecommons.org/licenses/by-nc/3.0>) which permits unrestricted non-commercial use, distribution, and reproduction in any medium, provided the original work is properly cited.

on the reproductive system of male and female F1 mice, such as decreased weight of ovary and uterus in F0 animals, decreased rate of ovulation in F1 offspring, increased weight of the testis, and decreased weights of the epididymis, prostate and seminal vesicle (Cha et al., 2017; Kim et al., 2019).

Some EDCs such as diethylstilbesterol (DES), vinclozolin, methoxychlor and phthalates has been intensively studied on their potent transgenerational effects (Newbold et al., 2000; Anway et al., 2006; Guerrero-Bosagna & Skinner MK, 2009; Stouder & Paoloni-Giacobino, 2011; Doyle et al., 2013). Only a handful of studies, however, have been carried out to investigate the multi-generational effects the NP on the reproductive system, and the results were controversial (Chapin et al., 1999; Kyselova et al., 2003; Tyl et al., 2006). We hypothesized that the uncertainty on the multi-generational NP effects could be derived from the difference of exposure dose between the studies. The dose employed in our previous studies (18.5–19.8 ug/kg/day) was far lower than the no-observed-adverse-effect level (NOAEL, 50 mg/kg/day in rat), while the doses about to or over the NOAEL have been used in most of studies on the endocrine disrupting nature of NP.

In the present study, we used the subchronic low-dose NP exposure model to clarify the multi-generational effect of NP on the reproductive system of F2 generation male mice.

## MATERIALS AND METHODS

### 1. Animals

ICR mice were provided by DBL (Chungcheongbuk-do, Korea) and reared in Sangmyung University animal facility under photoperiods of 12h light/dark with lights on at 7 AM and constant temperature of 21–23°C. Food and tap water were supplied *ad libitum*. The animal protocols were approved by the Animal Care and Use Committees at Sangmyung University (approval number R-1601-1). All the animals received human care in accordance with the

guides for animal experiments of the Association for Assessment and Accreditation of Laboratory Animal Care (AAALAC).

### 2. Treatments and tissue preparations

After acclimation, breeding pairs of mice were divided into 2 groups; (1) Control (CTL), supplied tap water, and (2) NP-50, treated with low-dose NP (50 µg/L; Sigma, USA) via drinking water. The parental (P) generation mice had pre-mating period for 2 weeks. After pre-mating period, male and female mice were placed in the breeding cage until a vaginal plug of female mice was observed. The animals were treated with NP from pre-mating period to weaning of offspring (F1). The F1 generation mice were weaned at postnatal day (PND) 21 and consistently treated with the NP, and when the male and female mice reached sexual maturity, the same breeding protocol which was applied to P generation mice was used. The offspring F2 generation mice were weaned at PND 21, and their anogenital distance (AGD) were measured with a digital caliper on PND 35, 40, 45, 50, and 55. Animals were sacrificed at PND 55, and sample collections were done between 18:00–19:00 pm. The weights of reproductive tissues (testis, epididymis, seminal vesicle and prostate) were measured. Tissues were fixed in paraformaldehyde (4%) for histological study.

### 3. Paraffin tissue section

Fixed tissues (testes and caudal edpidydimi) were dehydrated in graded concentrations of ethanol (70%, 80%, 90%, 95%, and 100%; Duksan, Korea) for 1 hour 30 minutes in each with gentle shaking and soaked in absolute ethanol overnight. The tissues were immersed in xylene (Samchun Chemical, Korea) for 30 minutes, 3 times and in paraffin (Avantik Biogroup, USA) at 56°C for 30 minutes, 3 times. The tissues were embedded in paraffin and sectioned (Microm, Germany) at 5 µm. The samples were attached on microscope slides (Marienfeld, Germany) and the slides

were stained with hematoxylin (Sigma, USA) and eosin (Across, USA) for 5 minutes, respectively.

#### 4. Statistical analysis

Values were expressed as mean±SE. Data were analyzed using Student's *t*-test as indicated.  $p < 0.05$  was considered statistically significant. Calculations were performed using Graphpad Software Prism version.

## RESULTS

### 1. Changes in body weights

To find the effect of chronic low-dose exposure to NP on the weight gain of F2 male mice, we measured and compared the body weights at weaning day (PND 21) and at sacrifice day (PND 55) (Table 1). The initial body weights of the NP-50 group animals were not significantly different from those of control group animals. Also the terminal body weights of the NP-50 group animals were not significantly different from those of control animals.

### 2. Changes in AGD index

Table 2 indicates that there was no statically significant difference in the AGD indices between control and NP-treated male mice from PND 35 to PND 55.

**Table 1. Effect of subchronic low-dose exposure to NP on the body weight gain from PND 21 to PND 55 in F2 male mice**

	CON	NP-50
Initial body weight (g)	10.8±0.4	11.2±0.5
Terminal body weight (g)	33.8±0.8	32.5±0.5
Increasing body weight (%)	315±14	292±16

Values are expressed as mean±SE (n=9).

\*  $p < 0.05$ , significantly different from the control group.

NP, nonylphenol; PND, postnatal day; CON, control group provided with tap water only; NP-50, treated with nonylphenol at a dose of 50 µg/L.

**Table 2. Effect of subchronic low-dose exposure to NP on changes in anogenital distance from PND 35 to PND 55 in F2 male mice**

	PND	CON	NP-50
	35	17.3±0.42	17.3±0.29
Anogenital distance (mm)	40	19.0±0.45	19.3±0.49
	45	19.9±0.41	19.8±0.47
	50	20.6±0.37	20.4±0.33
	55	21.3±0.38	21.2±0.42

Values are expressed as mean±SE (n=9).

NP, nonylphenol; PND, postnatal day; CON, control group provided with tap water only; NP-50, treated with nonylphenol at a dose of 50 µg/L.

### 3. Changes in reproductive tissue weights

As shown in Table 3, chronic low-dose NP exposure failed to induce any significant change in the absolute and relative weights of reproductive organs in F2 male mice, except the weights of the epididymis ( $p < 0.05$ ) when compared to control. However, the relative tissue weights were

**Table 3. Effect of subchronic low-dose exposure to NP on the absolute and relative weights of reproductive organs in F2 male mice**

	CON	NP-50
Testis (mg, pair)	128.0±7.53	124.0±4.13
Testis (mg, pair)/body weight (g)	3.8±0.28	3.8±0.09
Epididymis (mg)	42.0±1.66	46.1±1.29
Epididymis/body weight (g)	1.2±0.05	1.4±0.04*
Seminal vesicle (mg)	57.2±4.30	61.6±3.14
Seminal vesicle/body weight (g)	1.7±0.11	1.9±0.1
Prostate (mg)	7.7±0.64	6.3±0.48
Prostate (mg)/body weight (g)	0.2±0.02	0.2±0.02

Values are expressed as mean±SE (n=9).

\*  $p < 0.05$ , \*\*\*  $p < 0.001$ , significantly different from the control group value by *t*-test.

NP, nonylphenol; CON, control group provided with tap water only; NP-50, treated with nonylphenol at a dose of 50 µg/L.

not significantly different between two groups.

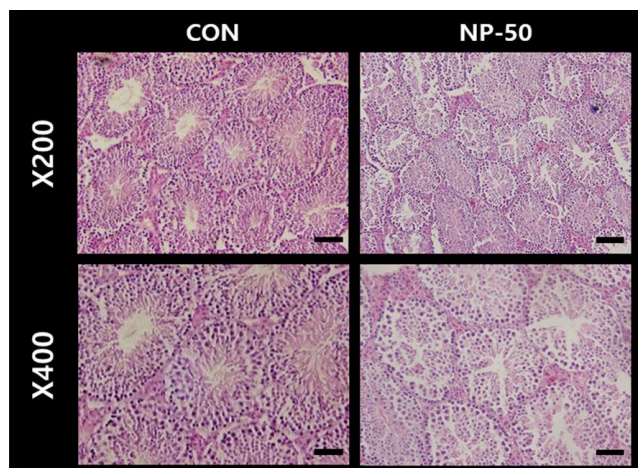
#### 4. Pathohistological changes in testis and epididymis

The overall histological appearances of the testis and caudal epididymis were similar to those of F1 mice organs (Kim et al., 2019). In the control testis, normal cellular architectures of seminiferous tubule were observed; tight Sertoli-Germ cell junctions were distinct and mature spermatids were abundant in the lumens (Fig. 1. CON). On the other hand, the volume of seminiferous tubule and its diameter, thickness of the basement membrane, luminal area and number of germ cell were decreased in the NP-treated testis (Fig. 1. NP-50). Sloughed and degenerate germ cells were much frequent in the NP-treated testis. Numerous mature sperms were found in the caudal epi-

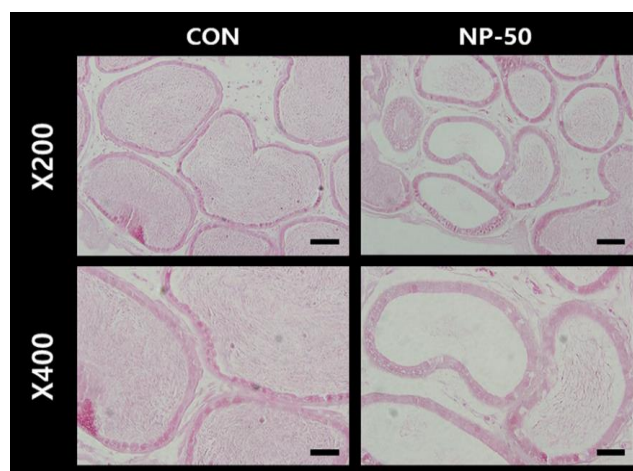
didymis of control animal (Fig. 2. CON). On the contrary, fewer mature sperms were found in the caudal epididymis of NP-treated animal (Fig. 2. NP-50). Notably, swollen epithelial cells were found in NP-50 group showing irregular cell arrangement.

## DISCUSSION

After the first report that NP has estrogenic effect in mammals (Soto et al., 1991), considerable evidence has accumulated indicating that NP could interfere with reproductive system (Nagao et al., 2001; Gong et al., 2009; Sato et al., 2009; Duan et al., 2016; Di et al., 2018). In particular, due to its estrogenic nature, relatively severe reproductive toxicity was found in NP-exposed male rodents. Para-nonylphenol (p-NP) exposure induced remarkable



**Fig. 1. Microphotographs of F2 testis.** The paraffin-embedded tissues were sectioned at 5  $\mu\text{m}$  and the sections were stained with hematoxylin and eosin. In the control group, the normal sizes of seminiferous tubules and lumen and normal arrangement of normal arrangement of germ cells were observed. In the NP-treated group, the diameters of seminiferous tubules and lumen were decreased. Note that sloughing morphologies of NP-treated group. NP, nonylphenol; CON, control group provided with tap water only; NP-50, treated with NP at a dose of 50  $\mu\text{g/L}$ . Scale bar ( $\times 200$ )=40  $\mu\text{m}$ ; ( $\times 400$ )=20  $\mu\text{m}$ .



**Fig. 2. Microphotographs of F2 caudal epididymis.** The paraffin-embedded tissues were sectioned at 5  $\mu\text{m}$  and the sections were stained with hematoxylin and eosin. Numerous mature sperms were found in the caudal epididymis of control animal (CON). On the contrary, fewer mature sperms were found in the caudal epididymis of NP-treated animal (NP-50). Note that swollen epithelial cells were found in NP-50 group. NP, nonylphenol; CON, control group given tap water only; NP-50, treated with NP at a dose of 50  $\mu\text{g/L}$ . Scale bar ( $\times 200$ )=40  $\mu\text{m}$ ; ( $\times 400$ )=20  $\mu\text{m}$ .

changes in testis architecture and significant reductions in number of germ cells and Sertoli cells in rat (Mehranjani et al., 2009). In vitro and in vivo studies indicated that NP could disrupt the structure and function of Sertoli cells, and decreased serum hormone levels in prepubertal male rats (Hu et al., 2014). Rat epididymal sperms exposed to NP exerted significantly worsening sperm parameters such as motility and acrosomal reaction (Uguz et al., 2009). Likewise, sperm counts in cauda and caput/corpus epididymides, sperm motility, daily sperm production and sperm transit time in cauda epididymis were remarkably decreased in rats gavaged with high-dose (100–300 mg/kg BW) NP for 30 days (Aly et al., 2012). Previously we demonstrated that the decreases of absolute weights in the accessory sex organs and the pathohistological changes in testis and epididymis of low-dose NP treated F1 mice, showing good agreement with the adverse effects of NP exposure on male rodents in the published reports (Kim et al., 2019). In the present study, we found that no change in numerical parameters such as tissue weight and AGD in NP exposed F2 mice, but still there were almost identical patterns of pathohistologic alteration in the testis and caudal epididymis as shown in F1 mice. For examples, multiple sloughing morphologies in seminiferous tubules, decreases in tubule diameter, reduced luminal area and number of germ cells were observed in the tissue sections from NP-treated F2 mice. With the apparent reduction in luminal sperm number from NP-treated epididymis, the present study strongly indicate the impaired spermatogenesis and detrimental effect on epididymal sperms in NP exposed F2 mice. These results support a low sperm count of NP-treated animals in the previous studies (Chitra et al., 2002; Uguz et al., 2009; Aly et al., 2012), and could be an explanation clue for a global decline in human sperm quality and count (Sifakis et al., 2017). Concerning the molecular action mechanism, NP-induced apoptosis, autophagy and necrosis in rat Sertoli cell seem to be through reactive oxygen species (ROS) mediated pathway (Duan et al., 2016).

Previous studies using boar and ram spermatozoa demonstrated that mitochondrial dysfunction could result in the formation of ROS (Uguz et al., 2015). In rat study, chronic oral administration of NP (250 mg/kg/day for 90 days) induced apoptosis and oxidative stress in epididymal sperm (Lu et al., 2014). Further studies on the NP action mechanism will be helpful to solve the problem with male infertility crisis.

There is general consensus among researchers that human EDC exposure is closely related to the lifestyle, and the lifestyle behaviors associated with EDCs exposures could be causes of low fertility and even serious diseases such as diabetes in adults, and could be passing through successive generations of family members (Martina et al., 2012; Lee, 2018). Several major EDCs has been studied on their potent transgenerational effects. DES exposure of the F1 generation mice during embryonic and early postnatal development at a range of dosages had adverse consequences in the F2 generations; in F2 males, the incidence of proliferative lesions of the testes was increased, and serum estradiol concentration was reduced (Newbold et al., 2000; Walker & Gore, 2011). Exposure to vinclozolin promotes transgenerational transmission of adult-onset disease states such as increased frequencies of tumors, prostate disease, kidney diseases, and immune abnormalities that develop as males age (Guerrero-Bosagna & Skinner, 2009). Particularly, the reduced spermatogenic capacity observed in the F1 male offspring was transmitted to the subsequent generations (F2–F4) (Anway et al., 2006). Methoxychlor treatment of pregnant mice decreased the mean sperm concentrations by 30% and altered the methylation pattern of all the imprinted genes tested in the F1 offspring, and the methoxychlor effects were transgenerational but disappeared gradually from F1 to F3 (Stouder & Paoloni-Giacobino, 2011). Embryonic exposure to Di-2-ethylhexyl phthalate (DEHP) was found to disrupt testicular germ cell organization and decreased sperm count and motility in F1 to F4 offspring in a transgenerational

manner, and spermatogonial stem cell (SSC) function of F3 offspring (Doyle et al., 2013).

Concerning the multi-generational effects the NP on the reproductive system, limited number of studies is available and the results were controversial. Sperm indices were unchanged in NP-exposed F0 and F1 males (30–100 or 100–350 mg/kg/day), but the testicular spermatid count and the epididymal sperm density were reduced while the testis and epididymis weights were unchanged in F2 rats (Chapin et al., 1999). A significant reduction in acrosomal integrity was seen in F1 and F2 generations of NP-treated CD-1 mice (50–500 µg/L in drinking water), and fewer offspring were observed in the second litter of the F2 generation of mice treated with NP (Kyselova et al., 2003). On the other hand, there was no NP (approximately > 150 mg/kg/day) effects on any reproductive parameter in any generation, including sperm counts of CD rats (Tyl et al., 2006). We hypothesized that the uncertainty on the multi-generational NP effects could be derived from the difference of exposure dose between the studies. The dose (18.5–19.8 µg/kg/day) employed in our previous (Kim et al., 2019) and the present studies was far lower than the NOAEL, while the doses about to or over the NOAEL have been used in most of studies on the endocrine disrupting nature of NP. Since the average daily human intake of NP was calculated to be 7.5 µg/day in Germany and to be about 25.32 µg/day in Taiwan (Guenther et al., 2002; Lu et al., 2007), the low dose used in our studies could be better to obtain practical information on the adverse effect of NP exposure to human. Unlike the deletion or substitution of nucleotide(s), the range of epigenetic modification such as DNA methylation, histone modification, altered DNA accessibility and chromatin structure induced by EDCs exposure might be variable (Xin et al., 2015). So one can assume that more of the inter-individual variability in abnormal status could be seen when there is a great difference of EDC exposure dose between studies.

In conclusion, though we found no numerically signifi-

cant change in the body and tissue weights in chronic low-dose NP exposed F2 male mice, our histological studies revealed that the abnormal structures of testicular seminiferous tubules and reduced number of germ cells in the tubules and epididymi of F2 mice, showing the coterminous states with those of F1 mice. This 'qualitative' change of reproductive tissues found in our study could be derived from the epigenetic reprogramming by low-dose NP exposure which is frequently experienced in daily living. Therefore, further studies with careful design of dose and exposure period are needed to achieve a better understanding on the multi- or trans-generational effects of NP on the reproductive health and a human application.

## CONFLICT OF INTERESTS

The authors declare no potential conflict of interest.

## ACKNOWLEDGMENT

This work was supported by the National Research Foundation of Korea (NRF) grant funded by the Korea government (2011-0025490).

## REFERENCES

- Aly HA, Domenech O, Banjar ZM (2012) Effect of nonylphenol on male reproduction: Analysis of rat epididymal biochemical markers and antioxidant defense enzymes. *Toxicol Appl Pharmacol* 261:134-141.
- Anway MD, Memon MA, Uzumcu M, Skinner MK (2006) Transgenerational effect of the endocrine disruptor vinclozolin on male spermatogenesis. *J Androl* 27:868-879.
- Cha S, Baek JW, Ji HJ, Choi JH, Kim C, Lee MY, Hwang YJ, Yang E, Lee SH, Jung HI, Cheon YP (2017) Disturbing effects of chronic low-dose 4-nonylphenol exposing on gonadal weight and reproductive outcome over one-generation. *Dev Reprod* 21:121-130.

- Chapin RE, Delaney J, Wang Y, Lanning L, Davis B, Collins B, Mintz N, Wolfe G (1999) The effects of 4-nonylphenol in rats: A multigeneration reproduction study. *Toxicol Sci* 52:80-91.
- Chitra KC, Latchoumycandane C, Mathur PP (2002) Effect of nonylphenol on the antioxidant system in epididymal sperm of rats. *Arch Toxicol* 76:545-551.
- Di QN, Cao WX, Xu R, Lu L, Xu Q, Wang XB (2018) Chronic low-dose exposure of nonylphenol alters energy homeostasis in the reproductive system of female rats. *Toxicol Appl Pharmacol* 348:67-75.
- Doyle TJ, Bowman JL, Windell VL, McLean DJ, Kim KH (2013) Transgenerational effects of di-(2-ethylhexyl) phthalate on testicular germ cell associations and spermatogonial stem cells in mice. *Biol Reprod* 88:112.
- Duan P, Hu C, Butler HJ, Quan C, Chen W, Huang W, Tang S, Zhou W, Yuan M, Shi Y, Martin FL, Yang K (2016) Effects of 4-nonylphenol on spermatogenesis and induction of testicular apoptosis through oxidative stress-related pathways. *Reprod Toxicol* 62:27-38.
- Gong Y, Wu J, Huang Y, Shen S, Han X (2009) Nonylphenol induces apoptosis in rat testicular Sertoli cells via endoplasmic reticulum stress. *Toxicol Lett* 186:84-95.
- Guenther K, Heinke V, Thiele B, Kleist E, Prast H, Raecker T (2002) Endocrine disrupting nonylphenols are ubiquitous in food. *Environ Sci Technol* 36:1676-1780.
- Guerrero-Bosagna CM, Skinner MK (2009) Epigenetic transgenerational effects of endocrine disruptors on male reproduction. *Semin Reprod Med* 27:403-408.
- Han XD, Tu ZG, Gong Y, Shen SN, Wang XY, Kang LN, Hou YY, Chen JX (2004) The toxic effects of nonylphenol on the reproductive system of male rats. *Reprod Toxicol* 19:215-221.
- Hu Y, Wang R, Xiang Z, Qian W, Han X, Li D (2014) Antagonistic effects of a mixture of low-dose nonylphenol and di-n-butyl phthalate (monobutyl phthalate) on the Sertoli cells and serum reproductive hormones in prepubertal male rats *in vitro* and *in vivo*. *PLOS ONE* 9:e93425.
- Kim YB, Cheon YP, Lee S-H (2019) Adverse effect of nonylphenol on the reproductive system in F1 male mice: A subchronic low-dose exposure model. *Dev Reprod* 23:93-99.
- Kyselova V, Peknicova J, Buckiova D, Boubelik M (2003) Effects of p-nonylphenol and resveratrol on body and organ weight and *in vivo* fertility of outbred CD-1 mice. *Reprod Biol Endocrinol* 1:30.
- Lee DH (2018) Evidence of the possible harm of endocrine-disrupting chemicals in humans: Ongoing debates and key issues. *Endocrinol Metab* 33:44-52.
- Lu YY, Chen ML, Sung FC, Wang PS, Mao IF (2007) Daily intake of 4-nonylphenol in Taiwanese. *Environ Int* 33:903-910.
- Lu WC, Wang AQ, Chen XL, Yang G, Lin Y, Chen YO, Hong CJ, Tian HL (2014) 90d exposure to nonylphenol has adverse effects on the spermatogenesis and sperm maturation of adult male rats. *Biomed Environ Sci* 27:907-911.
- Martina CA, Weiss B, Swan SH (2012) Lifestyle behaviors associated with exposures to endocrine disruptors. *Neurotoxicology* 33:1427-1433.
- Mehranjani MS, Noorafshan A, Momeni HR, Abnosi MH, Mahmoodi M, Anvari M, Hoseini SM (2009) Stereological study of the effects of vitamin E on testis structure in rats treated with para-nonylphenol. *Asian J Androl* 11:508-516.
- Nagao T, Saito Y, Usumi K, Nakagomi M, Yoshimura S, Ono H. (2000) Disruption of the reproductive system and reproductive performance by administration of nonylphenol to newborn rats. *Hum Exp Toxicol* 19:284-296.
- Nagao T, Wada K, Marumo H, Yoshimura S, Ono H (2001) Reproductive effects of nonylphenol in rats after gavage administration: A two-generation study. *Reprod*

- Toxicol 15:293-315.
- Newbold RR, Hanson RB, Jefferson WN, Bullock BC, Haseman J, McLachlan JA (2000) Proliferative lesions and reproductive tract tumors in male descendants of mice exposed developmentally to diethylstilbestrol. *Carcinogenesis* 21:1355-1363.
- Noorimotlagh Z, Haghighi NJ, Ahmadimoghadam M, Rahim F (2017) An updated systematic review on the possible effect of nonylphenol on male fertility. *Environ Sci Pollut Res Int* 24:3298-3314.
- Rattan S, Brehm E, Gao L, Niermann S, Flaws JA (2018) Prenatal exposure to di (2-ethylhexyl) phthalate disrupts ovarian function in a transgenerational manner in female mice. *Biol Reprod* 98:130-145.
- Sato T, Saito H, Uchiyama T, Fujimoto Y, Katase T, Kai O (2009) Effects of synthetic para-nonylphenol isomers administered chronically throughout pregnancy and lactation on reproductive system of mouse pups. *Arch Toxicol* 83:1097-1108.
- Sifakis S, Androutsopoulos VP, Tsatsakis AM, Spandidos DA (2017) Human exposure to endocrine disrupting chemicals: Effects on the male and female reproductive systems. *Environ Toxicol Pharmacol* 51:56-70.
- Soto AM, Justicia H, Wray JW, Sonnenschein C (1991) p-Nonyl-phenol: An estrogenic xenobiotic released from "modified" polystyrene. *Environ Health Perspect* 92:167-173.
- Stouder C, Paoloni-Giacobino A (2011) Specific trans-generational imprinting effects of the endocrine disruptor methoxychlor on male gametes. *Reproduction* 141:207-216.
- Tyl RW, Myers CB, Marr MC, Castillo NP, Seely JC, Sloan CS, Veselica MM, Joiner RL, Van Miller JP, Simon GS (2006) Three-generation evaluation of dietary para-nonylphenol in CD (Sprague-Dawley) rats. *Toxicol Sci* 92:295-310.
- Uguz C, Varisli O, Agca C, Agca Y (2009) Effects of nonylphenol on motility and subcellular elements of epididymal rat sperm. *Reprod Toxicol* 28:542-549.
- Uguz C, Varisli O, Agca C, Evans T, Agca Y (2015) In vitro effects of nonylphenol on motility, mitochondrial, acrosomal and chromatin integrity of ram and boar spermatozoa. *Andrologia* 47:910-919.
- Walker DM, Gore AC (2011) Transgenerational neuroendocrine disruption of reproduction. *Nat Rev Endocrinol* 7:197-207.
- Xin F, Susiarjo M, Bartolomei MS (2015) Multigenerational and transgenerational effects of endocrine disrupting chemicals: A role for altered epigenetic regulation? *Semin Cell Dev Biol* 43:66-75.