



# Monitoring BK virus infection in pediatric kidney transplant recipients

Min Hyun Cho, MD

Department of Pediatrics, Kyungpook National University Hospital, School of Medicine, Kyungpook National University, Daegu, Korea

Polyomavirus BK (BKV) is an important cause of allograft dysfunction and graft loss in kidney transplant recipients.<sup>1,2)</sup> The clinical manifestations of BKV infection, including BK viuria, BK viremia, and BKV nephropathy (BKVN), commonly develop during the first posttransplantation year.<sup>1)</sup> BK viremia is very common in children after kidney transplantation, especially in younger children and those receiving a kidney from a cadaveric donor.<sup>3)</sup> BKV infection can be diagnosed via the detection of decoy cells in urine cytology, confirming the presence of Haufen, which are icosahedral aggregates of polyomavirus particles by electron microscopy, and the detection of BKV DNA using urine and blood polymerase chain reaction (PCR) assays. Among them, measuring BKV DNA load in the blood using PCR is considered the preferred method of diagnosing BKV infection due its higher sensitivity and specificity as well as cost-effectiveness than other methods such as urine PCR and decoy cells.<sup>4)</sup> The diagnosis of BKVN is made by allograft biopsy, which shows tubulointerstitial mononuclear infiltration with many plasma cells, degenerative changes in the tubules, and intranuclear polyomavirus inclusion via SV40 immunoperoxidase stain.

Many studies reported that routine monitoring of BKV reactivation and adequate reduction of immunosuppression alone can effectively resolve viremia, preserve allograft function, and prevent symptomatic BKVN. Kwon et al.<sup>5)</sup> also reported that BKV infection developed in nine of 33 pediatric kidney transplant recipients (27.3%) and was effectively resolved by reduction of calcineurin inhibitor via routine monitoring of BKV load. Although there are several anti-BKV agents such as leflunomide, cidofovir, intravenous immunoglobulin, and fluoroquinolone, the benefit of these agents is limited.<sup>1)</sup> Therefore, the preemptive approach to resolving BKV viuria and/or viremia before the development of BKVN with reduction of immunosuppression is the mainstay of therapy in BK viremia/BKVN.<sup>6)</sup> The 2009 Kidney Disease: Improving Global Outcomes clinical practice guidelines recommend reducing immunosuppression when BKV plasma nucleic acid testing results are persistently greater than  $10^4$  copies/mL.

According to clinical algorithm based on current guidelines and available evidence (Fig. 1), screening for BK virus reactivation is recommended at least monthly for the first 3–6 months after kidney transplantation<sup>7)</sup> and then every 3 months until the end of the first posttransplantation year. This is also recommended in cases of an unexplained rise in serum creatinine or after the treatment of acute rejection. If a patient presents with elevated serum creatinine and significant viremia (BK viral load  $>10^4$  copies/mL on PCR), a graft biopsy should be performed to confirm definitive BKVN.<sup>1)</sup>

There is one thing to consider here. Allograft dysfunction combined with significant BK viremia does not always lead to BKVN. Because it is difficult to exclude the possibility of acute rejection or BKVN combined with acute rejection in such situations, an abrupt reduction in immunosuppression without confirmation of the pathologic findings of definitive BKVN can be counter-productive. Unfortunately, Kwon et al.<sup>5)</sup> reported that 6 of 9 patients with significant BK viremia presented azotemia, but none underwent renal biopsy, which limited their study. In conclusion, routine screening for BK virus reactivation and active use of graft

Corresponding author: Min Hyun Cho, MD

Department of Pediatrics, Kyungpook National University Hospital, School of Medicine, Kyungpook National University, 130 Dongdeok-ro, Jung-gu, Daegu 41944, Korea

Tel: +82-53-420-5719

Fax: +82-53-425-6683

E-mail: [chomh@knu.ac.kr](mailto:chomh@knu.ac.kr)

<https://orcid.org/0000-0002-7965-7587>

Received: 17 September, 2019

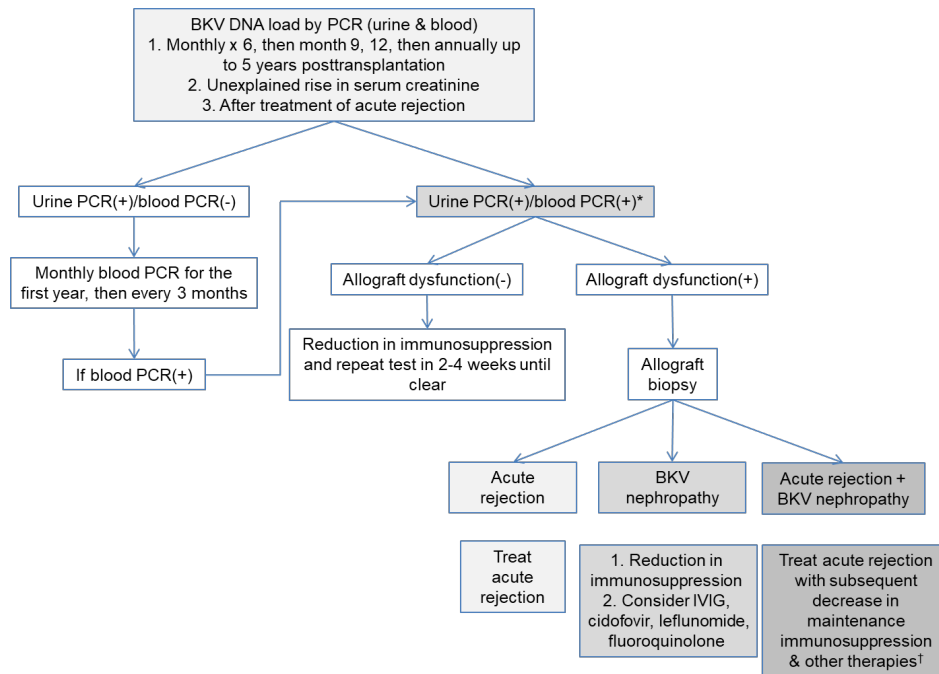
Revised: 7 October, 2019

Accepted: 18 October, 2019

See the article "Clinical manifestations of BK virus infection in pediatric kidney transplant patients" in Volume 62 on page 422.

Copyright © 2019 by The Korean Pediatric Society

This is an open-access article distributed under the terms of the Creative Commons Attribution Non-Commercial License (<http://creativecommons.org/licenses/by-nc/4.0/>) which permits unrestricted non-commercial use, distribution, and reproduction in any medium, provided the original work is properly cited.



**Fig. 1.** Clinical algorithm of management of BK virus infection in kidney transplant recipients. \*Blood PCR(+): significant viremia (BK viral load  $>10^4$  copies/mL). †Other therapies: IVIG, cidofovir, leflunomide, and fluoroquinolone, etc. BKV, BK virus; PCR, polymerase chain reaction; IVIG, intravenous immunoglobulin.

biopsy are the most reliable ways to overcome BK virus infection in pediatric kidney transplant recipients.

## Conflicts of interest

No potential conflict of interest relevant to this article was reported.

## References

- Lamarche C, Orio J, Collette S, Senécal L, Hébert MJ, Renoult É, et al. BK polyomavirus and the transplanted kidney: immunopathology and therapeutic approaches. *Transplantation* 2016;100:2276-87.
- Hymes LC, Warshaw BL. Polyomavirus (BK) in pediatric renal transplants: evaluation of viremic patients with and without BK associated nephritis. *Pediatr Transplant* 2006;10:920-2.
- Zarauza Santoveña A, García Meseguer C, Martínez Mejía S, Alonso Melgar Á, Fernández Cambor C, Melgosa Hijosa M, et al. BK virus infection in pediatric renal transplantation. *Transplant Proc* 2015; 47:62-6.
- Hirsch HH, Knowles W, Dickenmann M, Passweg J, Klimkait T, Mihatsch MJ, et al. Prospective study of polyomavirus type BK replication and nephropathy in renal-transplant recipients. *N Engl J Med* 2002;347:488-96.
- Kwon Y, Kim JY, Lee Y, Cho H. Clinical manifestations of BK virus infection in pediatric kidney transplant patients. *Korean J Pediatr* 2019;62:422-7.
- Ginevri F, Azzi A, Hirsch HH, Basso S, Fontana I, Cioni M, et al. Prospective monitoring of polyomavirus BK replication and impact of pre-emptive intervention in pediatric kidney recipients. *Am J Transplant* 2007;7:2727-35.
- Almérás C, Vetromile F, Garrigue V, Szwarc I, Foulongne V, Mourad G. Monthly screening for BK viremia is an effective strategy to prevent BK virus nephropathy in renal transplant recipients. *Transpl Infect Dis* 2011;13:101-8.