pISSN 1598-298X / eISSN 2384-0749
J Vet Clin 36(4) : 207-211 (2019)
http://dx.doi.org/10.17555/jvc.2019.08.36.4.207

Journal of Veterinary Clinics
www.ksvc.or.kr

Comparison of Radiographic and Echocardiographic Features between Small and Large dogs with Heartworm Disease

So-Young Kim, Hyun-Young Park, Jung-Yang Lee, Young-Won Lee and Ho-Jung Choi[1]

Department of Veterinary Medical Imaging, College of Veterinary Medicine, Chungnam National University, Daejeon 34134, Korea

(Received: June 13, 2019 / Accepted: August 09, 2019)

Abstract : This study was performed to compare the radiographic and echocardiographic features of cardiovascular changes between small and large dogs with heartworm diseases. Total of 49 dogs from two institutions were included in this study. The dogs were diagnosed with heartworm infestation and underwent thoracic and echocardiography. On thoracic radiographs, vertebral heart scale, reverse D shape, main pulmonary artery dilation, peripheral pulmonary artery dilation, and evidence of right heart failure were evaluated. On echocardiographs, visibility of worms, main pulmonary artery to aortic root (MPA/Ao) ratio, right to left ventricular basal diameter (RVD/LVD) ratio, and pulmonary hypertension were evaluated and analyzed between small and large dogs. The proportion of reverse D shape of the heart and accuracy for right ventricular hypertrophy in small dogs were lower than those of the large dogs. For echocardiographic parameter, the MPA/Ao and RVD/LVD ratio in the small dogs were significantly lower than those of the large dogs. As the results, thoracic radiography have a tendency to underestimate the severity of HWD in small dogs and should be used with echocardiography.

Key words **:** dogs, echocardiography, heartworm, pulmonary hypertension, radiography.

Introduction

The severity of canine heartworm disease (HWD) is classified into four grades depending on the degree of clinical signs, imaging features, and clinicopathologic abnormalities (10). Thoracic radiography has been used to grade the severity of HWD by evaluating cardiovascular and lung parenchymal changes including right ventricular hypertrophy, dilation of the main pulmonary artery (MPA), engorgement and/or tortuosity of pulmonary arteries and focal or multifocal alveolar pulmonary infiltration (2,9,13). Pleural and peritoneal effusion, the evidence of right heart failure, are also detected on thoracic and abdominal radiographs (16,17).

Echocardiography provides valuable information on the progression of HWD as a gold standard in the assessment of cardiac chamber size, cardiac function and pulmonary hypertension (3,5). Adult worms can be identified on the right side of the heart or pulmonary artery (2,3).

Most previous studies of radiographic and echocardiographic findings in HWD has been associated with large breed dogs, and less has focused on small breed dogs. Based on the author's observations, cardiovascular changes on the thoracic radiography often do not seem to reflect the severity of HWD in small breed dogs compared to large breed dogs. This study was performed to compare radiographic and echocardiographic changes of small breed dogs with those of large dogs and compare cardiovascular changes between radiography and echocardiography in dogs with HWD.

[1]Corresponding author.
E-mail : hjchoi@cnu.ac.kr

Materials and Methods

Experimental animals

Clinical and imaging data were searched from medical records at three different institutions (Chungnam national university animal hospital, Easy animal medical center and Haeundae animal medical center) from January 1, 2012 to September 31, 2018. These dogs were diagnosed with HWD based on the positive results with Canine SNAP 4Dx Plus Test and/or detection of adult worms on echocardiography. Thoracic radiographic and echocardiographic information were available for assessment of cardiovascular changes in all dogs.

The dogs with HWD were divided into two groups -small dogs (SD) group weighing less than 10 kg and large dogs (LD) group over 10 kg. Clinical signs were recorded in all dogs; cough, tachypnea, dyspnea, and exercise intolerance. General or urological signs were also recorded for weight loss, anorexia, lethargy, syncope, abdominal distension, and hematuria. Each clinical sign was evaluated for existence and recorded (yes or no).

Imaging analyses

Radiographic examinations were performed with three different digital radiographic equipments (XPLRER-900, Medien international Co. Ltd., Korea in Chungnam national university animal hospital, VETTER DX-16, Medien internation Co., Ltd., Korea in Easy animal medical center, and Comed Medical Systems Co., Ltd., Korea in Haeundae animal medical center). Examination protocols varied depending on the thoracic thickness of the dogs and settings of each radio-

graphic equipment. Right lateral and ventrodorsal thoracic radiographs were available for evaluation. Imaging analysis was done with Picture Archiving and Communication System (PACS, ViewRex, TechHeim Co., Ltd., Seoul, Korea) after sending all images to the workstation.

The factors for the cardiovascular changes on the thoracic radiography were vertebral heart scale (VHS), reverse D shape of the heart, dilation of peripheral pulmonary arteries, and the evidence of right heart failure (RHF). Measurement of VHS was calculated for quantifying heart size on the thoracic radiographs as previously described (6). The normal reference range for VHS was considered as 8.7-10.7 v. Reverse D shape of the cardiac silhouette was evaluated from the ventrodorsal views with clock face analogy. Right ventricular (RV) enlargement and dilation of main pulmonary artery (MPA) were evaluated as bulging of the cardiac silhouette at 5 to 9 and 1 to 2 o'clock position, respectively. Three observers evaluated the reverse D shape and recorded it as yes or no. Only when both factors were satisfied, reverse D shape was admitted.

Peripheral pulmonary arteries were assessed in the right lateral and ventrodorsal views for cranial and caudal lobar arteries, respectively. The cranial lobar arteries were compared to the width of veins and the narrowest width of proximal third of the 4th rib. The caudal lobar arteries were also compared to the width of veins and 9th rib where they crossed each other. Normally, peripheral pulmonary arteries should be approximately the same size with their veins and ribs. Dilation of crainal and caudal lobar ateries (subjective assessment; yes or no) was recorded. RHF was evaluated as the presence of either pleural fluid or ascites.

The dog underwent echocardiographic examinations with 5 to 7.5 MHz phased-array transducers (iU22, Philips Medical system, Bothwell, USA in Chungnam national university animal hospital, Prosound α6, Hitachi-Aloka Medical, Tokyo, Japan, Prosound α7, Hitachi-Aloka Medical, Tokyo, Japan). All echocardiographic measurements were obtained without sedation or anesthesia. Echocardiographic scans were performed on right parasternal long axis four-chamber view, right parasternal short axis view of the heart base and left parasternal apical four-chamber view. Following factors were evaluated using PACS system after sending raw data to the work station; visibility of adult worms, main pulmonary artery/aortic root (MPA/Ao) ratio, end-diastolic right to left ventricular basal diameter (RVD/LVD) ratio, and pulmonary hypertension. MPA/Ao ratio was obtained to assess the degree of MPA dilation from right parasternal short axis view at the level of aortic valve and pulmonic valve level. The MPA diameter was measured under the pulmonic valve immediately after the valve close, the aortic diameter was measured on the same view at the end-diastole using electronic calipers (Fig 1). The normal range of MPA/Ao ratio was reported as 0.8-1.15 (14). Measurements of RVD/LVD ratio was calculated to assess the degree of RV enlargement from the left parasternal apical four-chamber view as previously described (7,8,12,15). The basal diameters of right and left ventricle were measured from inner to inner margin of each ventricular wall at end-diastole using electronic calipers (Fig 1). The RVD/LVD ratio was obtained by dividing the RVD into the LVD. The normal reference range for RVD/LVD ratio was considered to be lower than 0.67 (1).

For evaluation of pulmonary hypertension, TR velocities were recorded from the let parasternal apical four-chamber view by placing the continuous wave Doppler gate at the right atrium. The peak jet velocities (V) were converted to estimate right ventricular systolic pressure (RVSP) and systolic pulmonary artery pressure (SPAP) by the modified Bernoulli equation (12).

$$RVSP = 4V^2 + RA\ pressure$$

RA pressure in normal, intermediate, and presence of right heart failure was assigning a fixed value of 5, 10, and 15 mmHg, respectively. If there was no evidence of the RV outflow tract obstruction, SPAP will be equal to RVSP. The pulmonary hypertension were graded as mild (30 to 55 mmHG), moderate (56 to 70 mmHg) and severe (over 80 mmHg) (15).

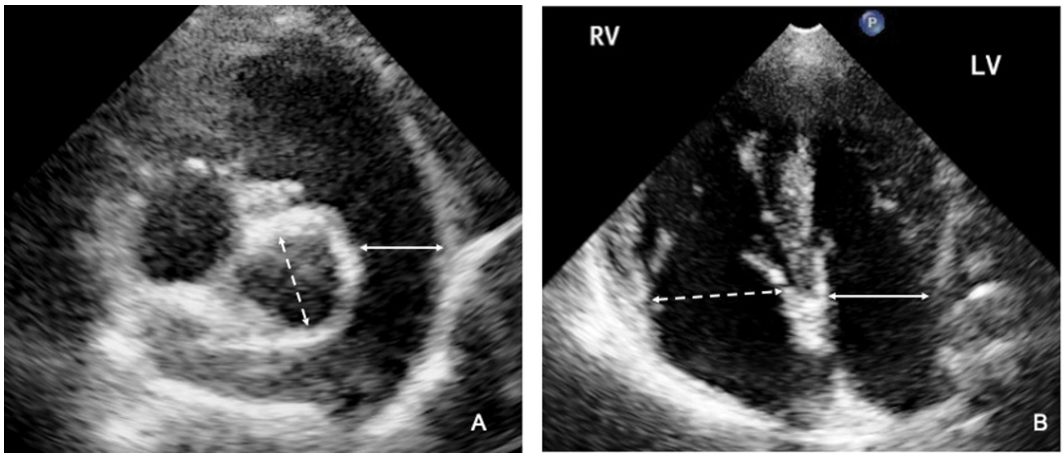

Fig 1. (A) Main pulmonary artery and aortic root diameter were measured on right parasternal short axis view at the aortic and pulmonic valve level. The main pulmonary artery diameter (double arrow) was measured under the pulmonic valve immediately after the valve close, the aortic root diameter (dashed double arrow) was measured on the same view. (B) Right ventricular and left ventricular basal diameter were measured on left parasternal apical four-chamber view. The basal diameter of right (dashed double arrow) and left ventricle (double arrow) were measured from inner to inner margin of each ventricular wall at end-diastole.

Statistics

Descriptive statistics including mean and standard deviations (SD) were calculated for the VHS, MPA/Ao ratio and RVD/LVD ratio. These factors were compared between small and large dog groups and with normal reference range using one-sample t-test. Other measurements were analyzed using independent t-test or Mann-Whitney test. RV hypertrophy, dilation of MPA, reverse D shape, dilation of peripheral pulmonary arteries, RHF, visibility of worms, PH and clinical signs were compared between groups and other factors using Pearson's chi-square test. A probability value ($p < 0.05$) was considered statistically significant. Inter-observer agreement of RV hypertrophy, dilation of MPA, reverse D shape was assessed to secure objectivity using Intraclass Correlation Coefficient (ICC). An ICC < 0.40 is considered as poor, 0.41-0.59 as fair, 0.60-0.74 as good and 0.75-1.00 as excellent agreement. Statistics was performed with the SPSS statistical software program (IBM SPSS Statistics 24.0, IBM Corp., USA).

Results

A total of 49 dogs were included in this study. SD group include 31 dogs and 18 dogs were in LD group. The clinical information for the dogs are summarized in Table 1.

The results of cardiovascular changes using radiography and echocardiography in 49 dogs with HWD are described in Table 2. VHS of SD group was higher than that of LD group, however these did not reach statistical significance. The percentage of dogs with dilation of MPA ($p = 0.041$) and reverse D shape ($p = 0.001$) in the SD group was significantly lower than that of LD group. There were no significant differences in the percentage of dogs with RV hypertrophy and RHF between SD and LD groups. MPA/Ao ratio of the SD group was significantly lower than that of LD group ($p = 0.011$). RVD/LVD ratio of LD group was significantly higher than that of SD group ($p = 0.028$). In addition, the RVD/LVD ratio of both groups was significantly higher than the normal reference range ($p = 0.001$). There were no significant differences in the visibility of worms and the presence of PH between SD and LD groups.

Of 49 dogs in both groups, the number of dogs with visible worms on echocardiography were 23 and their VHS was 10.7 ± 0.15. Pulmonary hypertension was detected in 30 dogs and their VHS was 10.8 ± 0.15. RVD/LVD ratio was increased in 31 dogs and their VHS was 10.7 ± 0.13. VHS of these dogs was upper limit of normal reference range.

The agreement of RV hypertrophy, MPA bulging and reverse D shape was estimated in radiography by three observers. The results were analyzed by intraclass correlation coefficient (ICC). The ICC for three values were 0.85, 0.87, and 0.86, respectively. The consistency of the three values was high indicating an acceptable level of interobserver agreement.

In the SD group, 6 dogs represented reverse D shape of the

Table 1. Clinical information in the dogs with HWD

	SD group	LD group
Number	31	18
Age (years)	6.9 ± 2.9	6.2 ± 3.7
Body weight (kg)	5.3 ± 2.0	19.0 ± 6.3
Sex	F (13), MC (9), M (6), FS (3)	M (10), F (5), FS (2), MC (1)
Breed	Mongrel (11), Yorkshire Terrier (5), Maltese (4), Miniature Poodle (3), Cocker Spaniel (2), Chihuahua (1), Lhasa Apso (1), Pomeranian (1), Pug (1), Schnauzer (1), Spitz (1)	Jindo Dog (6), Mongrel (4), Cocker Spaniel (2), Golden Retriever (2), Beagle (1), Labrador Retriever (1), Pungsan Dog (1), Samoyed (1)

SD, small dogs; LD, large dogs; F, female; FS, spayed female; M, male; MC, castrated male.

Table 2. Results of cardiovascular changes using radiography and echocardiography in 49 dogs with heartworm diseases

	Variables	SD group (n = 31)	LD group (n = 18)	p-Value
Radiography	VHS (Mean ± SD)	10.58 ± 0.82	10.34 ± 0.96	0.363
	RV hypertrophy (N, %)	16 (51.6)	13 (72.2)	0.157
	dilation of MPA (N, %)	13 (41.9)[a)]	13 (72.2)	0.041
	Reverse D shape (N, %)	6 (19.4)[a)]	12 (66.7)	0.001
	RHF (N, %)	7 (22.6)	6 (33.3)	0.411
Echocardiography	Visibility of worms (N, %)	15 (48.4)	8 (44.4)	0.790
	MPA/Ao ratio (Mean ± SD)	1.07 ± 0.14[a)]	1.20 ± 0.19	0.011
	RVD/LVD ratio (Mean ± SD)	0.92 ± 0.63[a)b)]	1.45 ± 1.03[b)]	0.028
	Presence of PH (N, %)	19 (61.3)	11 (61.1)	0.812
Presence of clinical signs (N, %)		22 (71.0)	15 (83.3)	0.332

[a)]Significant difference with LD group. [(b)]Significant difference with the normal reference range.
VHS, vertebral heart scale; RV, Right ventricular; MPA, main pulmonary artery; RHF, right heart failure; Ao, aortic root; RVD, right ventricular basal diameter; LVD, left ventricular basal diameter; PH, pulmonary hypertension.

Table 3. Associations between existence of clinical signs and other factors

Parameter	SD group (n = 31)	LD group (n = 18)
VHS	p = 0.183	p = 0.892
Reverse D shape	p = 0.081	p = 0.814
Visibility of adult worm	p = 0.096	p = 0.330
MPA/Ao ratio	p = 0.049*	p = 0.587
RVD/LVD ratio	p = 0.000*	p = 0.099
Presence of PH	p = 0.018*	p = 0.004*

*Significant difference with respect to clinical signs ($p < 0.05$).
HWD, heartworm disease; VHS, vertebral heart scale; MPA, main pulmonary artery; Ao, aorta root; RVD, right ventricular basal diameter; LVD, left ventricular basal diameter; PH, pulmonary hypertension.

heart on thoracic radiography. Of these dogs, five (83.3%) showed heartworms on echocardiography. In the LD group, twelve dogs showed reverse D shape, of which 10 dogs (83.3%) had visible worms on echocardiography.

In the SD group, approximately half of the dogs (15/29, 51.7%) showed dilation of peripheral pulmonary artery on thoracic radiographs and the other half of the dogs did not. In the LD group, dilated peripheral pulmonary artery more frequently appeared (14/18, 77.8%).

The mean MPA/Ao ratios in SD group for positive visibility of worms, PH, and RHF were 1.09 ± 0.14, 1.11 ± 0.14 and 1.12 ± 0.16, respectively. These ratios were upper limit of the normal reference range. The mean MPA/Ao ratios in LD group for the same factors were 1.22 ± 0.12, 1.29 ± 0.16 and 1.37 ± 0.19, respectively. These ratios were significantly higher than normal reference range ($p = 0.045$, $p = 0.016$, and $p = 0.039$, respectively).

Respiratory signs were the most common in both groups (Table 3). The associations between clinical signs and other factors are shown in Table 3. PH had a significant association with the presence of clinical signs in SD and LD groups. In SD group, the higher MPA/Ao ratio and RVD/LVD ratio, the more likely presence of clinical signs presents.

Using echocardiography as the gold standard, sensitivity, specificity and accuracy of radiography for RV hypertrophy were calculated as well as the positive and negative predictive values (Table 4). The sensitivity, positive predictive value, and accuracy of the LD group were higher than those of SD group.

Discussion

VHS is a quantitative method for evaluation of cardiac chamber enlargement on radiography (6). On thoracic radiography in dogs with HWD, RV hypertrophy can be observed and caused by the presence of adult worms and PH (17). In the previous study, VHS was higher than the average reference of each breed in large dogs with HWD (18). In this study, there was no significant difference from the reference range of VHS (8.7-10.7 v) not only between both groups but also in dogs with factors that could cause RV hypertrophy. This discrepancy may be caused by not applying breed specific VHS reference range or due to early stage HW diseases where generalized cardiomegaly didn't appear yet.

In veterinary medicine, cardiovascular changes on thoracic radiography may vary, but dilation of MPA and RV hypertrophy referred to reverse D shape of the heart is known as typical feature of HWD (17). According to the study of 83 medium or large dogs with HWD, cardiovascular changes on thoracic radiography were found in 60 dogs (72.29%) (18). In the present study, small dogs did not have remarkable cardiovascular changes including reverse D shape, dilation of MPA and RV hypertrophy. For example, a dog of SD group had only mild RV hypertrophy on thoracic radiography but showed large worm burden in RA and RV and RV enlargement on echocardiography, and worms in caudal vena cava on abdominal ultrasonography. It is thought that thoracic radiography often does not reflect the severity of cardiovascular changes by HW diseases in small dogs.

PH and physical obstruction caused by the presence of worms can lead to the dilation of MPA. RV hypertrophy is also a response to PH (17). Although the proportion of PH was similar between both groups, small dogs had a higher incidence of mild PH, while large dogs had severe PH. This result may reflect the feature of cardiovascular change in small dogs. However, it may just present the tendency of early visit to the hospitals of small dogs. Small dogs usually live indoor, which make owner easily notice clinical signs.

According to a study of 212 cats with HWD, radiographic signs were not suggestive or consonant in 122 cats (57.5%) (4). This is similar results to those of small dogs in the present study. Small body size like cats and small dogs may be associated with the minimal to mild radiographic cardiovascular changes, but further study would be required.

In both groups, PH had a significant association with the presence of clinical signs. PH is known as the cause of RV myocardial impairment, elevated RV end-diastolic pressure and signs of RHF. Cardiac output also gradually declines as the RHF progresses. When cardiac output becomes insufficient, exercise intolerance, dyspnea, fatigue, and syncope can occur (11).

A major limitation of this study is that duration of infec-

Table 4. Accuracy of radiography for evaluation of the right ventricle enlargement in dogs with HWD

Group	Results (n)				Statistics (%)				
	TP	TN	FP	FN	Sens.	Spec.	PPV	NPV	Acc.
SD group (n = 31)	9	8	9	7	56.3	47.1	56.3	53.3	54.8
LD group (n = 18)	12	2	1	3	80.0	66.6	92.3	40	77.8

HWD, heartworm disease; TP, true positive; TN, true negative; FP, false positive; FN, false negative, Sens., sensitivity; Spec., specificity; PPV, Positive predictive value; NPV, Negative predictive value; Acc., accuracy.

tion and the severity of clinical signs was not considered. Another limitation of this study is the small number of dogs with HWD, so that breed variation was not reflected. Further study is required in a larger experimental animal population.

In conclusion, the proportion of reverse D shape of the heart on thoracic radiography was significantly lower in the small dogs (19.4%) than the large dogs (66.7%). The MPA/Ao ratio and RVD/LVD ratio with echocardiography in the small dogs were significantly smaller than those of the large dogs. The accuracy of thoracic radiography for right ventricular hypertrophy in the small dogs was lower than in the large dogs. The result of this study suggests that thoracic radiography have a tendency to underestimate the severity of HWD in small dogs. Therefore, thoracic radiography should be used with echocardiography to accurately evaluate HWD severity of small dogs.

Acknowledgement

This work was supported by research funds of Chungnam National University.

References

1. Atkins CE, Keene BW, McGuirk SM. Pathophysiologic mechanism of cardiac dysfunction in experimentally induced heartworm caval syndrome in dogs: an echocardiographic study. Am J Vet Res. 1988; 49: 403-410.
2. Atkins CE. Canine heartworm disease. In: Ettinger SJ, Feldman EC, editors. Textbook of Veterinary Internal Medicine. 7th ed. Philadelphia: Saunders. 2010: 1353-1380.
3. Boon JA. Manual of veterinary echocardiography. 2th ed. Williams & Wilkins. 2011: 350-351.
4. Brawner WR, Dillon AR, Robertson-Plouche CK, Guerrero J. Radiographic diagnosis of feline heartworm disease and correlation to other clinical criteria: results of a multicenter clinical case study. Vet Therapeut 2000; 1: 81-87.
5. Brown DJ, Knight DH, King RR. Use of pulsed-wave Doppler echocardiography to determine aortic and pulmonary velocity and flow variables in clinically normal dogs. Am J Vet Res 1991; 52: 543-550.
6. Buchanan JW, Bücheler J. Vertebral scale system to measure canine heart size in radiographs. J Am Vet Med Assoc 1995; 206: 194-199.
7. Jurcut R, Giusca S, La Gerche A, Vasile S, Ginghina C, Voigt JU. The echocardiographic assessment of the right ventricle: what to do in 2010. Eur J Echocardiogr 2010; 11: 81-96.
8. Kou S, Caballero L, Dulgheru R, Voilliot D, De Sousa C, Kacharava G, Gomez De Diego JJ. Echocardiographic reference ranges for normal cardiac chamber size: results from the NORRE study. Eur Heart J-Card Img 2014; 15: 680-690.
9. Losonsky JM, Thrall DE, Lewis RE. Thoracic radiographic abnormalities in 200 dogs with spontaneous heartworm infestation. Vet Radiol 1983; 24: 120-123.
10. Nelson RW. Small Animal Internal Medicine. 5th ed. Elsevier Health Sciences. 2014: 173-189.
11. Pyle RL, Abbott J, Maclean H. Pulmonary hypertension and cardiovascular sequelae in 54 dogs. Intern J Appl Res Vet Med 2004; 2: 99-109.
12. Rudski LG, Lai WW, Afilalo J, Hua L, Handschumacher MD, Chandrasekaran K, Schiller NB. Guidelines for the echocardiographic assessment of the right heart in adults: a report from the American Society of Echocardiography: endorsed by the European Association of Echocardiography, a registered branch of the European Society of Cardiology, and the Canadian Society of Echocardiography. J Am Soc Echocardiogr 2010; 23: 685-713.
13. Schafer M, Berry CR. Cardiac and pulmonary artery mensuration in feline heartworm disease. Vet Radiol Ultrasound 1995; 36: 499-505.
14. Serres F, Chetboul V, Gouni V, Tissier R, Sampedrano CC, Pouchelon JL. Diagnostic value of echo-Doppler and tissue Doppler imaging in dogs with pulmonary arterial hypertension. J Vet Int Med 2007; 21: 1280-1289.
15. Tai TC, Huang HP. Echocardiographic assessment of right heart indices in dogs with elevated pulmonary artery pressure associated with chronic respiratory disorders, heartworm disease, and chronic degenerative mitral valvular disease. Veterinari Medicina 2013; 58: 613-620.
16. Thrall DE, Badertscher RR, Lewis RE, McCall JW, Lonsonsky JM. Radiographic changes associated with developing dirofilariasis in experimentally infected dogs. Am J Vet Res 1980; 41: 81-90.
17. Thrall DE. Textbook of Veterinary Diagnostic Radiology. 7th ed. Elsevier Health Sciences. 2018: 684-709.
18. Tudor N, Ionita L, Tapaloaga D, Tudor P, Ionita C, Vlagioiu C. Radiographic cardiopulmonary changes in dogs with heartworm disease. Romanian Biotechnological Letters 2014; 19: 9918-9924.