

Embolization for treating posttraumatic pseudoaneurysm of the sphenopalatine artery

Jeong Jin Chun¹,
Chang Yong Choi²,
Syeo Young Wee¹,
Woo Jin Song¹,
Hyun Gyo Jeong¹

¹Department of Plastic and Reconstructive Surgery, Soonchunhyang University College of Medicine, Gumi;

²Department of Plastic and Reconstructive Surgery, Soonchunhyang University College of Medicine, Bucheon, Korea

Posttraumatic pseudoaneurysms of the sphenopalatine artery are rare. Only a few cases have been reported. We report two cases of hemorrhage due to pseudoaneurysm of the sphenopalatine artery. The hemorrhage was uncontrollable. It required embolization. Two patients visited our hospital for treatment of zygomaticomaxillary complex fracture. At the emergency room, patients presented with massive nasal bleeding which ceased shortly. After reduction of the fracture, patients presented persistent nasopharyngeal bleeding. Under suspicion of intracranial vessel injury, we performed angiography. Angiograms revealed pseudoaneurysms of the sphenopalatine artery. Endovascular embolization was performed, leading to successful hemostasis in both patients. Due to close proximity to pterygoid plates, zygomaticomaxillary complex fracture involving pterygoid plates may cause injury of the sphenopalatine artery. The only presentation of sphenopalatine artery injury is nasopharyngeal bleeding which is common. Based on our clinical experience, although pseudoaneurysm of maxillary artery branch after maxillofacial trauma has a low incidence, suspicion of injury involving deeply located arteries and early imaging via angiogram are recommended to manage recurrent bleeding after facial trauma or surgery.

Keywords: Embolization, therapeutic / Maxillary artery / Pseudoaneurysm

INTRODUCTION

Fracture of the zygomaticomaxillary complex (ZMC) is a common injury observed in maxillofacial units with documented well management [1]. Pseudoaneurysms can occur following partial disruption in the wall of blood vessel, causing hematoma that is either contained by vessel adventitia or perivascular soft tissue [2]. Intracranial pseudoaneurysm is a rare complication of blunt cerebrovascular injury. Its incidence is less than 1% [3]. Specifically, there are only a few reports of pseudoaneurysm in facial bone fracture [1,4-8]. Despite a low incidence, due to reduced support from the vessel wall, the risk of pseudoaneurysm

rupture is much higher than that of true aneurysm [9]. This can cause secondary hemorrhage from the vessel at any time which may lead to life-threatening situation [2].

Herein, we report two cases of locally uncontrollable hemorrhage after ZMC fracture. The hemorrhage was treated by embolization of the maxillary artery branch. Our patients presented persistent nasal bleeding and malar swelling that might be overlooked by surgeons. Under suspicion of intracranial vessel injury, we performed angiograms and made diagnosis of pseudoaneurysm.

CASE REPORTS

Case 1

A 46-year-old female patient was transferred to our hospital for treating swelling and tenderness associated with left malar area following blunt trauma. At the emergency room, the patient

Correspondence: Hyun Gyo Jeong

Department of Plastic and Reconstructive Surgery, Soonchunhyang University College of Medicine, 179 1(il)gongdan-ro, Gumi 39371, Korea
E-mail: 33044@schmc.ac.kr

This work was supported in part by Soonchunhyang University Research Fund.

Received May 17, 2019 / Revised July 16, 2019 / Accepted July 29, 2019

presented with nasal bleeding which ceased shortly. Based on computed tomography (CT) scanning, a diagnosis of fractured left ZMC was established (Fig. 1A).

Three days after the trauma, the patient underwent reduction of fracture intraorally. No immediate postoperative bleeding was seen. Postoperative X-ray showed successful reduction of the fracture. However, 3 days after the operation, she presented with persistent nasopharyngeal bleeding accompanied by acute onset of severe swelling and pain of the left malar area. We conducted exploration of the oral incision under local anesthesia. The arterial bleeding originated under zygomaticomaxillary buttress. Bleeding was controlled with an electric coagulator and manual compression.

Two days after the reoperation, the patient presented with an-

other nasopharyngeal bleeding with severe swelling. At this time, her blood pressure was 110/70 mmHg and her pulse rate was 72 beats/min. Her hemoglobin concentration and hematocrit level were 9.6 g/dL and 27.7%, respectively. Her coagulation profile was within normal limits. Fluid was replaced with crystalloids followed by monitoring of vital signs. Arterial bleeding occurred from the oral incision which was opened to perform another hemostasis.

However, we suspected active bleeding and traced its origin behind the ZMC which could not be approached via operative wound. One day later, we conducted angiography which revealed a huge pseudoaneurysm of the sphenopalatine artery (Fig. 1B). Endovascular embolization of internal maxillary artery was performed using 500 µm polyvinyl alcohol particles

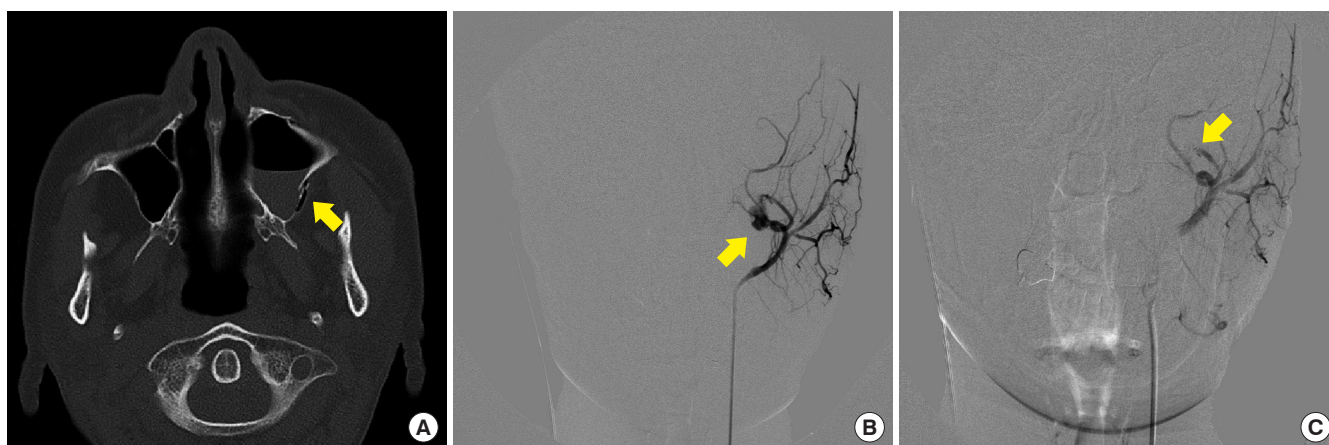


Fig. 1. (A) Preoperative computed tomography scan of the facial bone in a 46-year-old female (patient 1) presenting with left zygomaticomaxillary complex fracture (arrow) following blunt trauma. (B) Angiography of patient 1 revealing huge pseudoaneurysm of left sphenopalatine artery (arrow). (C) Angiography of patient 1 after endovascular embolization of internal maxillary artery with gelatin sponge and coil (arrow). Embolization was successfully done without any recurrent bleeding after the procedure.

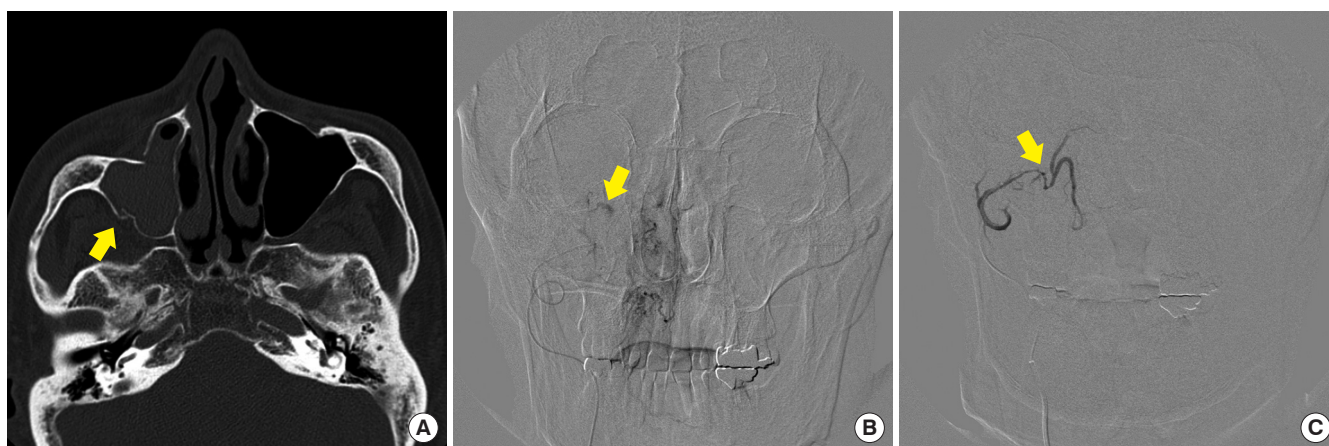


Fig. 2. (A) Preoperative computed tomography scan of the facial bone in a 60-year-old male (patient 2) presenting with right zygomaticomaxillary complex fracture (arrow) following blunt trauma. (B) Angiography of patient 2 revealing pseudoaneurysm and extravasation of left sphenopalatine artery (arrow). (C) Angiography of patient 2 after endovascular embolization of sphenopalatine artery with gelatin sponge (arrow). Embolization was successfully done without recurrent bleeding episode after the procedure.

(Bearing nsPVA; Merit Medical, South Jordan, UT, USA), 1,000 µm gelatin sponge (Cali gelfoam; Cook Medical, Bloomington, IN, USA), and 2/3 mm coil (Tornado Microcoil; Cook Medical). Immediate post-embolization angiography demonstrated successful disappearance of extravasation (Fig. 1C). After embolization, additional bleeding was not observed and the patient was discharged one week after embolization. At the time of discharge, her hemoglobin concentration and hematocrit level were 11.0 g/dL and 33.1%, respectively. Follow-up performed a few months later revealed no postoperative bleeding after embolization.

Case 2

A 60-year-old male patient presented at our emergency room with complaints of swelling and tenderness of right malar area and mild nasal bleeding due to trauma. Clinical and radiological assessment revealed a fracture of right ZMC (Fig. 2A). At 6 days after the trauma, a reduction was performed without any complication. However, during closure of oral incision, persistent bleeding was detected. It was uncontrollable despite local compression or hemostasis with an electric coagulator. Hemodynamic parameters were normal. The patient was immediately transferred to interventional radiology department for angiography. Angiography demonstrated extravasation from a pseudoaneurysm of the sphenopalatine artery (Fig. 2B). Embolization was performed with a 350- to 500-µm gelatin sponge (Cali gelfoam; Cook Medical). Successful embolization of the pseudoaneurysm was confirmed by post-procedure angiography (Fig. 2C). No complication or recurrence of hemorrhage was detected after embolization. Postoperative hemodynamic parameters remained normal. Postoperative radiological investigations showed reduction of fracture. Follow-up at a few months later revealed no complication of recurrent bleeding.

DISCUSSION

Management of blunt facial trauma and hemorrhage is well-established. The first step should be airway management to ensure breathing and circulation. Nasal packing, correction of coagulopathy, reduction of fractures, and arterial ligation remain standard treatments. However, in unstable patients or patients with persistent bleeding, angiographic embolization should be considered [10,11]. We followed this protocol. Based on persistent bleeding of patients, we suspected intracranial bleeding and performed angiograms. In both patients, we diagnosed pseudoaneurysms of sphenopalatine artery, the deepest branch of maxillary artery. Endovascular embolization was performed and bleeding was ceased.

The mechanism of pseudoaneurysm formation after fracture is partial transection of the vessel and hematoma in arterial wall by bone fragment [9,12]. Traumatic pseudoaneurysm of sphenopalatine artery is extremely rare because of its deep anatomic location and protection from bony structure. However, due to its close proximity to pterygoid plates, ZMC fracture involving these areas may cause injury of the sphenopalatine artery. Sphenopalatine artery is divided into lateral and septal posterior nasal arteries. Therefore, the only presentation of sphenopalatine artery injury is nasopharyngeal bleeding which is common [12].

As far as we know, no study has reported the incidence of pseudoaneurysm after ZMC fracture so far. There are some reports about pseudoaneurysm after maxillofacial fracture. Types of fracture included severe ZMC fracture and panfacial fracture [4-8]. In these reports, diagnosis was done after the patient presented life-threatening massive hemorrhage. The diagnosis of pseudoaneurysm is based on physical examination such as bruit or expanding masses [2,12,13]. However, in craniofacial trauma, these arterial injuries are not evident during primary physical examination due to its deep location [7,9,12,13]. Likewise, arterial injuries were not detected initially in our cases. During close observation, patients presented not massive bleeding, but some common symptoms such as persistent nasopharyngeal bleeding.

Pseudoaneurysm can be confirmed by imaging modalities such as contrast enhanced CT or angiography [7,9]. If a pseudoaneurysm is diagnosed, the treatment of choice is transcatheter embolization [5,13]. Ligation of bleeding artery by surgical treatment is an option. However, its effect is variable because of collateral circulation from the contralateral side and communication with the internal carotid system [5,10]. One advantage of embolization is that relatively distal vessels may be obliterated while more proximal vessels may be spared [5,7,13,14]. This may minimize the risk of persistent hemorrhage from collateral flow and aseptic necrosis of maxilla [7,13]. In multiple studies, it has been shown that embolization can successfully arrest bleeding in patients with hemorrhage with a success rate of up to 96% and a major complication rate of 3% [14].

Based on our clinical experience, we suggest a few key findings that surgeons should consider. First, we found that both patients presented with preoperative nasal bleeding. Nasal bleeding after injury or operation is common while the antrum clears [1]. Therefore, it can be ignored by surgeons. However, our cases suggest that nasal bleeding alone may suggest injury to intracranial vessels, especially in sphenopalatine artery injury.

Second, bleeding can originate in branches of the maxillary artery that enter the pterygoid plate. In this case, local hemosta-

sis such as nasal packing cannot control the bleeding adequately [1]. Therefore, if hemorrhage persists after facial trauma, according to protocol for controlling hemorrhage in facial trauma, early intervention with imaging modalities such as enhanced CT and angiogram is recommended [11].

In conclusion, although pseudoaneurysm resulting from maxillofacial trauma is rare, it may be life-threatening. Therefore, close postoperative follow-up of patients is necessary for detecting bleeding foci, even in cases without bleeding during surgical procedure. Surgeons should not overlook nasal bleeding or acute onset of swelling as they might be precursors of life-threatening hemorrhage.

NOTES

Conflict of interest

No potential conflict of interest relevant to this article was reported.

Ethical approval

The study was performed in accordance with the principles of the Declaration of Helsinki. Written informed consents were obtained.

Patient consent

The patients provided written informed consent for the publication and the use of their images.

ORCID

Jeong Jin Chun <https://orcid.org/0000-0001-6584-5782>
 Chang Yong Choi <https://orcid.org/0000-0002-6385-0817>
 Syeo Young Wee <https://orcid.org/0000-0002-1787-9715>
 Woo Jin Song <https://orcid.org/0000-0002-8957-3950>
 Hyun Gyo Jeong <https://orcid.org/0000-0002-6378-6093>

REFERENCES

- Hollow P, D'Sa A, McAndrew PG. Life-threatening haemorrhage after elevation of a fractured zygoma. *Br J Oral Maxillofac Surg* 1999;37:448-50.
- Avelar RL, Goelzer JG, Becker OE, de Oliveira RB, Raupp EF, de Magalhaes PS. Embolization of pseudoaneurysm of the internal maxillary artery after orthognathic surgery. *J Craniofac Surg* 2010;21:1764-8.
- Guyot LL, Kazmierczak CD, Diaz FG. Vascular injury in neurotrauma. *Neurol Res* 2001;23:291-6.
- Foletti JM, Bruneau S, Puech B, Guyot L, Chossegros C. Life-threatening hemorrhage after zygomatic bone surgery: about 2 posttraumatic cases. *Rev Stomatol Chir Maxillofac Chir Orale* 2016;117:183-7.
- Rogers SN, Patel M, Beirne JC, Nixon TE. Traumatic aneurysm of the maxillary artery: the role of interventional radiology: a report of two cases. *Int J Oral Maxillofac Surg* 1995;24:336-9.
- Austin RE, Stewart TL, Antonyshyn OM. Intracranial pseudoaneurysm associated with orbitozygomatic complex fracture. *J Craniofac Surg* 2014;25:1410-2.
- Fan X, Mao Q. Life-threatening oral haemorrhage of a pseudoaneurysm after raising of a fractured zygoma. *Br J Oral Maxillofac Surg* 2002;40:508-9.
- Nastro Siniscalchi E, Catalfamo L, Pitrone A, Papa R, Fama F, Lo Giudice G, et al. Traumatic pseudoaneurysm of the internal maxillary artery: a rare life-threatening hemorrhage as a complication of maxillofacial fractures. *Case Rep Med* 2016;2016:9168429.
- Alonso N, de Oliveira Bastos E, Massenburg BB. Pseudoaneurysm of the internal maxillary artery: a case report of facial trauma and recurrent bleeding. *Int J Surg Case Rep* 2016;21:63-6.
- Liu WH, Chen YH, Hsieh CT, Lin EY, Chung TT, Ju DT. Transarterial embolization in the management of life-threatening hemorrhage after maxillofacial trauma: a case report and review of literature. *Am J Emerg Med* 2008;26:516.
- Ho K, Hutter JJ, Eskridge J, Khan U, Boorer CJ, Hopper RA, et al. The management of life-threatening haemorrhage following blunt facial trauma. *J Plast Reconstr Aesthet Surg* 2006;59:1257-62.
- Cohen S, Anastassov GE, Chuang SK. Posttraumatic pseudoaneurysm of the sphenopalatine artery presenting as persistent epistaxis: diagnosis and management. *J Trauma* 1999;47:396-9.
- Lanigan DT, Hey JH, West RA. Major vascular complications of orthognathic surgery: false aneurysms and arteriovenous fistulas following orthognathic surgery. *J Oral Maxillofac Surg* 1991;49:571-7.
- Khanna S, Dagum AB. A critical review of the literature and an evidence-based approach for life-threatening hemorrhage in maxillofacial surgery. *Ann Plast Surg* 2012;69:474-8.