



# Journal of Acupuncture Research

Journal homepage: <http://www.e-jar.org>

Case Report

## Treatment of Ramsay Hunt Syndrome Using Korean Medicine including Sinbaro3 Pharmacopuncture: A Case Report



Won Bin Shin<sup>1,\*</sup>, Ji Won Park<sup>1</sup>, Hyo Jung Choi<sup>1</sup>, Jin Namgoong<sup>2</sup>, Sang Gyun Kim<sup>3</sup>, Baek Ki Min<sup>4</sup>

<sup>1</sup> Department of Acupuncture and Moxibustion Medicine, Bucheon Jaseng Hospital of Korean Medicine, Bucheon, Korea

<sup>2</sup> Department of Korean Medicine Obstetrics and Gynecology, Bucheon Jaseng Hospital of Korean Medicine, Bucheon, Korea

<sup>3</sup> Department of Acupuncture and Moxibustion Medicine, Haeundae Jaseng Hospital of Korean Medicine, Busan, Korea

<sup>4</sup> Department of Acupuncture and Moxibustion Medicine, National Medical Center, Seoul, Korea

### ABSTRACT

#### Article history:

Submitted: April 30, 2019

Revised: June 19, 2019

Accepted: August 5, 2019

#### Keywords:

Korean medicine,  
Ramsay Hunt Syndrome,  
Sinbaro3 pharmacopuncture

This study was conducted to investigate whether treatment with Korean medicine might help to improve symptoms of patients diagnosed with Ramsay Hunt Syndrome. A patient diagnosed with Ramsay Hunt Syndrome was hospitalized for 15 days from October 4, 2018 to October 18, 2018 and treated using Korean medicine (Sinbaro3 pharmacopuncture, acupuncture, electroacupuncture, and herbal medicine). Therapeutic effects were evaluated using the Numerical Rating Scale (NRS), House-Brackmann grade, Yanagihara's score survey, and Digital Infrared Thermographic Imaging (DITI). After treatment, the Numerical Rating Scale score (6 at admission down to 2 points at discharge), House-Brackmann grade (Grade V down to Grade II), Yanagihara's score (6.0 up to 22.0), and Digital Infrared Thermographic Imaging showed improvement from admission to discharge. Treatment with traditional Korean medicine, may help improve symptoms of Ramsay Hunt Syndrome such as facial nerve paralysis, neuralgia after paraplegia, hearing difficulties, and dizziness.

<https://doi.org/10.13045/jar.2019.00115>  
pISSN 2586-288X eISSN 2586-2898

©2019 Korean Acupuncture & Moxibustion Medicine Society. This is an open access article under the CC BY-NC-ND license (<http://creativecommons.org/licenses/by-nc-nd/4.0/>).

### Introduction

Ramsay Hunt Syndrome (RHS) is a disorder of the geniculate ganglion that is caused by Herpes zoster virus. It occurs when the latent infection of varicella-zoster virus in the geniculate ganglion is reactivated, and causes inflammation in the nerve cells [1]. Typical symptoms of RHS are facial nerve paralysis, vesicular exanthema in the external auditory canal and other cortical areas, and mucous membranes of the mouth and pharynx, causing dizziness and hearing loss [2]. In addition, RHS exhibits brain-neuropathy symptoms, viral infection symptoms, auditory irritation, abnormal sensations of the neck, and pain that tends to be greater than that of Bell's palsy [3]. In clinical practice, RHS is diagnosed during a medical, neurological and Digital Infrared Thermographic Imaging (DITI) or magnetic resonance imaging, if necessary [4]. The rates of autotherapy and complete recovery of

Bell's palsy are approximately 70% and 95%, respectively, whereas those of RHS are approximately 30% and 60%, respectively [1]. In addition, owing to a higher probability of complete degeneration of the nerve cells in RHS compared with Bell's palsy, prevention of permanent deformation by facial nerve paralysis is an important treatment goal [4]. In Korean medicine, although active research on Bell's palsy has been conducted, there is a lack of research on RHS treatment.

Sinbaro3 pharmacopuncture is mainly composed of Harpagide and cinnamic acid produced by hydrolysis of the secondary root of *Harpagophytum procumbens* [5]. Sinbaro3 inhibits the release, synthesis and production of inflammatory mediators including histamine, polypeptides, kinins, and prostaglandins, which are recruited to inflammatory sites [6]. It has been suggested that Sinbaro3 pharmacopuncture may possess analgesic properties and promote anti-inflammatory actions. Yun et al [7] and Park et al

\*Corresponding author.

Department of Acupuncture and Moxibustion Medicine, Bucheon Jaseng Hospital of Korean Medicine, Bucheon, Korea

Email: [swb3702@naver.com](mailto:swb3702@naver.com)

ORCID: Won Bin Shin <https://orcid.org/0000-0002-3562-437X>

©2019 Korean Acupuncture & Moxibustion Medicine Society. This is an open access article under the CC BY-NC-ND license (<http://creativecommons.org/licenses/by-nc-nd/4.0/>).

[8] have reported beneficial treatment effects on musculoskeletal disorders using Korean medicine in combination with Sinbaro3 pharmacopuncture. However, these treatment modalities have been limited to musculoskeletal disorders and have not been used in the treatment of patients diagnosed with RHS. Here we report the case of a patient diagnosed with RHS, an inflammatory facial nerve paralysis. The patient was treated using Korean medicine in combination with Sinbaro3 pharmacopuncture over the 15-day period of hospitalization and showed improvement of symptoms.

## Case Report

### Patient

OOO(M/58)

### Chief complaints

The patient had symptoms of left-sided facial nerve palsy and was unable to wrinkle either his forehead on the left or his nose. Further, he experienced difficulties on the left side whilst smiling and dribbled food during eating. The paralysis was accompanied by a facial tingling sensation. In addition, the patient experienced postherpetic and facial neuralgia, postauricular pain, painful blisters, dizziness, nystagmus, and hearing loss.

### Onset

The onset of symptoms began on September 19, 2018 when his ear started to hurt. He had suffered extreme stress and fatigue prior to this.

### Present illness and medical history

The patient was diagnosed with RHS at the local University hospital on September 19, 2018, where he was treated for 13 days and administered antiviral drugs. However, only minor improvements in his condition were experienced, and he was referred to Bucheon Jaseng Korean medicine hospital for treatment. His medical history was not significant.

### Duration of treatment

The patient received treatment between October 04, 2018 and October 18, 2018 (15 days of hospitalization).

### Patient protection policy on patient information use

This case report was a retrospective chart review, and written informed consent was obtained from the patient. In order to protect the information, and rights of the patient, the patient's medical records were collected and approved by the Institutional Review Board at the Jaseng Korean medicine hospital for use in this study (IRB No.: 2019-04-004).

### Treatment

#### Pharmacopuncture treatment

Sinbaro3 pharmacopuncture (Jaseng Wonoe Tangjunwon, Namyangju, Korea) was administered twice a day at a dose of 0.1–0.2 mL, per acupoint, via injection to the left GB14, TE23, TE17, ST07, ST03, ST04, and ST06, using a disposable 30 gauge x 8 mm needle, 1/2 syringe (Sungsimmedical, Bucheon, Korea), to a depth of 0.3–0.5 cm.

#### Acupuncture treatment

Acupuncture treatment was performed by a Korean medicine doctor with 2 - years of clinical experience. Standardized disposable needles (0.20 mm × 30 mm) made of stainless steel (The Eastern Acupuncture Equipment Manufacturer, Boryung, Korea) were used. Acupuncture treatment was administered to the left GB14, TE23, TE17, ST03, ST04, and ST06 for 15 minutes, and performed twice a day, 8 hours apart, at a needle depth of 0.3–0.5 cm.

#### Electroacupuncture treatment

Electroacupuncture was performed twice a day using a STN-330 device (Stratek, Korea). Electrodes were placed on GB14–TE23, TE17–ST03, and ST04–ST06. The intensity of the stimulation was 2–3 mA, and the frequency was 1.0 Hz, and the treatment was performed for 15 minutes.

#### Herbal medicine treatment

The patient was prescribed Kamidaibo decoction, comprising of Zingiberis Rhizoma Crudus (3 g), Jujubae Fructus (2 g), Angelicae Gigantis Radix, Hoelen, Paeoniae Radix Alba, Atractylodis Rhizoma Alba, Rehmanniae Radix Preparata, Ginseng Radix, Cnidii Rhizoma, Astragali Radix (0.7 g), Osterici Radix, Angelicae Pubescentis Radix, Eucommiae Cortex, Chaenomelis Fructus, Saposhnikoviae Radix, Linderae Radix, Achyranthis Radix, Coicis Semen (0.5 g), and Glycyrrhizae Radix, Aucklandiae Radix, Aconiti Lateralis Preparata Radix, Cinnamomi Cortex (0.3 g). The patient took 100 mL of the herbal medicine 3 times a day.

#### Evaluation tools

##### Numerical rating scale

To evaluate the intensity of postherpetic neuralgia, the patient was evaluated on the day of admission, 1 week after admission, and on the day of discharge, using the NRS. This scale requires patients rate their pain, where 10 is the worst imaginable pain. The evaluation was conducted by another Korean medicine doctor who was not a treatment practitioner.

##### House–Brackmann facial grading scale (Appendix A)

To evaluate facial function, the patient was evaluated on the day of admission, 1 week after admission, and on the day of discharge using the House–Brackmann facial grading scale. Grade I indicated normal facial function and Grade VI indicated impaired facial function. The House–Brackmann facial grading scale could also be used to evaluate facial nerve recovery. Grades I and II represented satisfaction with the recovery, and Grades III and IV indicated that the symptoms experienced were still unsatisfactory [3]. The evaluation was conducted by another Korean medicine doctor who was not a treatment practitioner.

##### Yanagihara's unweighted grading system (Appendix B)

To evaluate facial function, and the degree of facial nerve paralysis, the patient was evaluated on the day of admission, 1 week after admission, and on the day of discharge using Yanagihara's unweighted grading system. Complete paralysis was evaluated as 0, and normal function was given 4 points (covering 10 items including the forehead and nose wrinkling and closed eye). Based on a total score of 40 points, the lower the score in Yanagihara's unweighted grading system, the worse the paralysis [9]. The evaluation was conducted by another Korean medicine doctor who was not a treatment practitioner.

##### DITI

To evaluate the degree and prognosis of facial nerve palsy, the

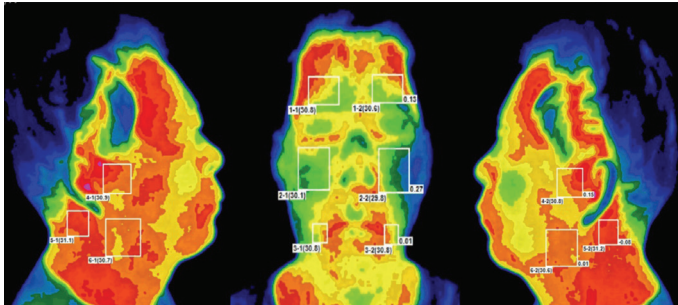


Fig. 1. Digital infrared thermographic imaging taken on 05<sup>th</sup> October 2018.

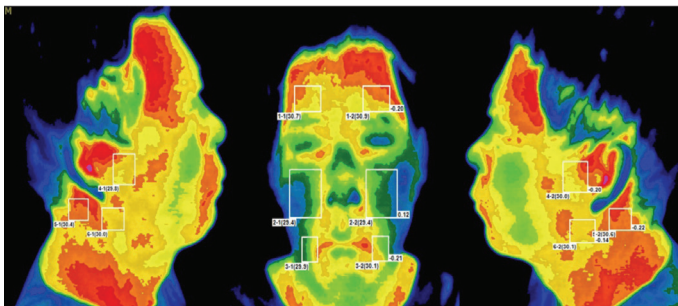


Fig. 2. Digital infrared thermographic imaging taken on 18<sup>th</sup> October 2018.

Table 1. Change of NRS, House-Brackmann Grade, and Yanagihara's Score.

	4 <sup>th</sup> October	11 <sup>th</sup> October	18 <sup>th</sup> October
NRS score	6	4	2
House-Brackmann grade	V	III	II
Yanagihara's score	6	16	22
At rest	2	3	3
Wrinkle forehead	0	2	3
Blink	1	2	3
Closure of eye lightly	1	2	4
Closure of eye tightly	2	3	4
Closure of eye involved side only	0	1	1
Wrinkle nose	0	1	1
Whistle	0	0	0
Grin	0	1	2
Depress lower lip	0	1	1

Table 2. Changes of Digital Infrared Thermographic Imaging.

	5 <sup>th</sup> October 2018			18 <sup>th</sup> October 2018		
	Right (°C)	Left (°C)	ΔT* (°C)	Right (°C)	Left (°C)	ΔT* (°C)
GB14	30.8	30.6	-0.13	30.7	30.9	0.20
ST03	30.1	29.8	-0.27	29.4	29.4	-0.12
ST04	30.8	30.8	-0.01	29.9	30.1	0.21
ST06	30.7	30.6	-0.01	30.0	30.1	0.14
ST07	30.9	30.8	-0.15	29.8	30.0	0.20
TE17	31.1	31.2	0.08	30.4	30.6	0.22

\* Value obtained by subtracting the right-side temperature from the left-side temperature.

temperature was measured at the site of pain and paralysis, using DITI, on the day after hospitalization (Fig. 1) and on the day of discharge (Fig. 2). Temperature measurement sites were GB14, ST03, ST04, ST06, ST07 and TE17 on both sides of the face. The region of interest (ROI) was set by a radiology technician at the same acupoint and size, on the day after hospitalization, and on the day of discharge. In addition, the temperature differences calculated by DITI were compared between the left and right sides.

**Evaluation results** (Tables 1 and 2)

NRS decreased from a score of 6.0 at admission to a score of 4.0 after 1 week, with a further decrease to 2.0 at discharge. The House-Brackmann grade changed from a Grade V at admission to a Grade III after 1 week, and a Grade II at discharge. The Yanagihara's score increased from 6.0 at the time of admission

to 16.0 after 1 week, and 22.0 at discharge. DITI showed the temperature difference at the time of admission and discharge at each specific site, and was measured as a reduction of 0.13°C and an increase of 0.2°C at GB14, a reduction of 0.27°C and a reduction of 0.12°C at ST03, a reduction of 0.01°C and an increase of 0.21°C at ST04, a reduction of 0.01°C and an increase of 0.14°C at ST06, a reduction of 0.15°C and an increase of 0.2°C at ST07, and an increase of 0.08°C and an increase of 0.22°C at TE17, respectively.

**Changes in other subjective symptoms**

Symptoms of dizziness persisted from the time of admission, to 1 week after admission. Following this time period, symptoms began to reduce. At discharge, the symptoms improved by 50%. In addition, left-side hearing loss, nystagmus, and abnormal

facial sensation improved steadily from admission, showing 80% improvement on the day of discharge.

### Evaluation of adverse events after treatment

To evaluate the post-treatment adverse events, the patient's discomfort was investigated. Edema, rubefaction, nausea, and dizziness 1 hour after treatment, and at 8 AM the next day were recorded. The patient didn't complain about these symptoms during their hospital stay.

### Discussion

RHS is the result of reactivation of latent varicella-zoster virus in the sensory ganglion of patients with a previous history of varicella-herpes zoster virus infecting the geniculate ganglion. The disease is characterized by peripheral facial nerve palsy with blistering pain in the face, or around the ears. In addition, paralysis of the fifth, seventh, and eighth cranial nerves is frequent; however, it is rare in the fourth, sixth, ninth, tenth, and eleventh cranial nerves, leading to various symptoms such as hearing loss, tinnitus, dizziness, and nystagmus [10]. RHS is also referred to as Herpes zoster oticus because it is a lymphoid inflammatory disease of the facial nerve, and paralysis in the facial canal, which is not limited to the geniculate ganglion [11].

In Western medicine, oral steroids and antiviral agents are used for the improvement of paralysis, and the treatment of the Herpes infection, respectively, and facial nerve decompression is used for relief from nerve edema and postherpetic neuralgia. However, all of these are limited to the treatment of symptoms [12]. Antivirals and steroids may promote the treatment of Herpes zoster, but their effects on facial nerve palsy and postherpetic neuralgia recovery are unclear [13-15].

Most case reports in Korean medicine are limited to Bell's palsy, and there is a lack of published case reports on RHS. Korean medicine including pharmacopuncture was effectively used for the treatment of facial nerve palsy compared with treatment excluding pharmacopuncture. It has been reported that treatment using Korean medicine including pharmacopuncture, resulted in beneficial improvements in the patient [16]. This study aimed to test the hypothesis that Korean medicine including Shinbaro3 pharmacopuncture would help to improve the symptoms of RHS. The pharmacopuncture was prepared via hydrolyzing *Harpagophytum procumbens*, which had been reported to be effective against inflammatory and painful diseases, degenerative diseases of musculoskeletal system, arthritis, and rheumatoid arthritis [5,17,18]. The patient received acupuncture and electroacupuncture, in combination with Shinbaro3 pharmacopuncture, and was prescribed herbal medicine treatments comprising the Kamidaibo decoction, which has an immunity-enhancing action [19].

After 15 days of inpatient treatment, the NRS score, which was applied to evaluate postherpetic neuralgia, decreased from a score of 6.0 at admission, to 2.0 at discharge, indicating that the treatment modality may have helped in pain relief. Furthermore, the House-Brackmann facial grading scale improved from Grade V to Grade II during hospitalization, and Yanagihara's unweighted grading system improved from a score of 6.0 at admission, to 22.0 at discharge, suggesting improvement in facial paralysis. In addition, dizziness improved by 50% at discharge, and hearing loss, nystagmus, and abnormal facial sensation were improved by 80%. DITI was performed on the next day of hospitalization, and at discharge, to evaluate the degree of objective symptom improvement and prognosis. Bae et al [20] reported that the

prognosis was worse when the temperature of the paralyzed side was lower than the unaffected side, and the prognosis was better as the temperature increased. In this study, the values obtained by subtracting the temperature from the left side to the right side of 6 acupoints were compared. Before treatment, the temperature of the left side acupoints were lower than that of the right side, except for TE17. After treatment, however, the temperature of the left side acupoints was higher than that of the right side, except for ST03. The ST03 temperature on the left side, however, was closer to the right value. This suggested that the prognosis of facial nerve palsy may improve after treatment.

In this study, the first case has been reported of a patient with RHS who has experienced improvement of facial nerve palsy, postherpetic neuralgia, hearing loss, dizziness, and other discomforts after receiving Korean medicine treatments including Shinbaro3 pharmacopuncture. However, the facts that the patient's position and posture are not exactly the same and that the person directly sets the location and size of the ROI box are limitations of this study because it may make the DITI result different. In addition, it could be possible that the improvement in symptoms was not due to Korean medicine treatments, but natural progression, or the latent effect of previous Western medicines. Moreover, the effectiveness of a single treatment method cannot be isolated because several Korean medicine treatments were applied to only one patient. Due to these limitations, further studies of the comparative effect will be needed as well as more case reports.

### Conflicts of Interest

The authors have no conflicts of interest to declare.

### References

- [1] An Editorial Department of Jungdam. Steps to Internal Medicine Part 10 Nerve, 2nd ed. Seoul (Korea): Jungdam; 2013. p. 113-116. [in Korean].
- [2] The Korean Academy of Family Medicine. Textbook of Family Medicine, 4th ed. Seoul (Korea): The Medicine Publisher; 2015. p. 645-653. [in Korean].
- [3] The Society of Korean Medicine Ophthalmology, Otolaryngology & Dermatology. Korean Medicine Otorhinolaryngology. Busan (Korea): Sunwoo; 2015. p. 136-140. [in Korean].
- [4] Park SY. Herpes Zoster Oticus. Korean J Otorhinolaryngol Head Neck Surg 2014;57:78-83. [in Korean].
- [5] Lee JH, Lee JW, Kim MJ, Kim EJ, Lee IH. Identification of Novel Standard Compounds for standardization of Shinbaro3 Pharmacopuncture. J Korean Med Rehabil 2015;25:65-72. [in Korean].
- [6] Mahomed IM, Ojewole JA. Analgesic, anti-inflammatory and anti-diabetic properties of *Harpagophytum procumbens* DC (pedaliaceae) secondary root aqueous extract. Phytother Res 2004;18:982-989.
- [7] Yun YU, Chung JH, Cheong SH, Moon BH, Choi YJ, Yoo SB et al. A Case Report of Supraspinatus Tendinitis and Subdeltoid Bursitis Patient Improved by Korean Medicine Treatment with Shinbaro3 Pharmacopuncture. J Korean Med Rehabil 2015;25:161-167. [in Korean].
- [8] Park JW, Yoon TK, Shin WB, Kim DR, Ryu WH, Jeon YH et al. The Effects of Korean Medicine Treatment on Posterior Cruciate Ligament Avulsion Fracture: A Case Report. J Acupunct Res 2018; 35:145-148. [in Korean].
- [9] Yanagihara N. Grading of Facial palsy. In Facial Nerve Surgery, Proceedings: Third International Symposium of Facial Nerve Surgery, Zurich, 1976. U. Fisch (Ed). Amstelveen, Netherlands: Kugler Medical Publications. Birmingham (AL): Aesculapius Publishing Co; 1977. p. 533-535.
- [10] Anis WS, Micic L, Giaccio D. Ramsay Hunt syndrome presenting as a cranial polyneuropathy. Cutis 1996;57:421-424.
- [11] Cho SH, Lee GY. A Case Report of Herpes Zoster Oticus. J Oriental Med Surg Ophthalmol Otolaryngol 2001;14:76-86. [in Korean].
- [12] Choi WS, Kim KS, Lee SD. Clinical studies on a case of Ramsay-Hunt Syndrome. J Korean Acupunct Moxib Soc 2001;18:237-247. [in Korean].
- [13] Kim YM, Baek YH, Lee JD, Park DS, Kim CH, Ko HK. Clinical Studies on 11 Cases of Facial Nerve Palsy in Herpes Zoster Oticus. J Korean Acupunct Moxib Soc 2002;19:234-246. [in Korean].

- [14] Park CW, Ahn KS, Choi SJ, Muhn DS. A Clinical Study of Facial Nerve Paralysis. *Korean J Otolaryngol* 1998;41:430-435. [in Korean].
- [15] Crabtree JA. Herpes Zoster Oticus. *Laryngoscope* 1968;78:1853-1878.
- [16] Sim SY. Clinical Research of Korean Medical Treatment for the Peripheral Facial Paralysis. *J Korean Med Ophthalmol Otolaryngol Dermatol* 2015;28:62-73. [in Korean].
- [17] Vlachojannis J1, Roufogalis BD, Chrubasik S. Systematic review on the safety of Harpagophytum preparations for osteoarthritic and low back pain. *Phytother Res* 2008;22:149-152.
- [18] Lanhers MC. Anti-inflammatory and analgesic effects of an aqueous extract of Harpagophytum procumbens. *Planta Med* 1992;58:117-123.
- [19] Lee CH, Kim DH, Jeong JH. Effects of Kamidaibotang (KDT) on Immunologic control function. *J Oriental Gynecol* 1999;12:225-252. [in Korean].
- [20] Bae HB, Ko WS, Yoon HJ. Study on the possibility of Digital Infrared Thermographic Imaging as a prognosis evaluation tool for patients with facial palsy. *J Korean Med Ophthalmol Otolaryngol Dermatol* 2017;30:62-75. [in Korean].

Appendix A. House-Brackmann Facial Grading Scale.

Grade	Description	Characteristics
I	Normal	Gross: Slight weakness noticeable on close inspection may have very slight synkinesis. Normal: Symmetry and tone.
II	Mild dysfunction	Motion: Forehead-Moderate to good function. Eye-Complete closure with minimum effort mouth-slight asymmetry. Gross: Obvious but not disfiguring difference between two sides, noticeable but severe synkinesis, contracture, and/or hemifacial spasm At rest- Normal symmetry and tone.
III	Moderate dysfunction	Motion: Forehead-Slight go moderate movement. Eye-Complete closure with effort. Mouth-Slight weak with maximum effort. Gross: Obvious weakness and/or disfiguring asymmetry. At rest: Normal symmetry and tone.
IV	Moderately severe dysfunction	Motion: Forehead-None. Eye-incomplete closure. Mouth-asymmetry with maximum effort. Gross: Only barely perceptible. At rest: Asymmetry.
V	Severe dysfunction	Motion: Forehead-None. Eye-incomplete closure. Mouth-Slight movement.
VI	Total paralysis	No movement

Appendix B. Yanagihara's Unweighted Grading System.

	Scale of rating				
At rest	0	1	2	3	4
Wrinkle forehead	0	1	2	3	4
Blink	0	1	2	3	4
Closure of eye lightly	0	1	2	3	4
Closure of eye tightly	0	1	2	3	4
Closure of eye involved side only	0	1	2	3	4
Wrinkle nose	0	1	2	3	4
Whistle	0	1	2	3	4
Grin	0	1	2	3	4
Depress lower lip	0	1	2	3	4