



## 스포츠 손상 후 비골건 봉합술

양기원, 박기철, 황지선, 이홍섭

울지대학교 을지병원 족부족관절정형외과

## Peroneal Tendon Repair in Sports Injury

Ki Won Young, Ki Chol Park, Ji Sun Hwang, Hong Seop Lee

Department of Foot and Ankle Surgery, Eulji Medical Center, Eulji University, Seoul, Korea

**Purpose:** This study examined the clinical outcomes and assessed the average time to return to play following a peroneal tendon repair in Korean athletes.

**Materials and Methods:** Between March 2004 and February 2017, a total of 30 athletes underwent peroneal tendon repair for a peroneal tendon tear. The indications of surgical treatment were chronic pain or intractable symptoms after a previous ankle sprain affecting sports activity refractory to conservative treatment for at least six months. The patient underwent tubulization for a longitudinal tendon rupture. Peroneus longus to peroneus brevis tenodesis was performed when tendon repair was impossible due to total rupture or multiple longitudinal rupture.

**Results:** Twenty patients not included in this study were as follows: insufficient follow-up, previous surgery, and additional bone surgery. All 10 patients had a previous ankle sprain history, tenderness and swelling on the retromalleolar area. In the 10 patient population, there were five peroneus brevis tendon tears, three peroneus longus tendon tears, one peroneus longus and brevis tendon tear, and one peroneus brevis and superior peroneal retinaculum tear. In the 10 patients, six cases of peroneal brevis tendon repair and four cases of peroneal longus to brevis tenodesis were performed. The preoperative American Orthopaedic Foot and Ankle Society score was improved from a mean of 60.6 (standard deviation [SD], 8.64) to a mean of 90.2, postoperatively (SD, 4.4;  $p < 0.012$ ). The preoperative visual analogue scale was improved from a mean of 5.43 (SD, 1.2) to 0.5 (SD, 0.16), postoperatively ( $p < 0.023$ ). The mean length of time to return to play was 12.2 weeks (range, 8~16 weeks).

**Conclusion:** Peroneal tendon tear can occur due to sports injuries. If there is tenderness at the retromalleolar area, the surgeon should consider a peroneal tendon lesion. Surgical repair of the peroneal tendon can be an effective treatment to help athletes to return to play.

**Key Words:** Tendon injuries, Sports, Athletes

## INTRODUCTION

Ankle sprain is by far the most frequently encountered injury in

Received June 28, 2019 Revised August 26, 2019 Accepted August 28, 2019

**Corresponding Author:** Hong Seop Lee

Department of Foot and Ankle Surgery, Eulji Medical Center, Eulji University, 68 Hangeulbiseok-ro, Nowon-gu, Seoul 01830, Korea

Tel: 82-2-970-8259, Fax: 82-2-973-3024, E-mail: sup4036@naver.com

ORCID: <https://orcid.org/0000-0002-3589-314X>

The point of this thesis was presented by 33th Spring Symposium of Korean Orthopaedic Society for Sports Medicine.

**Financial support:** None.

**Conflict of interest:** None.

athletes that greatly consumes practice time. In sports, plantar flexion and inversion injury of the foot and ankle joint is the common mechanism of injury. Most of the time, the anterior talofibular ligament is injured first, followed by the calcaneofibular ligament. As the injury becomes more severe, the posterior talofibular ligament eventually gets injured.<sup>1)</sup>

Ankle plantar flexion and inversion are the two most common mechanisms of injury of the peroneal tendons and their related structures.<sup>2)</sup> Due to the ambiguous nature of pain, especially in the lateral side of the ankle, peroneal tendon injuries are frequently unrecognized.<sup>3)</sup>

Copyright ©2019 Korean Foot and Ankle Society. All rights reserved.

© This is an Open Access article distributed under the terms of the Creative Commons Attribution Non-Commercial License (<http://creativecommons.org/licenses/by-nc/4.0>) which permits unrestricted non-commercial use, distribution, and reproduction in any medium, provided the original work is properly cited.

The main function of the peroneal tendon is the ankle eversion that contributes to lateral ankle stability. As a consequence, an overlooked peroneal tendon injury may interfere with sports and daily activities.

Peroneal tendon injury is related to various sports activities, such as ballet, running, skating, soccer, and tennis.<sup>4-6)</sup> The total recovery time required for athletes to return to games is important. However, there are few articles about the return to play of athletes after peroneal tendon repair.

We hypothesized that athletes could be able to return to play after peroneal tendon repair. This study aimed to analyze the clinical outcomes of and assess the average time to return to play following peroneal tendon repair in Korean athletes.

## MATERIALS AND METHODS

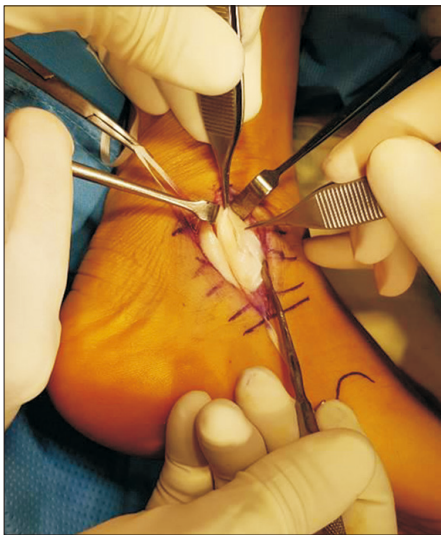
This study was approved by the Institutional Review Board of Eulji Medical Center (IRB No. 2019-04-013). Between March 2004 and February 2017, a total of 30 athletes underwent peroneal tendon tear repair. Their cases were retrospectively reviewed, and the need for informed consent was waived because of the study's retrospective nature. The study included professional- or amateur-level athletes in Korean society.

Operative treatment was indicated in athletes who suffered from chronic pain or ankle sprains that led to intractable symptoms affecting their sports activities. Intractable symptoms were considered those that remained refractory to conservative treatment such

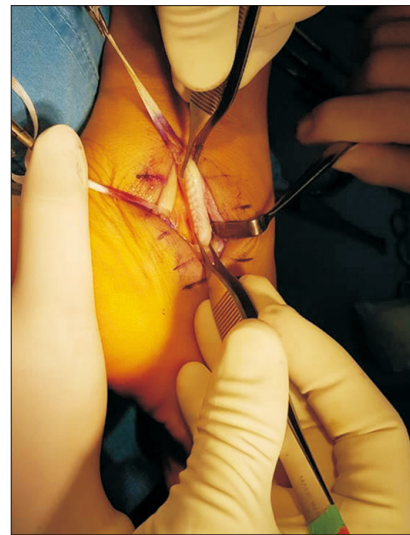
as physical therapy or peroneal strengthening exercise for at least 6 months. Preoperative ultrasonography or magnetic resonance imaging was used to diagnose peroneal tendon tears. Twenty patients (20 feet) not included in this study were: insufficient follow-up (<2 years, n=5), previous surgery (n=6), and additional bone surgery like bony realignment surgery or os subfibulare excision (n=9). A total of 10 patients were included in this study (four males, six females; average age, 24.3 years; range, 16~32 years). Five patients were amateur-level athletes, while 5 were professional-level athletes. They included soccer players (n=5), basketball players (n=3), and volleyball players (n=2). The average follow-up period was 9.2 years (range, 2~15 years).

### 1. Surgical procedure

Surgery was performed using spinal anesthesia or popliteal anesthesia after the placement of a cushion under the affected hip. Between the upper 2 cm to the lower 2 cm from the lateral malleolus tip, a curved incision was made along the retromalleolar area. First, tendon exploration was performed; if tenosynovitis was present, a synovectomy was performed (Fig. 1). Tubulization was performed for longitudinal tendon rupture (Fig. 2). Peroneus longus to peroneus brevis tenodesis was performed when tendon repair was impossible due to total rupture or multiple longitudinal rupture. Superior peroneal retinaculum (SPR) repair was performed when peroneal subluxation was noted intraoperatively. A modified Brostrom operation (MBO) was performed when chronic ankle instability was noted.<sup>7)</sup> Postoperatively, the ankles



**Figure 1.** In the operative field, a split tear and degenerative change of the peroneus brevis tendon are visible.



**Figure 2.** Debridement and tubulization of the peroneus brevis tendon were performed.

were immobilized with a short leg splint for 1 month and an air cast for additional 1 month. After a 4-week immobilization period, the patients were encouraged to actively move the joint as much as possible to increase range of motion and engage in tolerable weightbearing. After 6 weeks postoperatively, peroneal strengthening exercises and Achilles tendon stretching exercises were undertaken. Once swelling and pain was controlled, functional rehabilitation was started.<sup>8)</sup> The first stage of functional rehabilitation was balance exercise. Balance exercise was progress from squatting on triangle board to balance board/wobble board exercise. Once the athlete could perform these without a pain, the athlete moved on the the next stage (2nd stage, walking in a straight line; 3rd stage, jogging in a straight line). Once the athlete could perform 2nd stage and 3rd stage without a pain or a limp, jumps was added. Once the athlete could perform 10 jumps for distance on the involved limb as long as uninvolved limb, they moved on the last stage. The last stage was cutting. As the athletes became more functional, we encouraged the athlete to return to team training (Table 1).

## 2. Outcome measures

Clinical outcomes were analyzed by American Orthopaedic Foot

**Table 1.** This Table Shows the Schedule of Functional Rehabilitation

Stage	Rehabilitation schedule
1st	Balance exercise
2nd	Walking in a straight line
3rd	Jogging in a straight line
4th	Jump
5th	Cutting

**Table 2.** Clinical Data of the Patients

No.	Age (yr)	Sex	Sports	Activity	Diagnosis	Operation	Time to RTP (wk)
1	23	Female	Soccer	Ama.	PB tear	Repair	12
2	23	Female	Volleyball	Ama.	PB tear	Repair	8
3	29	Male	Soccer	Pro.	PL tear	Tenodesis	12
4	16	Male	Soccer	Ama.	PB tear	Repair	12
5	20	Female	Basketball	Ama.	PB tear	Repair	16
6	32	Female	Basketball	Pro.	PB tear	Repair	16
7	29	Male	Soccer	Pro.	PB,PL tear	Tenodesis	12
8	25	Female	Basketball	Pro.	PL tear	Tenodesis	12
9	26	Female	Volleyball	Pro.	PL tear	Tenodesis	12
10	22	Male	Soccer	Ama.	PB, SPR tear	Repair	12
Average	24.3						12.2

RTP: return to play, Ama.: amateur-level, Pro.: professional-level, PB: peroneus brevis tendon, PL: peroneus longus tendon, SPR: superior peroneal retinaculum.

and Ankle Society (AOFAS) ankle-hindfoot scores and visual analogue scale (VAS) scores pre- and postoperatively. We checked the postoperative complications in the chart review.

## 3. Statistical analyses

Continuous variables are shown as mean and standard deviation. The Wilcoxon signed-rank test (SPSS ver. 12.0; SPSS Inc., Chicago, IL, USA) was used to compare the pre- and postoperative AOFAS ankle-hindfoot scores and VAS scores.  $p < 0.05$  was considered statistically significant.

## RESULTS

All 10 patients had a history of previous ankle sprain and tenderness and swelling of the retromalleolar area. Of our 10 patients, there were 5 peroneus brevis tendon tears, 3 peroneus longus tendon tears, 1 peroneus longus and brevis tendon tear, and 1 peroneus brevis and SPR tear. We performed 6 peroneal brevis tendon repairs and 4 peroneal longus to brevis tenodesis repairs. Additional procedures included 1 SPR repair and 3 MBO. AOFAS score improved from a mean 60.6 (standard deviation [SD], 8.64) preoperatively to a mean 90.2 (SD, 4.4) postoperatively ( $p < 0.012$ ). VAS improved from a mean 5.43 (SD, 1.2) preoperatively to 0.5 (SD, 0.16) postoperatively ( $p < 0.023$ ). The mean length of time to a return to play was 12.2 weeks (range, 8~16 weeks) (Table 2).

## DISCUSSION

The primary finding of this study is that we should consider surgical repair of peroneal tendon for athletes with sustained retro-

malleolar area pain and a history of previous lateral ankle sprain. The 10 athletes included in this study were able to return to play after surgery.

The ligaments that are most frequently injured in ankle sprain include the anterior talofibular ligaments and the calcaneofibular ligaments.<sup>9)</sup> The surrounding soft tissues, bones, and other structures are also vulnerable to injury as the inversion stress is applied to the ankle during ankle sprain.<sup>10)</sup> The bony structures that may be injured include the lateral process of the talus, osteochondral lesion of the talus, base of the 5th metatarsus, proximal fibula, and calcaneal anterior process. The soft-tissue structures at risk are the anterior inferior tibiofibular ligament, posterior inferior tibiofibular ligament, posterior talofibular ligament, cervical ligament of the subtalar joint, peroneal longus and brevis tendons, superficial peroneal nerve, deltoid ligament, and SPR. Many authors have reported that peroneal tendon injuries are frequently overlooked.<sup>11,12)</sup> Misdiagnosis is the most common cause of treatment failure of lateral ankle sprains. Surgeons must consider the possibility of peroneal tendon tear when evaluate athletes suffer acute and chronic lateral ankle pain. After experiencing a plantar flexion-inversion ankle sprain, peroneal tendon rupture in a longitudinal pattern should be considered in patients suffering from persistent lateral ankle symptoms.

Rupture and dislocation of the peroneal tendons mostly occur after an acute traumatic event and commonly occur in young athletes who are exposed to sports trauma. On the other hand, tenosynovitis and partial tears often arise from mechanical stress in a repetitive fashion rather than a single traumatic event.<sup>13)</sup> Peroneal dislocation or subluxation occurs congenitally due to shallow fibular groove or weak peroneal retinaculum, but trauma causes 90% of cases of peroneal dislocation.<sup>14)</sup> The mechanism of trauma involves strong contraction of the peroneal tendon or dorsiflexion of the ankle in a hindfoot eversion position, which is known to be related to SPR rupture.

Initial treatment of peroneal tendon tear is a conservative treatment consisting of anti-inflammatory medications, brace, lateral lifting wedge, and rehabilitation exercise.<sup>15)</sup> Non-surgical treatment for peroneal tendon tear has a higher failure rate than tendinitis.<sup>15)</sup> Failure of non-operative treatment is an indication for surgical treatment. In this study, we performed the surgical repair in the athletes did not respond the non-surgical treatment for at least 6 months. Current surgical options for peroneal tendon tears consist of debridement of degenerative portion of the tendon followed by primary repair, tenodesis to the normal peroneal tendon,

tendon transfer of the flexor digitorum longus or flexor hallucis longus.<sup>15-18)</sup> Krause and Brodsky<sup>17)</sup> recommended tenodesis rather than tendon repair when peroneus brevis tendon was degenerative greater than 50%. In the present study, we performed peroneus longus to peroneus brevis tenodesis when tendon repair was impossible due to total rupture or multiple longitudinal rupture.

To be our knowledge, the report of return to sports after peroneal tendon repair is rare. Demetracopoulos et al.<sup>19)</sup> obtained excellent results by debridement and primary repair of peroneal tendon tears. In their study, 94% (17 of 18) of the patients returned to full sports activity without limitation. The author reported that the main reason for the excellent results to sports return was their exclusion criteria of patients with severe, degenerative tears not suitable to debride and repair primarily. The other study reported that only 46% (12 of 26) could return to sports after operative treatment of peroneal tendon tears.<sup>20)</sup> Patient's old age (average 53 years) had a negative effect on the return to sports after operative treatment. We observed all 10 athletes were able to return to sports. We believe the main reason for the excellent results of return to sports was our cohort of patients was young active athlete.

Peroneal brevis tendon tears occur more frequently than peroneus longus tendon tears. The reason for this is that the peroneus brevis tendon is located in the posterior aspect of the fibula between the peroneus longus tendon and the peroneus brevis tendon and passes over the end of the fibula at an acute angle.<sup>21)</sup> In this study, peroneus brevis tendon tears occurred most frequently, suggesting that we should examine peroneus brevis tendon tears more carefully.

This study has several limitations. The primary limitation is its retrospective design. Data were collected from the patients, which could lead to recall bias. This study included insufficient numbers of patients to confirm the conclusion of peroneal tendon tear treatment for athletes. Another limitation is that various sports with varying influences on ankle injuries were involved, which made it difficult to pinpoint which sports activities are more susceptible to peroneal tendon injuries. However, the diverse sports activities included in the study helped provide general treatment guidelines.

## CONCLUSION

Peroneal tendon tears may occur due to sports injuries. If there is tenderness in the retromalleolar area, the surgeon should consider the possibility of a peroneal tendon lesion. Surgical repair of the peroneal tendon can be an effective treatment that enables

athletes to return to sports.

## REFERENCES

1. Anderson KJ, Lecocq JF. Operative treatment of injury to the fibular collateral ligament of the ankle. *J Bone Joint Surg Am.* 1954;36:825-32.
2. Burman M. Stenosing tendovaginitis of the foot and ankle; studies with special reference to the stenosing tendovaginitis of the peroneal tendons of the peroneal tubercle. *AMA Arch Surg.* 1953;67:686-98.
3. Dombek MF, Lamm BM, Saltrick K, Mendicino RW, Catanzariti AR. Peroneal tendon tears: a retrospective review. *J Foot Ankle Surg.* 2003;42:250-8.
4. Ferran NA, Oliva F, Maffulli N. Recurrent subluxation of the peroneal tendons. *Sports Med.* 2006;36:839-46. doi: 10.2165/00007256-200636100-00003.
5. Larsen E. Longitudinal rupture of the peroneus brevis tendon. *J Bone Joint Surg Br.* 1987;69:340-1.
6. Wind WM, Rohrbacher BJ. Peroneus longus and brevis rupture in a collegiate athlete. *Foot Ankle Int.* 2001;22:140-3.
7. Lee KT, Park YU, Kim JS, Kim JB, Kim KC, Kang SK. Long-term results after modified Brostrom procedure without calcaneofibular ligament reconstruction. *Foot Ankle Int.* 2011;32:153-7. doi: 10.3113/FAI.2011.0153.
8. Chinn L, Hertel J. Rehabilitation of ankle and foot injuries in athletes. *Clin Sports Med.* 2010;29:157-67. doi: 10.1016/j.csm.2009.09.006.
9. DiGiovanni BF, Fraga CJ, Cohen BE, Shereff MJ. Associated injuries found in chronic lateral ankle instability. *Foot Ankle Int.* 2000;21:809-15. doi: 10.1177/107110070002101003.
10. Young KW, Park YU, Kim JS, Cho HK, Choo HS, Park JH. Misdiagnosis of talar body or neck fractures as ankle sprains in low energy traumas. *Clin Orthop Surg.* 2016;8:303-9. doi: 10.4055/cios.2016.8.3.303.
11. Sammarco GJ. Peroneus longus tendon tears: acute and chronic. *Foot Ankle Int.* 1995;16:245-53. doi: 10.1177/107110079501600501.
12. Clarke HD, Kitaoka HB, Ehman RL. Peroneal tendon injuries. *Foot Ankle Int.* 1998;19:280-8. doi: 10.1177/107110079801900503.
13. Karlsson J, Wiger P. Longitudinal split of the peroneus brevis tendon and lateral ankle instability: treatment of concomitant lesions. *J Athl Train.* 2002;37:463-6.
14. Stover CN, Bryan DR. Traumatic dislocation of the peroneal tendons. *Am J Surg.* 1962;103:180-6.
15. Squires N, Myerson MS, Gamba C. Surgical treatment of peroneal tendon tears. *Foot Ankle Clin.* 2007;12:675-95. doi: 10.1016/j.fcl.2007.08.002.
16. Redfern D, Myerson M. The management of concomitant tears of the peroneus longus and brevis tendons. *Foot Ankle Int.* 2004;25:695-707. doi: 10.1177/107110070402501002.
17. Krause JO, Brodsky JW. Peroneus brevis tendon tears: pathophysiology, surgical reconstruction, and clinical results. *Foot Ankle Int.* 1998;19:271-9. doi: 10.1177/107110079801900502.
18. Heckman DS, Reddy S, Pedowitz D, Wapner KL, Parekh SG. Operative treatment for peroneal tendon disorders. *J Bone Joint Surg Am.* 2008;90:404-18. doi: 10.2106/JBJS.G.00965.
19. Demetracopoulos CA, Vineyard JC, Kiesau CD, Nunley JA 2nd. Long-term results of debridement and primary repair of peroneal tendon tears. *Foot Ankle Int.* 2014;35:252-7. doi: 10.1177/1071100713514565.
20. Steel MW, DeOrio JK. Peroneal tendon tears: return to sports after operative treatment. *Foot Ankle Int.* 2007;28:49-54. doi: 10.3113/FAI.2007.0009.
21. Alanen J, Orava S, Heinonen OJ, Ikonen J, Kvist M. Peroneal tendon injuries. Report of thirty-eight operated cases. *Ann Chir Gynaecol.* 2001;90:43-6.