

Review Article



OPEN ACCESS

Received: Jan 5, 2019

Revised: Mar 14, 2019

Accepted: May 1, 2019

Correspondence to

Arnulf Heinrich Hoelscher

Center of Esophageal and Gastric Surgery,
Agaplesion Markus Hospital, Wilhelm-Epstein-
Straße 4, 60431 Frankfurt, Germany.
E-mail: Arnulf.Hoelscher@fdk.info

Copyright © 2019. Korean Gastric Cancer
Association

This is an Open Access article distributed
under the terms of the Creative Commons
Attribution Non-Commercial License ([https://
creativecommons.org/licenses/by-nc/4.0](https://creativecommons.org/licenses/by-nc/4.0))
which permits unrestricted noncommercial
use, distribution, and reproduction in any
medium, provided the original work is properly
cited.

ORCID iDs

Felix Berth

<https://orcid.org/0000-0002-3780-0728>

Arnulf Heinrich Hoelscher

<https://orcid.org/0000-0002-8207-3865>

Funding

Felix Berth is supported by the German
Research Foundation (“DFG”).

Author Contributions

Conceptualization: B.F., H.A.H.; Methodology:
B.F., H.A.H.; Project administration: B.F.,
H.A.H.; Writing - original draft: B.F., H.A.H.;
Writing - review & editing: B.F., H.A.H.

Conflict of Interest

No potential conflict of interest relevant to this
article was reported.

<https://jgc-online.org>

History of Esophagogastric Junction Cancer Treatment and Current Surgical Management in Western Countries

Felix Berth ¹, Arnulf Heinrich Hoelscher ²

¹Department of Surgery, Division of Gastrointestinal Surgery, Seoul National University Hospital, Seoul, Korea

²Center of Esophageal and Gastric Surgery, Agaplesion Markus Hospital, Frankfurt, Germany

ABSTRACT

The incidence of esophagogastric junction (EGJ) cancer has been significantly increasing in Western countries. Appropriate planning for surgical therapy requires a reliable classification of EGJ cancers with respect to their exact location. Clinically, the most accepted classification of EGJ cancers is “adenocarcinoma of the EGJ” (AEG or “Siewert”), which divides tumor center localization into AEG type I (distal esophagus), AEG type II (“true junction”), and AEG type III (subcardial stomach). Treatment strategies in western countries routinely employ perioperative chemotherapy or neoadjuvant chemoradiation for cases of locally advanced cancers. The standard surgical treatment strategies are esophagectomy for AEG type I and gastrectomy for AEG type III cancers. For “true junctional cancers,” i.e., AEG type II, whether the extension of resection in the oral or aboral direction represents the most effective surgical therapy remains debatable. This article reviews the history of surgical EGJ cancer treatment and current surgical strategies from a Western perspective.

Keywords: Surgery; Treatment

INTRODUCTION

Esophagogastric junction (EGJ) cancer, especially adenocarcinoma of the EGJ (AEG), represents a solid tumor entity with a rapidly increasing incidence in Western countries during recent decades [1,2]. Being anatomically associated with esophageal cancer and gastric cancer, EGJ cancers, which are predominantly considered to be adenocarcinomas, are increasingly being considered as a distinct tumor entity. They have a constellation of risk factors that are distinct from those for esophageal and gastric cancers, with a certain genetic configuration and principally tailored therapeutic approaches. In Western countries, where the highest incidence of EGJ cancer is found, a limited level of centralization leads to difficulties in recruitment for prospective studies. In Asian countries, especially in Korea and Japan, the incidence of EGJ cancer is not high compared with gastric cancer, for which a large number of clinical trials have been performed, and the surgical treatment is highly standardized.

Based on evidence gained in recent decades in Western countries, both optimal surgical and medical strategies are under discussion. Regarding the surgical approach, gastrectomy or esophagectomy, both with standardized lymph node dissection, are technically feasible methods for treating AEG type II. Thus far, most national or European guidelines and recommendations do not strongly favor any one approach when specifically addressing this true junctional adenocarcinoma.

HISTORY OF GASTRIC AND ESOPHAGOGASTRIC SURGERY IN WESTERN COUNTRIES

In Western countries, Theodor Billroth has been recognized as the pioneer of upper gastrointestinal cancer surgery. He was the first to successfully perform a partial gastrectomy in a patient with cancer in 1881. His name is globally connected to the reconstruction methods used after distal gastrectomy, the gastroduodenostomy (Billroth I) and gastrojejunostomy (Billroth II). In Germany, Billroth is also known as the founder of the German Society of Surgery. Historically, surgery of the stomach has long been the predominant discipline in upper gastrointestinal cancer surgery, not only because of the challenges of thoracotomy in terms of anesthesia and ventilation during its beginnings, but also due to the high incidence of gastric cancer. Several Western national and international registers precisely show the rapidly decreasing incidence of gastric cancer starting from the 1960s. Lately the decrease of incidence slowed down [3]. At the same time, however, the incidence of proximal gastric cancer and adenocarcinoma of the esophagus has been increasing, drawing attention to this anatomically challenging area. The surgical approaches for advanced cancer of the EGJ in the 20th century routinely included esophagogastrectomy. Unsatisfactory outcomes not only for the cancer but also for the surgical approach showed the need for a more effective surgery driven by objective parameters, which have now been provided with a classification. The classification of EGJ cancer was developed in an attempt to help with clinical decision making, to choose in which cases a gastrectomy and in which cases an esophagectomy would represent the most effective surgical treatment. Western evidence for this clinical challenge was mainly provided by Siewert et al. [4,5], who recognized the need for surgical standardization and a reduction in surgical morbidity regarding this increasing tumor entity.

CLASSIFICATION OF EGJ CANCER

The most commonly used classification system for cancers of the EGJ in Western countries is the AEG classification, which was introduced in Germany in 1987 by Siewert et al. [4,5] and was published in 1998. This classification aimed to clinically evaluate the exact location and extent of the cancer to provide for standardized decision making with respect to the surgical approach (**Fig. 1**). AEG type I represents a tumor centered in projection on the distal esophagus within 1–5 cm orally of the anatomical cardia. AEG type III cancer infiltrates the junction from below, and the tumor center is located within 2–5 cm aborally from the anatomical cardia. In AEG type II cancer, sometimes described as “true junctional cancer,” the epicenter of the tumor is located in projection to the anatomical cardia (+1 cm to -2 cm). Even before evidence was found in clinical trials, esophagectomy was suggested as an appropriate approach for AEG type I, and gastrectomy was suggested for AEG type III [4]. These approaches contribute not only to the technical feasibility for an R0 resection but also to an appropriate lymph node dissection in the mediastinum or abdomen.

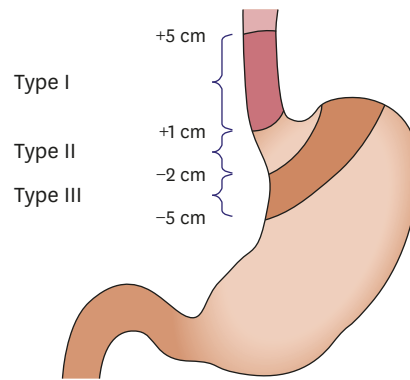


Fig. 1. Adenocarcinoma of the esophagogastric junction-classification (figure taken from Siewert et al. [4]).

Hence, the optimal surgical approach for AEG type II cancer, in which a gastrectomy as well as an esophagectomy is technically possible in many cases, has been under discussion. Evidence can only be gained from retrospective studies, in which the classification system used must be carefully reviewed. The Japanese classification of gastric carcinoma offers a classification associated with the AEG classification (Fig. 2, Nishi's classification); both classifications might be applicable for clinical decision making. In the Japanese classification, however, the description of the junction area for gastric carcinoma also includes pathological findings when referring to the border between the esophageal and gastric muscles, and defines EGJ cancer as within 2 cm distal or proximal to the junction [6]. It is important to differentiate between a pathological and a clinical classification of the junction and EGJ cancer, given that any pathological classification is a major change of principle from "a priori" (preoperative) decision making to "a posteriori" (postoperative) with respect to the surgical procedure. Clinically, the authors of the Japanese classification of gastric carcinoma suggest referring to landmarks such as the horizontal vessels of the esophagus, the caliber change of the esophagus and stomach, the angle of His and the gastric longitudinal folds. The squamocolumnar junction (Z-line) is not meant to be identical to the EGJ after the Japanese classification. The Japanese treatment guidelines, however, refer to the predominant location of the tumor, whether it is in the stomach (G) or esophagus (E), resulting in a description as G, E, GE, EG, or E=G [7] (Fig. 3).

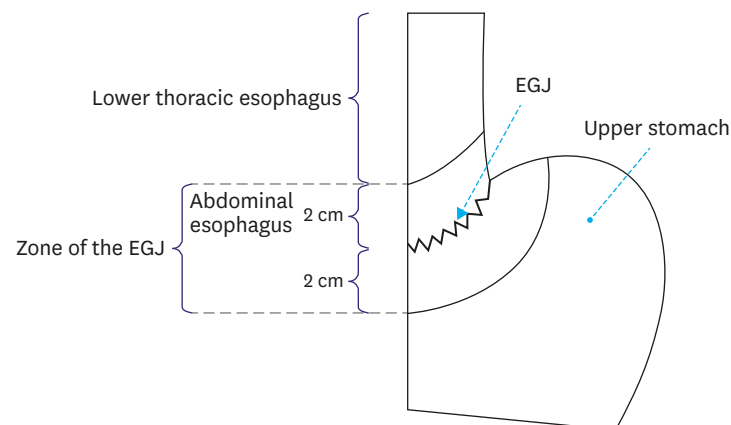


Fig. 2. Nishi's classification (figure taken from: the Japan Esophageal Society [28], the figure is based on the "Nishi's classification": Nishi M, Kajisa T, Aiko T, Kaneko Y, Kawaji T. The proposal of the gastric cardia. *Gekarinshou* 1973;15:1328-1338). EGJ = esophagogastric junction.

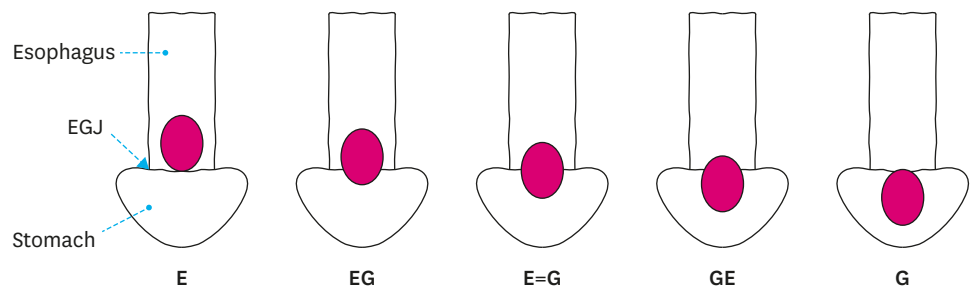


Fig. 3. Japanese scheme of junctional cancer (figure taken from the Japan Esophageal Society [28]). EGJ = esophagogastric junction.

Outcome comparisons between cohorts using different classification systems appear inappropriate, given that the extent of the tumor and the infiltration length of the esophagus or stomach are believed to be strongly correlated with the location of the lymph node metastasis and, consequently, to the rationale of choosing the optimal surgical approach. The determination of exact tumor location and its extent as well the configuration of the patient in respect of length of esophagus and the presence of hiatal hernia would influence the surgical approach in this challenging anatomical area. In Western countries, the AEG classification is widely accepted to support the clinical decision making.

SURGICAL THERAPY

When deciding on the surgical approach for EGJ cancers, most surgeons in Western countries rely on the AEG classification. However, the evidence for the chosen procedures is not derived from clinical trials dealing with 1 of the 3 types of junctional cancers exclusively. The first landmark trial that is still used to justify the esophagectomy approach in AEG type I cancers is the Dutch trial published in 2002, which compared outcomes for transhiatal and transthoracic esophagectomy for patients with cancers of the “mid-to distal esophagus or of the cardia involving the distal esophagus” [8]. In total, 220 patients were randomly assigned to one of the surgical approaches; although the overall and disease-specific survival did not differ significantly after 5 years, a trend was observed toward better outcomes with the transthoracic approach. The inclusion of the tumor location in this trial led to a more frequent performance of transthoracic esophagectomy in patients with AEG type I cancers. After becoming the standard surgical approach, efforts were made to develop safety strategies to prevent high morbidity after this radical 2-cavity procedure. Thus, the randomized controlled French multicentre randomised controlled phase III trial was able to show benefits for the hybrid esophagectomy (laparoscopic gastric mobilization and open transthoracic esophagectomy) over the open approach in terms of morbidity, without compromising 3-year outcomes [9]. These results confirmed hybrid esophagectomy as the standard approach in Western centers. Recent small retrospective studies have suggested benefits for patients undergoing total minimally invasive esophagectomy over hybrid esophagectomy for pulmonary and pain outcomes; however, these results have not yet been prospectively confirmed [10,11]. Large Western national (Dutch) and international cohorts evaluating the short-term outcome for hybrid and total minimal invasive esophagectomy have indicated that the total minimally invasive approach might still be associated with a higher rate of anastomotic leaks [12-14]. The numbers for anastomotic leaks vary from 11.4% to 15.6% in open procedures and from 15.9% to 21.2% in the minimally invasive

approach in those large data collections. High intrathoracic as well as neck anastomosis after esophagectomy and reconstruction with gastric conduit are both performed in Western countries dependent on the center's preference. The randomized controlled Dutch traditional invasive vs. minimally invasive esophagectomy (TIME) trial demonstrated lower postoperative morbidity for total minimally invasive esophagectomy (with neck anastomosis) compared with open surgery (with intrathoracic anastomosis). Even though the TIME trial included AEG type I cancers, there have been no surgical trials exclusively dealing with junctional cancers. However, given that a 2-field lymphadenectomy is also performed in esophagectomy for distal esophageal cancer, the results in respect to short-term operative outcomes are of interest. In Asia, the benefits of minimally invasive esophagectomy are also under investigation, as shown by the Japanese Clinical Oncology Group (JCOG) 1,409 trial comparing thoracoscopic and open esophagectomy for stage I–III esophageal cancer.

In most cases, AEG type III cancer is surgically treated as gastric cancer in Western countries, which means that total gastrectomy is performed. As for the lower incidence of gastric cancers in Western countries, some evidence regarding gastrectomy has been taken from Eastern studies. For AEG type III cancers, the Japanese JCOG trial comparing the left thoracoabdominal approach with the abdominal transhiatal approach for cancers of the cardia and subcardia published in 2006 by Sasako et al. [15] has demonstrated strong evidence in favor of the abdominal transhiatal approach. This study was aborted after interim analysis due to lower survival and higher morbidity using the left thoracoabdominal approach. Before this study was conducted, when they were introducing the AEG-classification, the approach suggested by Siewert et al. [4] for treating AEG type III was transhiatal extended gastrectomy. As to the obvious technical aspect, gastrectomy is not under intense discussion for AEG type III cancers in Western countries. The proximal margin, the esophagus, is usually not infiltrated by tumor in AEG type III cancer, which provides good opportunities for R0 resection by total gastrectomy. Furthermore, subcardial tumors can frequently spread along the lesser curvature in direction of the angle of his; thus, safe distal resection margins might also be more comfortably achieved by gastrectomy rather than by esophagectomy (including resection of the lesser curvature and proximal stomach). The role of mediastinal lymph node dissection in AEG type III cancer, especially of the lower mediastinum, is indeed a matter of discussion. Given that advanced cancers are mostly diagnosed in Western countries, a transhiatal extension of the gastrectomy appears reasonable. Initially, a cohort of 166 patients with AEG type III cancer, published by Siewert et al., [16] had been reported as having a (mediastinal) paraesophageal lymph node metastasis rate of 9%. Therefore, the authors suggested a lymph node dissection of the lower mediastinum for AEG type III cancers, which subsequently became the standard. The cohort was recruited mostly from advanced cases, and limited resection options for early cancers were discussed, but Western evidence is lacking. In cases of advanced tumor stage, an open approach is typically used in Western countries for transhiatal extended gastrectomy. However, driven by advances in laparoscopic gastric cancer surgery in Korea and Japan [17,18], techniques have been suggested for feasible laparoscopic lower mediastinal lymph node dissection, even for advanced cases [19]. Until now, no Western study has compared an open and a laparoscopic or robotic transhiatal extended gastrectomy approach for EGJ cancer.

The most discussed type of EGJ cancer in terms of surgery is AEG type II cancer or “true junctional cancer”. Both surgical landmark trials named above addressed AEG type II cancers in their inclusion criteria. Technically, “true junctional cancers” can be resected by gastrectomy with transhiatal extension and distal esophageal resection or by esophagectomy with combined

resection of the cardia and proximal stomach. In terms of abdominal lymph node dissection, gastrectomy represents a more radical approach, and in terms of mediastinal lymph node dissection, transthoracic esophagectomy offers higher radicality. As for the high proportion of advanced cancers, cardia resection and reconstruction with small bowel interposition (Merendino) or cardia reconstruction with flap techniques do not play a significant role in Western countries. Several Western studies have presented numbers and proportions of infiltrated mediastinal lymph nodes in AEG type II cancers. The largest cohort of Rüdiger Siewert et al., [20] with more than 1,000 patients with EGJ cancer, presented a lower mediastinal lymph node metastasis rate of 15.6%, and even 16.1% at the greater curvature. Based on these data, a transhiatal extended gastrectomy has been suggested for AEG type II; however, it must be mentioned that middle and upper mediastinal lymph node dissection has not been commonly performed for patients in this cohort and the rate of positive lymph nodes in this location is therefore unknown. Lerut et al. [21] noted a significant rate of lymph node metastases in the neck and the cervicothoracic junction region (17.6%) in patients with 3-field lymphadenectomy (abdominal, thoracic, and cervical). In this study, the tumor site is only categorized as “GEJ”, which most likely contributes to AEG type II in this context. The patient number is limited, but it is still recognized that upper mediastinal and even neck lymph node metastasis can frequently occur in EGJ cancer. A recent Asian study that has affected this discussion in Western countries is the 2017 published data on lymph node metastasis on patients with EGJ cancer, including those with squamous cell carcinoma, initiated by the Japanese Gastric Cancer Association and the Japanese Esophageal Society. This study included 2,807 patients with EGJ cancer and calculated the lymph node metastatic risk for each lymph node station and region. The study included only tumors with a diameter smaller than 4 cm; however, a middle and upper mediastinal lymph node dissection was performed in only a minority of those cases. Data show that for pT2 cancers, and even esophagus-predominant adenocarcinoma (n=237), the most frequently infiltrated lymph node station in the lower mediastinum is No. 110 (paraesophageal lymph nodes in the lower thorax), with only 5.1%. The same group of patients showed a lymph node metastasis rate at the lesser curvature (No. 1 and 3) of 34.6% and 28.7%, respectively [22]. These data reflect the probability of mediastinal lymph node metastasis as possibly more associated with advanced disease status than with overall lymph node status. It might also explain the different treatment strategies for EGJ cancers in Western countries compared with those in Korea and Japan, where a high proportion of early cancers are diagnosed due to screening programs.

To gain more evidence for patient survival, a clinical trial for patients with AEG type II cancer randomized to esophagectomy with cardia and proximal stomach resection or to gastrectomy with transhiatal extension is planned in Germany; it is expected to start recruiting in 2019. This trial, defining overall survival as the primary endpoint, aims to answer the question of the oncological accuracy of both approaches. However, including enough patients to compare subgroups of defined tumor location and the comparable extent of lymphadenectomy, surgical quality, T-category, type of neoadjuvant treatment and functional performance is difficult. The most important outcome parameters in future studies should also focus on functional outcomes and quality of life measurements when comparing these surgical approaches.

Regardless of the exact tumor location, recent studies have focused on the evaluation of surgical benefits for patients with limited metastatic status. The Randomized Etanercept North American Strategy to Study Antagonism of Cytokine (AIO-FLOT5) trial is currently recruiting randomized patients with limited metastatic status to chemotherapy alone versus surgery, embedded into a perioperative chemotherapy concept [23].

With respect to the surgical radicality for each approach, German guidelines recommend D2 lymph node dissection plus lower mediastinal lymph node dissection when gastrectomy is applied in EGJ cancers and a 2-field lymphadenectomy for the esophagectomy approach, in which a partial D1 and D2 (abdominal) lymphadenectomy and a lower and middle mediastinal (thoracic) lymphadenectomy is routinely included [24].

SUMMARY AND FUTURE PERSPECTIVES

Current surgical management of EGJ cancer in Western countries is based on Siewert's AEG classification. Transthoracic esophagectomy with proximal gastric resection and reconstruction with gastric pull-up is the treatment of choice for AEG type I, and transhiatal extended gastrectomy with distal esophageal resection and reconstruction by Roux-en-Y esophagojejunostomy is favored for AEG type III. With respect to the surgical approach for EGJ cancers, the primary question is the best treatment approach for AEG type II cancers. Addressing this question, a trial randomizing those patients to either gastrectomy with transhiatal lower mediastinal lymph node dissection or to transthoracic esophagectomy is currently planned and will possibly begin in 2019. It will also be important to implement higher surgical (and pathological) standards in the clinical trials evaluating nonsurgical agents. Even the landmark trials do not meet all the surgical requirements accepted as recommended standard guidelines in Western countries. The Medical Research Council Adjuvant Gastric Infusional Chemotherapy trial, although dealing with more than 70% gastric cancer in only clinically advanced stages, had a D2-lymph node dissection rate of 41.4% among all cases in which surgery was performed (n=457) [25]. In the ACCORD-07 trial, a median number of only 19 lymph nodes were examined; and in the CROSS trial, the anastomotic leakage rate was 26.1% among all patients who underwent resection (n=322) [26,27]. The effect of these studies can be boosted by implementing the highest possible standards of surgery and pathological examination of the specimen so that accurate radicality of surgery is provided, a precise pathological staging is performed, and the lowest possible proportions of patients need to discontinue postsurgical treatments due to complications or low performance.

CONCLUSIONS

Cancers of the EGJ are surgically challenging as different approaches and different classifications are used. In Western Countries the AEG classification is the commonly used clinical classification to support the decision making for the surgical procedure. Thus, EGJ cancers directly located in the junction (AEG type II) are still controversially discussed in regard of the optimal surgical approach. As the incidence of this specific tumor entity is rising, there is a future need of world-wide cooperation considering the classification and surgical therapy of EGJ cancers.

REFERENCES

1. Global Burden of Disease Cancer Collaboration, Fitzmaurice C, Dicker D, Pain A, Hamavid H, Moradi-Lakeh M, et al. The global burden of cancer 2013. *JAMA Oncol* 2015;1:505-527.

[PUBMED](#) | [CROSSREF](#)

2. Buas MF, Vaughan TL. Epidemiology and risk factors for gastroesophageal junction tumors: understanding the rising incidence of this disease. *Semin Radiat Oncol* 2013;23:3-9.
[PUBMED](#) | [CROSSREF](#)
3. Sonnenberg A. Time trends of mortality from gastric cancer in Europe. *Dig Dis Sci* 2011;56:1112-1118.
[PUBMED](#) | [CROSSREF](#)
4. Siewert JR, Hölscher AH, Becker K, Gössner W. Cardia cancer: attempt at a therapeutically relevant classification. *Chirurg* 1987;58:25-32.
[PUBMED](#)
5. Siewert JR, Stein HJ. Classification of adenocarcinoma of the oesophagogastric junction. *Br J Surg* 1998;85:1457-1459.
[PUBMED](#) | [CROSSREF](#)
6. Japanese Gastric Cancer Association. Japanese classification of gastric carcinoma: 3rd English edition. *Gastric Cancer* 2011;14:101-112.
[PUBMED](#) | [CROSSREF](#)
7. Japanese Gastric Cancer Association. Japanese gastric cancer treatment guidelines 2014 (ver. 4). *Gastric Cancer* 2017;20:1-19.
[PUBMED](#) | [CROSSREF](#)
8. Hulscher JB, van Sandick JW, de Boer AG, Wijnhoven BP, Tijssen JG, Fockens P, et al. Extended transthoracic resection compared with limited transhiatal resection for adenocarcinoma of the esophagus. *N Engl J Med* 2002;347:1662-1669.
[PUBMED](#) | [CROSSREF](#)
9. Briez N, Piessen G, Torres F, Lebuffe G, Triboulet JP, Mariette C. Effects of hybrid minimally invasive oesophagectomy on major postoperative pulmonary complications. *Br J Surg* 2012;99:1547-1553.
[PUBMED](#) | [CROSSREF](#)
10. Berlth F, Plum PS, Chon SH, Gutschow CA, Bollschweiler E, Hölscher AH. Total minimally invasive esophagectomy for esophageal adenocarcinoma reduces postoperative pain and pneumonia compared to hybrid esophagectomy. *Surg Endosc* 2018;32:4957-4965.
[PUBMED](#) | [CROSSREF](#)
11. Bonavina L, Scolari F, Aiolfi A, Bonitta G, Sironi A, Saino G, et al. Early outcome of thoracoscopic and hybrid esophagectomy: propensity-matched comparative analysis. *Surgery* 2016;159:1073-1081.
[PUBMED](#) | [CROSSREF](#)
12. Schmidt HM, Gisbertz SS, Moons J, Rouvelas I, Kauppi J, Brown A, et al. Defining benchmarks for transthoracic esophagectomy: a multicenter analysis of total minimally invasive esophagectomy in low risk patients. *Ann Surg* 2017;266:814-821.
[PUBMED](#) | [CROSSREF](#)
13. Low DE, Kuppusamy MK, Alderson D, Ceconello I, Chang AC, Darling G, et al. Benchmarking complications associated with esophagectomy. *Ann Surg* 2019;269:291-298.
[PUBMED](#) | [CROSSREF](#)
14. Seesing MF, Gisbertz SS, Goense L, van Hillegersberg R, Kroon HM, Lagarde SM, et al. A propensity score matched analysis of open versus minimally invasive transthoracic esophagectomy in the Netherlands. *Ann Surg* 2017;266:839-846.
[PUBMED](#) | [CROSSREF](#)
15. Sasako M, Sano T, Yamamoto S, Sairenji M, Arai K, Kinoshita T, et al. Left thoracoabdominal approach versus abdominal-transhiatal approach for gastric cancer of the cardia or subcardia: a randomised controlled trial. *Lancet Oncol* 2006;7:644-651.
[PUBMED](#) | [CROSSREF](#)
16. Siewert JR, Stein HJ. Carcinoma of the cardia: carcinoma of the gastroesophageal junction - classification, pathology and extent of resection. *Dis Esophagus* 1996;9:173-182.
17. Kim HH, Han SU, Kim MC, Kim W, Lee HJ, Ryu SW, et al. Effect of laparoscopic distal gastrectomy vs open distal gastrectomy on long-term survival among patients with stage I gastric cancer: the KLASS-01 randomized clinical trial. *JAMA Oncol* 2019;5:506-513.
[PUBMED](#) | [CROSSREF](#)
18. Katai H, Mizusawa J, Katayama H, Takagi M, Yoshikawa T, Fukagawa T, et al. Short-term surgical outcomes from a phase III study of laparoscopy-assisted versus open distal gastrectomy with nodal dissection for clinical stage IA/IB gastric cancer: Japan Clinical Oncology Group Study JCOG0912. *Gastric Cancer* 2017;20:699-708.
[PUBMED](#) | [CROSSREF](#)
19. Takiguchi S, Miyazaki Y, Shinno N, Makino T, Takahashi T, Kurokawa Y, et al. Laparoscopic mediastinal dissection via an open left diaphragm approach for advanced Siewert type II adenocarcinoma. *Surg Today* 2016;46:129-134.
[PUBMED](#) | [CROSSREF](#)

20. Rüdiger Siewert J, Feith M, Werner M, Stein HJ. Adenocarcinoma of the esophagogastric junction: results of surgical therapy based on anatomical/topographic classification in 1,002 consecutive patients. *Ann Surg* 2000;232:353-361.
[PUBMED](#) | [CROSSREF](#)
21. Lerut T, Nafteux P, Moons J, Coosemans W, Decker G, De Leyn P, et al. Three-field lymphadenectomy for carcinoma of the esophagus and gastroesophageal junction in 174 R0 resections: impact on staging, disease-free survival, and outcome: a plea for adaptation of TNM classification in upper-half esophageal carcinoma. *Ann Surg* 2004;240:962-972.
[PUBMED](#) | [CROSSREF](#)
22. Yamashita H, Seto Y, Sano T, Makuuchi H, Ando N, Sasako M, et al. Results of a nation-wide retrospective study of lymphadenectomy for esophagogastric junction carcinoma. *Gastric Cancer* 2017;20:69-83.
[PUBMED](#) | [CROSSREF](#)
23. Al-Batran SE, Goetze TO, Mueller DW, Vogel A, Winkler M, Lorenzen S, et al. The RENAISSANCE (AIO-FLOT5) trial: effect of chemotherapy alone vs. chemotherapy followed by surgical resection on survival and quality of life in patients with limited-metastatic adenocarcinoma of the stomach or esophagogastric junction - a phase III trial of the German AIO/CAO-V/CAOGI. *BMC Cancer* 2017;17:893.
[PUBMED](#) | [CROSSREF](#)
24. Moehler M, Al-Batran SE, Andus T, Anthuber M, Arends J, Arnold D, et al. German S3-guideline "diagnosis and treatment of esophagogastric cancer". *Z Gastroenterol* 2011;49:461-531.
[PUBMED](#) | [CROSSREF](#)
25. Cunningham D, Allum WH, Stenning SP, Thompson JN, Van de Velde CJ, Nicolson M, et al. Perioperative chemotherapy versus surgery alone for resectable gastroesophageal cancer. *N Engl J Med* 2006;355:11-20.
[PUBMED](#) | [CROSSREF](#)
26. Ychou M, Boige V, Pignon JP, Conroy T, Bouché O, Lebreton G, et al. Perioperative chemotherapy compared with surgery alone for resectable gastroesophageal adenocarcinoma: an FNCLCC and FFCD multicenter phase III trial. *J Clin Oncol* 2011;29:1715-1721.
[PUBMED](#) | [CROSSREF](#)
27. van Hagen P, Hulshof MC, van Lanschot JJ, Steyerberg EW, van Berge Henegouwen MI, Wijnhoven BP, et al. Preoperative chemoradiotherapy for esophageal or junctional cancer. *N Engl J Med* 2012;366:2074-2084.
[PUBMED](#) | [CROSSREF](#)
28. Japan Esophageal Society Japanese classification of esophageal cancer, 11th edition: part II and III. *Esophagus*. 2017;14:37-65.
[PUBMED](#) | [CROSSREF](#)