

# Effective method for reconstruction of remaining lower lip vermilion defect after a mental V-Y advancement flap

Joo-Hak Kim<sup>1</sup>,  
Chang Hwan Ahn<sup>1</sup>,  
Sunje Kim<sup>1</sup>,  
Won Suk Lee<sup>2</sup>,  
Sang-Ha Oh<sup>1,3</sup>

<sup>1</sup>Department of Plastic and Reconstructive Surgery, School of Medicine, Chungnam National University, Daejeon; <sup>2</sup>Department of Emergency Medicine, Eulji University College of Medicine, Daejeon; <sup>3</sup>Brain Research Institute, School of Medicine, Chungnam National University, Daejeon, Korea

**Background:** The mental V-Y advancement flap method is useful for reconstruction of lower lip defect because of its many advantages. However, it is not easy to select the optimal reconstructive method for the vermilion defect that remains after application of the mental V-Y advancement flap. In choosing the representative surgical method for vermilion mucosal reconstruction including mucosal V-Y advancement flap, buccal mucosal flap, and buccal mucosal graft. We describe an efficient technique to large lower lip defects combining mental V-Y advancement flap and buccal mucosal graft

**Methods:** This study included 16 patients who underwent reconstructive surgery for full-thickness and large defect (> half the entire width) of the lower lip from October 2006 to September 2017. The operation was conducted using mental V-Y advancement flap with various vermilion mucosal reconstruction methods considering the location of the defect and the amount of residual tissue of the lip coloboma after excision.

**Results:** All patients underwent mental V-Y advancement flap. In vermilion mucosal reconstruction, five patients underwent mucosal V-Y advancement flap, three underwent buccal mucosal flap, and eight underwent buccal mucosal graft. There were good aesthetic and functional results in all patients who underwent buccal mucosal graft. However, two patients who underwent mucosal V-Y advancement flap complained of oral incompetence, and all patients who underwent buccal mucosal flap had oral commissure deformity.

**Conclusion:** Buccal mucosal graft combined with mental V-Y advancement flap can produce suitable functional and aesthetic outcomes in near total lower lip reconstruction in patient with large mucosal defect including vermilion portion.

**Keywords:** Lip / Mouth mucosa / Surgical flap

**Correspondence:** Won Suk Lee  
Department of Emergency Medicine, Eulji University College of Medicine, 77 Gyeryong-ro 771beon-gil, Jung-gu, Daejeon 34824, Korea  
E-mail: medulla@eulji.ac.kr

Sang-Ha Oh  
Department of Plastic and Reconstructive Surgery, School of Medicine, Chungnam National University, 282 Munwha-ro, Jung-gu, Daejeon, 35015 Korea  
E-mail: djplastic@cnu.ac.kr

This work was supported by research fund of Chungnam National University. This work was supported by Chungnam National University Hospital Research Fund, 2017.

Received June 25, 2018 / Revised March 17, 2019 / Accepted April 2, 2019

## INTRODUCTION

The challenge to lower lip reconstruction is that it involves preservation of function while considering aesthetic results. Although full-thickness defects of less than one-third of the length of the lower lip can be reconstructed by simple primary closure, various kinds of flap procedures have been described to permit reconstruction of larger defects [1]. However, functional and aesthetic preservation is difficult for larger lower-lip defects.

Sufficient oral competence, muscle function, sensation, oral gape and aesthetic results are the basic goals of lower lip reconstruction. The mental V-Y advancement flap is a very useful method for lower lip reconstruction. The mental V-Y advancement flap is a functional lower lip reconstruction technique that includes transfer of the myocutaneous flap based on the mental neurovascular bundle and on branches of the facial artery that has many advantages over other methods [2,3]. If a mental V-Y advancement flap is elevated bilaterally, even a full thickness total defect of the lower lip can be restored [2].

The new vermilion mucosal surface can be created by various methods of lip reconstruction; however, restoration of its structure is difficult. Mental V-Y advancement flap was conducted for reconstruction of cutaneous layer. After that, the vermilion mucosal layer was reconstructed by representative methods such as mucosal V-Y advancement flap [4], buccal mucosal flap [5], and buccal mucosal graft [6]. We describe an efficient technique to large lower lip defects combining mental V-Y advancement flap and buccal mucosal graft and present our long-term outcomes.

## METHODS

### Patients

This study was approved by the ethics committee of the faculty of Chungnam National University Hospital (IRB No. CNUH 2017-10-037). The study included sixteen patients who underwent lower lip reconstruction between October 2006 and September 2017 at our hospital. The mean age was 61 years (range, 25–82 years), and eight patients were female. The condition was caused by squamous cell carcinoma in 12 patients and trauma in the remaining four. Full-thickness defect sizes were between half and two-thirds the entire width of the lower lip (Table 1). All surgery was performed by a single senior surgeon (SHO) in this study. The authors evaluated this approach with regard to functional and esthetic outcome and to identify long-term complications.

### Surgical technique

In all cases of this study, mental V-Y advancement flap was performed first for cutaneous layer reconstruction of volume for vermilion. A mental V-Y advancement flap was designed according to the defect's shape, with the apex lying inferiorly and incorporating the mental nerve. The base of the triangle abutted the inferior border of the defect site, and the apex lay below the mandible edge. Following skin incision on the planned borders of the V-Y flap, the flap was elevated from the bone in a medial to lateral direction after deepening the medial incision

to the periosteum. Careful attention was paid to preserve the integrity of the mental neurovascular bundle. The mandibular attachments of the depressor muscles were separated from the bone while elevating the flap apex, after which the dissection was conducted superiorly at the lateral border, leaving the orbicularis oris and depressor anguli oris muscles intact, although their attachments to the bone had already been separated. Thus, a mental V-Y advancement flap was created and advanced superomedially based on the intact neurovascular bundle and two previously mentioned muscles. A new oral sphincter was created with these muscles [2].

The mental V-Y advancement flap was modified to provide a sufficient volume for the vermilion. The base of the triangle, the superior margin of the flap, was in contact with the inferior border of the defect. For vermilion mucosal coverage, the base of the triangle was de-epithelialized by about 1 cm in width, after which it was advanced to the defect site to restore the volume of the resected lip. There was no special difficulty in advance as much as it needs.

The remaining vermilion mucosal defects were covered with a mucosal V-Y advancement flap, buccal mucosal flap, or buccal mucosal graft. In the mucosal V-Y advancement flap, a V-shaped mucosal flap was designed at the oral vestibule adjacent to the defect, with the vermilion defect margin serving as the base of this triangular flap and the tip of the flap leading to the fornix. The mucosal and submucosal tissues were incised and dissected, after which the V-shaped mucosal flap was advanced to the defect to completely cover the wound (Fig. 1) [4].

It is important to avoid injuring the opening of the parotid gland in a buccal mucosal flap. After the opening of the parotid gland is located, a site 7–10 mm inferior to this opening is set as the upper margin of the flap, and the flap is then designed on the mucosa in the buccal aspect in the shape of the semi-spindle extending in the pharyngeal direction with its pedicle at the angle of the mouth. The width-to length ratio of the flap is about 1:3. The flap, which contains fibers of the buccinators muscle along its entire length, is raised. At this time, when raising the flap from the layer of buccal fat, care must be taken to ensure that the flap contains a branch of the facial artery. The flap is then transposed to the lower vermilion defect and sutured and the donor site for the flap is closed primarily (Fig. 2) [5].

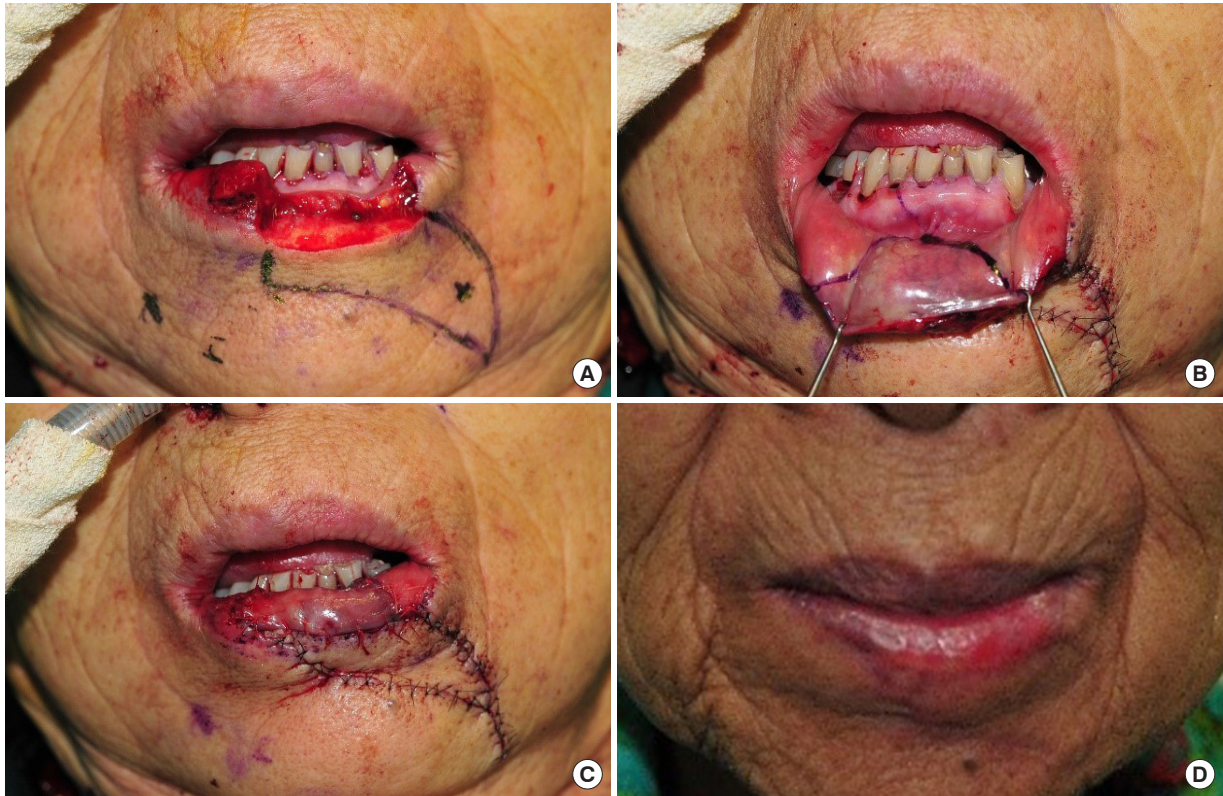Another way of providing vermilion coverage is via buccal mucosal graft. To accomplish this, the mucosa is harvested from the buccal side of the oral cavity. The mucosal graft includes only mucosa for a high survival rate. The donor site is then closed with a primary suture. Finally, tie-over dressing is applied and then removed from the recipient site after 3 days (Fig. 3).

**Table 1.** Characteristics of the patients

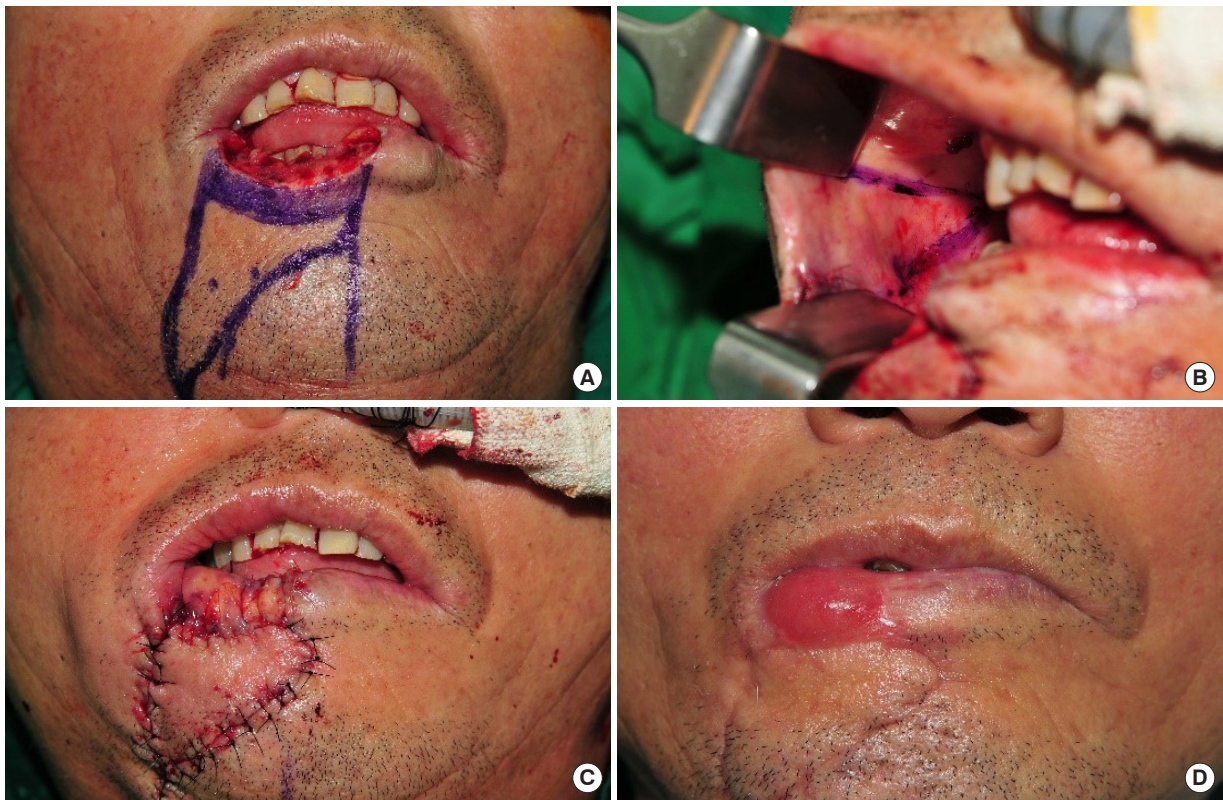
Case	Age (yr)/sex	Cause	Defect size (%)	Lower lip reconstruction method	Vermilion reconstruction method	Wound complications	Functional outcome		Esthetic outcome		Follow-up (mo)	
							Microstomy/mouth opening limitation	Oral continence	Commissure deformity	Assessment		
1	55/M	Trauma	50	Mental V-Y advancement flap	Buccal mucosal graft	No	No/no	No	No	Satisfied	No	6
2	50/M	SCC	50	Mental V-Y advancement flap	Buccal mucosal graft	Graft failure	No/no	No	No	Accepted	Buccal mucosal re-graft	9
3	76/F	SCC	50	Mental V-Y advancement flap	Mucosal V-Y advancement flap	No	No/no	No	No	Accepted	No	15
4	69/F	SCC	50	Mental V-Y advancement flap	Mucosal V-Y advancement flap	No	No/no	Drooling/fluid incontinence	No	Unaccepted	No	18
5	76/F	SCC	50	Mental V-Y advancement flap	Buccal mucosal graft	No	No/no	No	No	Satisfied	No	9
6	82/F	SCC	60	Mental V-Y advancement flap	Mucosal V-Y advancement flap	No	No/no	No	No	Satisfied	No	12
7	78/F	SCC	70	Mental V-Y advancement flap	Buccal mucosal graft	No	No/no	No	No	Satisfied	No	12
8	78/M	SCC	70	Mental V-Y advancement flap	Buccal mucosal flap	No	No/no	No	Distortion	Unaccepted	No	18
9	27/M	Trauma	50	Mental V-Y advancement flap	Buccal mucosal graft	No	No/no	No	No	Accepted	No	9
10	62/M	SCC	50	Mental V-Y advancement flap	Buccal mucosal flap	No	No/no	No	Distortion	Unaccepted	Division	25
11	82/M	SCC	80	Mental V-Y advancement flap	Buccal mucosal graft	No	No/no	No	No	Satisfied	No	12
12	32/M	Trauma	50	Mental V-Y advancement flap	Buccal mucosal flap	No	No/no	No	Distortion	Unaccepted	No	21
13	75/F	SCC	60	Mental V-Y advancement flap	Mucosal V-Y advancement flap	No	No/no	Drooling/fluid incontinence	No	Accepted	No	15
14	69/F	SCC	70	Mental V-Y advancement flap	Mucosal V-Y advancement flap	No	No/no	No	No	Accepted	No	18
15	25/F	Trauma	50	Mental V-Y advancement flap	Buccal mucosal graft	No	No/no	No	No	Satisfied	No	9
16	39/M	SCC	60	Mental V-Y advancement flap	Buccal mucosal graft	No	No/no	No	No	Accepted	No	15

M, male; F, female; SCC, squamous cell carcinoma.



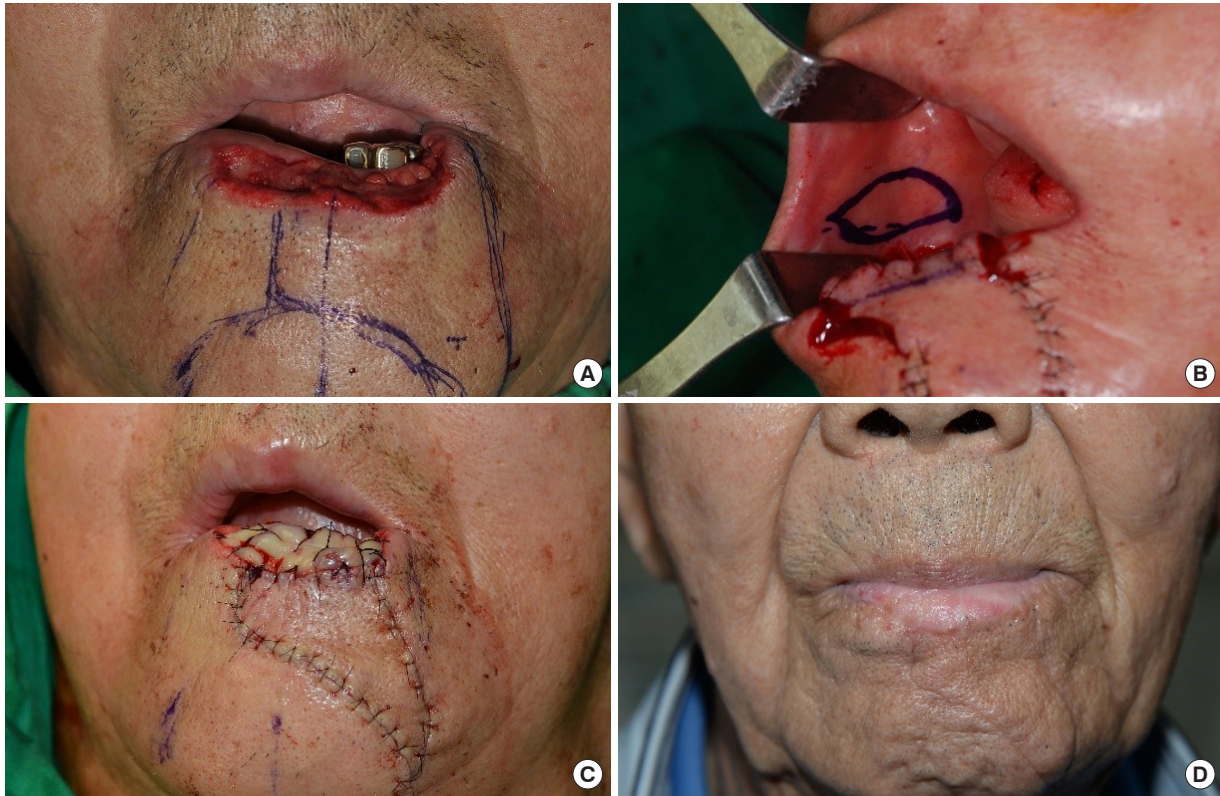

**Fig. 1.** Case 6. (A) A mental V-Y advancement flap for lower lip reconstruction is designed after tumor ablation. (B) Vermilion defect is reconstructed with the mucosal V-Y advancement flap. (C) Immediately postoperative view. (D) Two-month postoperative view.



**Fig. 2.** Case 10. (A) A mental V-Y advancement flap is designed after tumor ablation. (B) Vermilion defect is reconstructed with the buccal mucosal flap. (C) Immediately postoperative view. (D) Two-month postoperative view.





**Fig. 3.** Case 11. (A) A mental V-Y advancement flap is designed after tumor ablation. (B) Vermilion defect is reconstructed with the buccal mucosal graft. (C) Immediately postoperative view. (D) Two-month postoperative view.

### Postoperative care and monitoring

All patients were discharged on the 7th postoperative day and instructed to eat soft diets and avoid wide opening of the mouth for 4 weeks. Sutures were removed 12–14 days after surgery. The patients were asked to come for postoperative follow up once monthly for 6 months, then every 3 months for 2 years. All patients were evaluated for early postoperative complications in terms of hematoma, flap necrosis, infection, dehiscence and orocutaneous fistula and for late results regarding the functional aspect of the repair in terms of preservation of the oral competence and size of the oral stoma, limitation of mouth opening. As for esthetic outcome, objective assessment was done by same surgeon and was graded as “satisfied,” “accepted,” “unaccepted” in terms of symmetry of commissure at rest and at function, color and texture match with adjacent tissues.

## RESULTS

All patients underwent mental V-Y advancement flap for cutaneous layer reconstruction of lower lip defect. Vermilion mucosal defects remained after application of the mental V-Y advancement flap. Various vermilion reconstruction methods including mucosal V-Y advancement flap, buccal mucosal flap, or

buccal mucosal graft were performed. Specifically, mucosal V-Y advancement was performed in five patients, buccal mucosal flap in three and buccal mucosal graft in eight. The follow-up period ranged from 6 to 25 months (mean, 13.8 months). Failure of the buccal mucosal graft occurred in one patient who was treated with regraft from the contralateral side buccal mucosa due to partial necrosis. In the remaining patients, healing was uneventful without hematoma, infection, wound dehiscence, or flap necrosis. With regards to functional outcome, none of our patients developed microstomia and limitation of mouth opening. As for oral continence, two patients (40%) who underwent mucosal V-Y advancement flap had oral incompetence with temporary drooling and fluid incontinence for the first few months following surgery. Complete recovery of all functional changes occurred within 8–10 weeks. Most of the fundamental functions such as sensibility and mouth opening were satisfactory in all patient. However, Aesthetic aspects such as symmetry of commissure at rest and at function, color and texture match with adjacent tissues showed different outcome depending on vermilion mucosal reconstruction. Three patients (100%) who underwent buccal mucosal flap had oral commissure deformity like distortion of affected oral commissure. The final esthetic outcome as detected by the objective as-

assessment was “satisfied” in five patients (62.5%) of buccal mucosal graft group, one patient (20%) of mucosal V-Y advancement flap group and no patient of buccal mucosal flap group (Table 1).

## DISCUSSION

The main goal in lower lip reconstruction is good coverage of the vermilion and the adjacent skin associated with the reconstruction of oral sphincter competence, with minimal aesthetic and functional changes [7]. Normal function is achieved by obtaining a recovered wound that does not leak and by maintaining adequate tension on the cheek so that it does not droop or develop pockets that can collect food debris. Normal appearance is approximated by matching the color and texture of the repair to that of the surrounding skin and, when possible, by concealing the scars in borders between adjacent facial aesthetic units.

When a large defect involving more than half of the lower lip is created, reconstruction can be planned by a variety of tissue transfer techniques in which the usual donor sites are the adjacent cheek of the upper lip. The lip switch procedure produces a denervated reconstruction and transects the orbicularis oris sphincter [8]. The Karapandzic method [9], which maintains lip function and sensation, is probably the best choice in such cases. The principal disadvantage of this technique has been the relative microstomia in larger defects. Consequently, the Webster-Bernard technique [10] is the method of choice for repair of larger defects. The continuous tension of the closure frequently results in a tight, poorly functioning lower lip.

The cheek provides sufficient tissue as the donor site for reconstruction of large lower lip defects. In contrast to partial loss, there is little possibility of achieving a functional and sensate lower lip using classical methods such as the Gillies fan flap. The neurovascular and myocutaneous flap models, such as the gate flap [11] or the steeple flap [12], are created from the nasolabial area to achieve functional lower lip repairs. These procedures provide sufficient tissue to reconstruct the large defects of the lower lip, but denervate the upper lip and destroy the orbicularis muscle around the commissure.

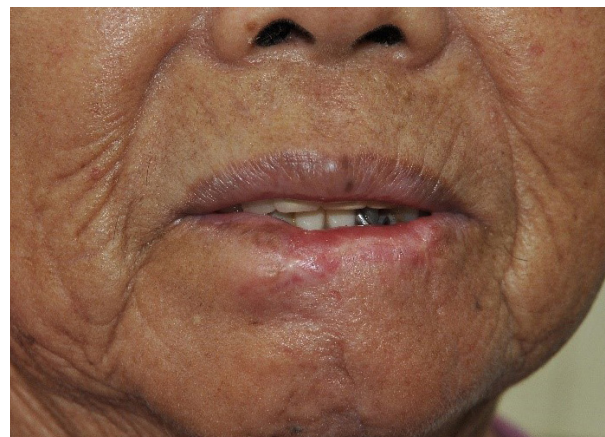The basis of the mental V-Y advancement flap is simple advancement of tissues from both sides of the chin as the myocutaneous flaps upward toward the lip defect and reorients the muscles of the flap for sphincteric function while preserving the mental nerve for sensation. Soft tissues over the mentum are not disturbed and are preserved as an intact unit. The lateral muscle attachments with their vascular and nerve supply are preserved and ensure muscular continuity and function. Since

the lateral attachments of these muscles are bluntly separated from the overlying skin and underlying mandible and mucosa, upper lip sensation and motor functions are not affected [2]. In our study, half of the patients complained of temporary sensory loss, but all recovered to almost normal sensation in a few weeks. In addition, there were no motor function problems

The vermilion is the most apparent cosmetic portion of the lip, and its color is derived the extensive superficial vascularization in this area. The color and morphology of vermilion play an important role in facial aesthetics [7]. Therefore, not only the reconstruction of the cutaneous layer recovers the entire volume of anteroposterior dimension, but also the vermilion mucosal coverage needs to be carefully considered.

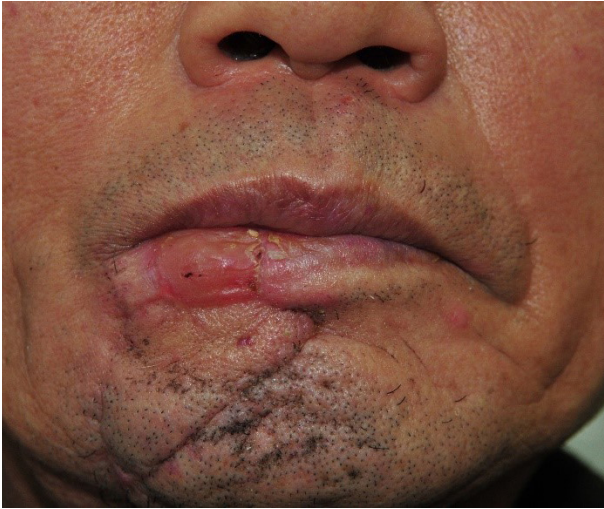The vermilion mucosal layer can be reconstructed by advancement flaps, cross-lip flaps, tongue flaps, or buccal mucosal flaps. The upper lip and tongue provide sufficient donor site tissue for reconstruction of a vermilion defect. A disadvantage of this procedure is that it is necessary to keep the upper lip and tongue attached to the lower lip for a period of 2 weeks, and the pedicle is then divided in a second surgical stage [13,14].

The mucosal V-Y advancement flap is easy and provides good aesthetic results when properly applied, especially in the medial side defect of vermilion. It can be used when the vermilion defects with lengths do not exceed 50% of the entire vermilion or when the extra portion of the oral vestibule mucosa on the lingual side near the defect is abundant [4]. On the other hand, it is difficult to apply to the defect near the oral commissure, and it has potential disadvantages such as a decrease in the anterior-posterior dimension of the lip [15,16]. In our study, two patients who underwent mucosal V-Y advancement flap had oral incompetence (Fig. 4). Temporary drooling and fluid incontinence were the most common complaint in two patients for the



**Fig. 4.** Case 13. The patient who underwent mucosal V-Y advancement flap for vermilion reconstruction had oral incompetence in resting.



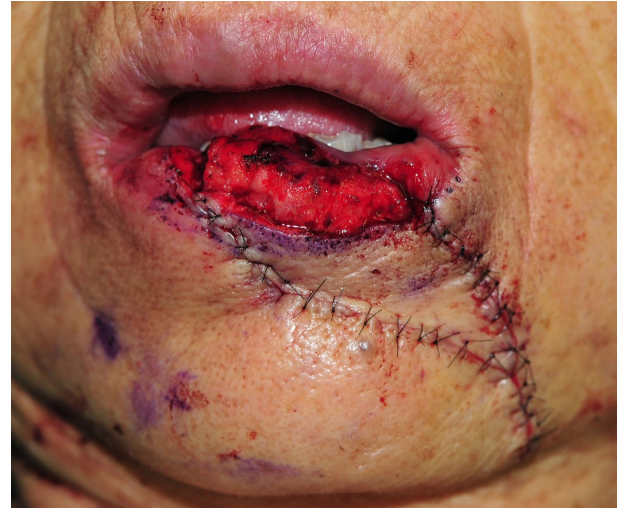

**Fig. 5.** Case 10. The patient who underwent buccal mucosal flap for vermilion reconstruction had commissure deformity, although a secondary procedure (division and de-bulking) was done.

first few months following surgery. This is because the flap has limited applications in large defects of the mucosal surface of the lip. But this problem resolved within a few months postoperatively.

The commissure based buccal mucosal flap can cover various sizes or locations of the defect. Modification of this flap, including large-size flaps or bilateral buccal mucosal flaps may be applied depending on the size or location of the defect. Ono et al. [5] reported maximum flap size can be developed in adult patients is 1.5 cm in width and 5 cm in length. However, when flap is elevated, careful attention must be paid to avoid injury of parotid gland opening and to contain a branch of the facial artery running from the angle of the mouth to the pharynx and a disadvantage of this procedure is that it causes distortion of the oral commissure, which is difficult to correct. In our study, all three patients who underwent the buccal mucosal flap procedure had oral commissure deformity. It is difficult to fix an already distorted oral commissure. One patient tried to overcome this oral commissure deformity through flap division and de-bulking, but was not satisfied with the result (Fig. 5).

Compared to other vermilion mucosal reconstruction, the advantages of using a buccal mucosal graft for vermilion reconstruction are that it is easy, provides good aesthetic results and has little or no residual donor site morbidity. Use of the hard palate as a donor site has been reported [17,18]. We used the mucosa of the buccal side of the oral cavity as donor site of mucosal graft. Harvesting the buccal mucosa is convenient because the donor site is within the same surgical field, and the characteristics of the buccal mucosa are more similar to those of the lip than the palatal mucosa. In addition, the donor site is closed



**Fig. 6.** In a mental V-Y advancement flap, the base of the triangle was de-epithelialized by about 1 cm in width, after which it was advanced to the defect site to restore the volume of the resected lip.

with a primarily so that the procedure causes less pain and is easy to manage postoperatively [6]. If large amounts of mucosal coverage are needed, buccal mucosa graft can be harvested bilaterally. When buccal mucosal graft is conducted alone, the limitations is that it does not supply sufficient volume of full thickness defect, therefore we recommend to mental V-Y advancement flap with buccal mucosal graft. As mentioned above, the base of the triangle, the superior margin of the flap, was in contact with the inferior border of the defect. The base of the triangle was de-epithelialized by about 1 cm in width, after which the de-epithelialized base of the triangle was advanced to the defect site to restore the volume of the resected lip (Fig. 6). One of the disadvantages of buccal mucosal grafts is that the graft is tendency to dry out for a certain period of time and resulting in keratotic changes and this is also in the case of commissure based buccal mucosal flaps. The keratotic changes observed in the reconstructed vermilion for a period of time are thought to be due to histologic differences between the oral mucosa and the vermilion, and these changes gradually disappear within 6 months of surgery. And care should be taken to determine precisely the opening of the parotid gland to avoid damages to this opening at the time of graft design [5].

The advantages of using a mental V-Y advancement flap combined with buccal mucosal graft for reconstruction of the lower lip are as follows: (1) it maintains almost normal sensation; (2) there are no problems associated with oral competence and mouth opening; (3) the color, texture, and contour of the reconstructed vermilion are aesthetically acceptable; (4) and there is little donor site morbidity. Therefore, we believe that the presented technique must be considered as one of the efficient

methods for functional and esthetic reconstruction of full-thickness subtotal lower lip defects.

## NOTES

### Conflict of interest

No potential conflict of interest relevant to this article was reported.

### Ethical approval

The study was approved by the Institutional Review Board of Chungnam National University Hospital (IRB No. CNUH 2017-10-037) and performed in accordance with the principles of the Declaration of Helsinki. Written informed consents were obtained.

### Patient consent

The patients provided written informed consent for the publication and the use of their images.

### ORCID

Joo-Hak Kim <https://orcid.org/0000-0001-9244-0940>  
Chang Hwan Ahn <https://orcid.org/0000-0003-4182-3823>  
Sunje Kim <https://orcid.org/0000-0001-7887-7521>  
Won Suk Lee <https://orcid.org/0000-0001-8226-9166>  
Sang-Ha Oh <https://orcid.org/0000-0003-3734-5005>

## REFERENCES

1. Clossmann JJ, Pogrel MA, Schmidt BL. Reconstruction of perioral defects following resection for oral squamous cell carcinoma. *J Oral Maxillofac Surg* 2006;64:367-74.
2. Bayramicli M, Numanoglu A, Tezel E. The mental V-Y island advancement flap in functional lower lip reconstruction. *Plast Reconstr Surg* 1997;100:1682-90.
3. Chen WL, Wang YY, Zhou M, Yang ZH, Zhang DM. Double mental neurovascular V-Y island advancement flaps combined with tongue flaps for functionally reconstructing total lower-lip defects. *J Craniofac Surg* 2012;23:181-3.
4. Jin X, Teng L, Zhang C, Xu J, Lu J, Zhang B, et al. Reconstruction of partial-thickness vermilion defects with a mucosal V-Y advancement flap based on the orbicularis oris muscle. *J Plast Reconstr Aesthet Surg* 2011;64:472-6.
5. Ono I, Gunji H, Tateshita T, Sanbe N. Reconstruction of defects of the entire vermilion with a buccal musculomucosal flap following resection of malignant tumors of the lower lip. *Plast Reconstr Surg* 1997;100:422-30.
6. Seo YJ, Song SH, Choi YW, Oh SH. A lower lip reconstruction. *Dermatol Surg* 2015;41:505-7.
7. Jun G, Wei F, Tong L, Yi H, Hao Z, Jun LS. Aesthetic and functional evaluation of large full-thickness vermilion and lower lip defects reconstruction. *J Craniofac Surg* 2019;30:e36-9.
8. Erol OO, Pence M, Agaoglu G. The Abbé island flap for the reconstruction of severe secondary cleft lip deformities. *J Craniofac Surg* 2007;18:766-72.
9. Karapandzic M. Reconstruction of lip defects by local arterial flaps. *Br J Plast Surg* 1974;27:93-7.
10. Webster RC, Coffey RJ, Kelleher RE. Total and partial reconstruction of the lower lip with innervated musclebearing flaps. *Plast Reconstr Surg Transplant Bull* 1960;25:360-71.
11. Alic B, Gurel M, Cilengir M, Seyhan A, Atlihan S. Unilateral gate flap for reconstruction of the lower lip. *Plast Reconstr Surg* 1989;84:814-9.
12. Stranc MF, Robertson GA. Steeple flap reconstruction of the lower lip. *Ann Plast Surg* 1983;10:4-11.
13. Kawamoto HK Jr. Correction of major defects of the vermilion with a cross-lip vermilion flap. *Plast Reconstr Surg* 1979;64:315-8.
14. Yano K, Hosokawa K, Kubo T. Combined tongue flap and V-Y advancement flap for lower lip defects. *Br J Plast Surg* 2005;58:258-62.
15. Goldstein MH. A tissue-expanding vermilion myocutaneous flap for lip repair. *Plast Reconstr Surg* 1984;73:768-70.
16. Sand M, Altmeyer P, Bechara FG. Mucosal advancement flap versus primary closure after vermilionectomy of the lower lip. *Dermatol Surg* 2010;36:1987-92.
17. Vecchione TR. Palatal grafts for lip reconstruction. *Ann Plast Surg* 1983;10:301-5.
18. Ito R, Fujiwara M. Lower lip reconstruction with a hard palate mucoperiosteal graft. *J Plast Reconstr Aesthet Surg* 2009;62:e333-6.