

# Temporary Right Ventricular Assist Device Insertion via Left Thoracotomy after Left Ventricular Assist Device Implantation

Ilkun Park, M.D., Yang Hyun Cho, M.D., Ph.D.,  
Su Ryeun Chung, M.D., Ph.D., Dong Seop Jeong, M.D., Ph.D.,  
Kiick Sung, M.D., Ph.D., Wook Sung Kim, M.D., Ph.D., Young Tak Lee, M.D., Ph.D.

*Department of Thoracic and Cardiovascular Surgery, Samsung Medical Center,  
Sungkyunkwan University School of Medicine, Seoul, Korea*

Right heart failure is a relatively common complication after left ventricular assist device (LVAD) implantation. Severe right heart failure can be managed by temporary right ventricular assist device (RVAD) implantation. However, trans-sternal RVAD insertion requires a subsequent third sternotomy for cannula removal. Herein, we present a case of RVAD insertion via a left anterior mini-thoracotomy after LVAD implantation in a patient with alcohol-induced cardiomyopathy.

*Key words:* 1. Right-sided heart failure  
2. Left ventricular assist device  
3. Extracorporeal life support

## Case report

A 47-year-old man with alcohol-induced dilated cardiomyopathy and chronic atrial fibrillation was admitted for New York Heart Association class IV dyspnea. He had a history of excess alcohol consumption (more than 100 g of alcohol daily) for over 20 years. He had been hospitalized 4 times in a 7-year period for symptoms of heart failure. He presented with dyspnea and azotemia and was managed with a continuous infusion of dobutamine and milrinone, along with continuous renal replacement therapy. On hospital day 33, he experienced cardiac arrest due to ventricular fibrillation and returned to spontaneous circulation after 4 minutes of car-

diopulmonary resuscitation.

Transthoracic echocardiography showed decreased left and right ventricular systolic function (left ventricular ejection fraction, 30%; tricuspid annular plane systolic excursion, 8.5 mm). Severe mitral and tricuspid regurgitation were present. The inferior vena cava was dilated, with a diameter of 3.1 cm and associated plethora, and his right ventricular systolic pressure was 44.3 mm Hg. He also had severe cardiomegaly with pericardial effusion (Fig. 1). Because he could not lay supine, right heart catheterization could not be performed. His serum creatinine level was 1.81 mg/dL, the estimated glomerular filtration rate was 40.4 mL/min/m<sup>2</sup>, and the total bilirubin level was 3.1 mg/dL.

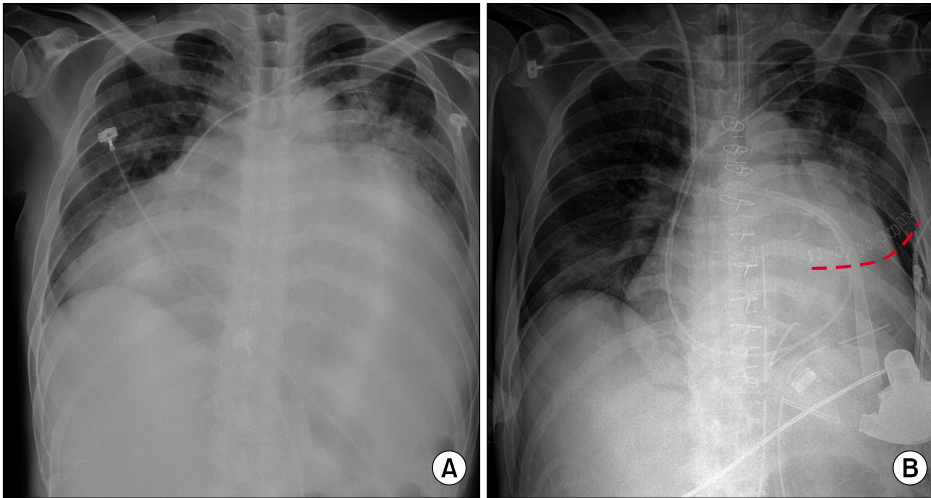
<sup>†</sup>This study was presented in the 2017 Fall Conference of The Korean Society of Thoracic and Cardiovascular Surgery (Forum 11th).

Received: May 31, 2018, Revised: July 5, 2018, Accepted: November 14, 2018, Published online: April 5, 2019

Corresponding author: Yang Hyun Cho, Department of Thoracic and Cardiovascular Surgery, Samsung Medical Center, Sungkyunkwan University School of Medicine, 81 Irwon-ro, Gangnam-gu, Seoul 06351, Korea  
(Tel) 82-2-3410-2213 (Fax) 82-2-3410-0089 (E-mail) mdcho95@gmail.com

© The Korean Society for Thoracic and Cardiovascular Surgery. 2019. All right reserved.

© This is an open access article distributed under the terms of the Creative Commons Attribution Non-Commercial License (<http://creativecommons.org/licenses/by-nc/4.0>) which permits unrestricted non-commercial use, distribution, and reproduction in any medium, provided the original work is properly cited.



**Fig. 1.** (A) Preoperative chest X-ray. (B) Post-right ventricular assist device implantation chest X-ray. Red dashed line, left anterior mini-thoracotomy.

Because he was a recent alcohol abuser, we had an extensive discussion on further management of his severe heart failure. According to a psychiatric evaluation, he was more psychologically than physiologically dependent on alcohol. His wife and parents planned to provide psychosocial support. We accepted their plan and agreed to proceed with left ventricular assist device (LVAD) insertion and tricuspid annuloplasty. As a result of severe right ventricular failure, LVAD was offered under the condition that he would remain alcohol-free for at least 6 months, for a possible later heart transplantation.

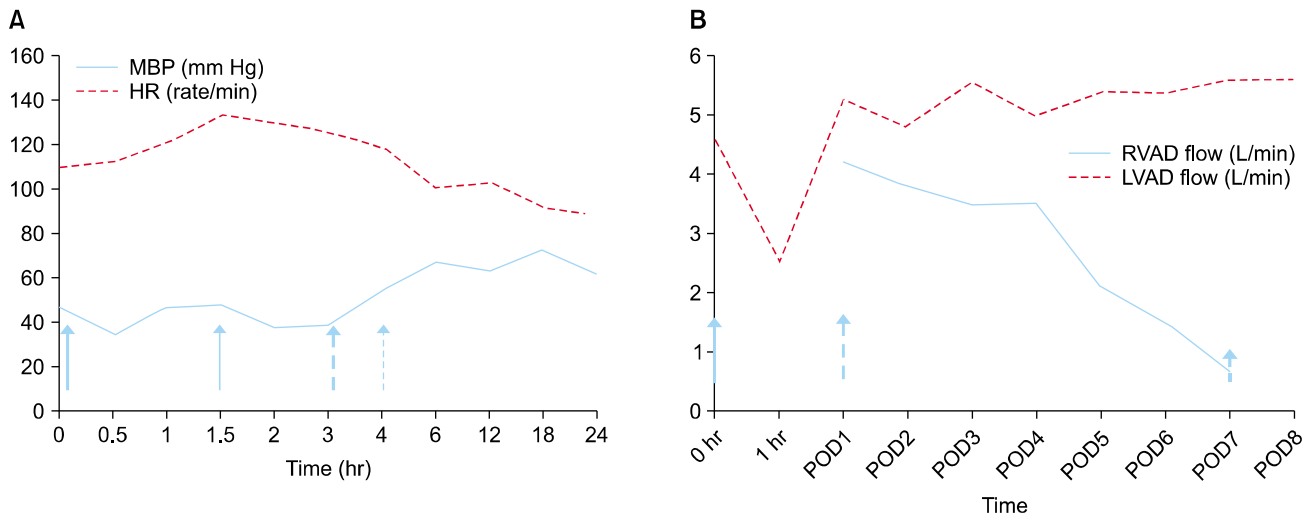
On hospital day 49, we performed surgery. Median sternotomy was performed and cardiopulmonary bypass was initiated with arterial cannulation into the ascending aorta, and bicaval venous cannulation was performed without aortic cross-clamping. After right atriotomy, beating heart tricuspid annuloplasty was performed with a Carpentier Edwards MC<sup>3</sup> 30-mm ring (Edwards Lifesciences, Irvine, CA, USA). After elevation, the left ventricular apex was sutured with a sewing ring, incised, and fixed with an LVAD inflow cannula (HeartWare, Framingham, MA, USA). The driveline was pulled out through the left upper quadrant abdominal wall using the double-tunnel technique. The outflow cannula was anastomosed to the right side of the proximal ascending aorta and the LVAD was initiated. After careful de-airing, the patient was successfully weaned from cardiopulmonary bypass with inotropic support (dobutamine [3  $\mu$ g/kg/min] and milrinone [0.7  $\mu$ g/kg/min]) and the LVAD flow was increased to 4.5 L/min at 2,500

rpm. With stable vital signs, the patient was transferred to the cardiovascular intensive care unit (ICU).

He was stable for a few hours. After he awoke and coughed, hypotension and tachycardia developed. Despite inotrope infusion and nitric oxide inhalation, he was still unstable (Fig. 2), with hypotension (mean arterial blood pressure [MBP], 40 mm Hg), high central venous pressure (CVP; range, 15–18 mm Hg), low LVAD flow (2.5 L/min), and low pulmonary arterial pressure (systolic pulmonary arterial pressure, 23 mm Hg; diastolic pulmonary arterial pressure, 15 mm Hg). We decided to perform emergent insertion of an extracorporeal right ventricular assist device (RVAD) under veno-pulmonary artery extracorporeal life support, with the patient in the ICU.

To avoid repeat sternotomy for insertion and removal of the pulmonary artery cannula, we decided to perform percutaneous femoral venous cannulation and pulmonary artery cannulation via a left anterior mini-thoracotomy. A 22F venous cannula was inserted into the femoral vein using the Seldinger technique. Left anterior thoracotomy was performed at the second intercostal space. After double purse-string suturing, return arterial cannulation (15F) was placed in the main pulmonary artery. The extracorporeal RVAD was initiated with a flow of 4.4 L/min. The LVAD flow was increased to 4.7 L/min at 2,500 rpm. The thoracotomy was closed after maintaining stable LVAD flow.

After RVAD implantation, inhaled nitric oxide was tapered and the patient showed stable hemodynamics, with a CVP of 8 mm Hg, an MBP of >60



**Fig. 2.** Hemodynamic parameters after LVAD implantation. Signs of right heart failure include elevated CVP and heart rate; decreased cardiac output, LVAD flow, and mean blood pressure; and normal pulmonary arterial pressure. (A) Early post-LVAD hemodynamics. (B) RVAD and LVAD flow during weaning from the RVAD. Bold arrow, immediate postoperative; arrow, start of nitric oxide; dashed bold arrow, RVAD insertion; dashed arrow, cessation of nitric oxide; short arrow, RVAD removal. LVAD, left ventricular assist device; CVP, central venous pressure; RVAD, right ventricular assist device; MBP, mean blood pressure; HR, heart rate; POD, postoperative day.

mm Hg, and a heart rate of 80–90/min. The RVAD rpm and flow rates were slowly decreased with spontaneous recovery of right ventricular systolic function. The RVAD was removed after 6 days (Fig. 2). After general anesthesia in the ICU, the return cannulation into the main pulmonary artery was removed via a redo thoracotomy using the previous incision, and the venous cannulation was simultaneously removed from the right femoral insertion site.

The patient was transferred to the general ward on hospital day 73. After resolution of lower leg pitting edema and rehabilitation therapy, he was discharged at 129 days postoperatively. However, he was repeatedly noncompliant with medical therapy. He was readmitted for recurrent alcohol abuse and subsequent right ventricular failure. At 251 days after implantation, the LVAD was turned off due to irreversible septic encephalopathy and coma.

It was impossible to get a written informed consent because the patient was in coma status when we are reporting this case.

## Discussion

The incidence of right heart failure after LVAD implantation is approximately 20%, depending on the

institution, LVAD type, and patient subgroup [1]. LVAD reduces the right heart afterload, but increases the preload if the LV ejection fraction increases from 20%–30% to a near normal level. In addition, unloading of the LV and an interventricular septal shift toward the LV causes a change in right ventricular morphology. These all contribute to right heart dysfunction after LVAD implantation.

When right ventricular failure is refractory to medical therapy, RVAD should be implanted without hesitation [2]. Right ventricular failure after LVAD implantation is generally an emergency and can lead to severe hemodynamic instability and organ failure. Insertion of RVAD in the ICU can eliminate the time lost to moving the patient and anesthetic preparation. It may also help sustain vital signs by avoiding the need to change ventilator settings and infusions. However, the place of surgery and the anesthetic preparation for RVAD implantation largely depend on the incision for the procedure.

An RVAD can be inserted via standard sternotomy, left thoracotomy, or percutaneously. Surgical RVAD generally requires repeat sternotomy for insertion and removal. Although some surgeons prefer using a substernal graft connection to the main pulmonary artery that can be ligated at the time of removal without sternotomy [3], any technique requiring re-

peat sternotomy may increase the chance of mediastinitis or device infection.

Stepanenko et al. [4] reported RVAD implantation through a redo thoracotomy after LVAD implantation via left lateral thoracotomy. In our case, we performed a separate small left anterior thoracotomy. The main pulmonary artery was easily visible through this incision. The separate mini-thoracotomy offers rapid access, easy cannulation, no need for repeat sternotomy and rewiring, little bleeding, a low risk of wound infection, and easy decannulation. Indeed, the total operative time for this case was 35 minutes, without significant bleeding or hemodynamic compromise. The patient quickly recovered after RVAD weaning without surgical complications. Because some patients receiving RVAD implantation have already undergone other cardiac procedures, including coronary artery bypass grafting, LVAD implantation, or other valve operations, RVAD outflow cannulation through the right pulmonary artery into the main pulmonary artery may also avoid extensive dissection and postoperative bleeding [5]. This technique could be used if extensive dissection involving the main pulmonary artery is needed.

Recently, percutaneous temporary RVAD support was reported in Germany [6]. This technique may be convenient and safe for RVAD implantation without operative complications, including postoperative bleeding and wound infection. However, it could have a deleterious effect on right-side heart valves. Moreover, although it would be a good option for planned concurrent RVAD and LVAD implantation, it would not be appropriate in emergent RVAD implantation, especially at the bedside, because intraoperative transesophageal echocardiography is essential for correct placement of the cannula.

In conclusion, we believe that this separate mini-thoracotomy approach for RVAD insertion may be an alternative option to sternotomy. Although many techniques have been reported for RVAD outflow cannulation, the technique should be individualized according to the patient.

## Conflict of interest

No potential conflict of interest relevant to this article was reported.

## ORCID

Ilkun Park: <https://orcid.org/0000-0001-6005-640X>  
Yang Hyun Cho: <https://orcid.org/0000-0003-1685-3641>  
Su Ryeun Chung: <https://orcid.org/0000-0002-9619-0640>  
Dong Seop Jeong: <https://orcid.org/0000-0002-6947-8403>  
Kiick Sung: <https://orcid.org/0000-0003-0768-9587>  
Wook Sung Kim: <https://orcid.org/0000-0001-7808-3385>  
Young Tak Lee: <https://orcid.org/0000-0001-8790-6099>

## References

1. Kormos RL, Teuteberg JJ, Pagani FD, et al. *Right ventricular failure in patients with the HeartMate II continuous-flow left ventricular assist device: incidence, risk factors, and effect on outcomes.* J Thorac Cardiovasc Surg 2010;139:1316-24.
2. Morgan JA, John R, Lee BJ, Oz MC, Naka Y. *Is severe right ventricular failure in left ventricular assist device recipients a risk factor for unsuccessful bridging to transplant and post-transplant mortality.* Ann Thorac Surg 2004;77: 859-63.
3. Strauch JT, Franke UF, Madershahian N, Wahlers T. *Right ventricular assist device implantation: a new transcatheter approach.* Thorac Cardiovasc Surg 2004;52:378-9.
4. Stepanenko A, Potapov EV, Krabatsch T, Hetzer R. *Simple implantation of a temporary right ventricular device for right ventricular failure after left ventricular device implantation via a left lateral thoracotomy.* ASAIO J 2011;57:17-8.
5. Minami K, Bonkohara Y, Arusoglu L, El-Banayosy A, Korfer R. *New technique for the outflow cannulation of right ventricular assist device.* Ann Thorac Surg 1999;68:1092-3.
6. Schmack B, Weymann A, Popov AF, et al. *Concurrent left ventricular assist device (LVAD) implantation and percutaneous temporary RVAD support via CardiacAssist Protek-Duo TandemHeart to preempt right heart failure.* Med Sci Monit Basic Res 2016;22:53-7.