

Reconsideration of Dr. Allen's Report about Hemoptysis Patients from High Prevalence of Archaeoparasitological Paragonimiasis in Korea

Min Seo¹, Jong-Yil Chai^{2,3}, Jong Ha Hong⁴, Dong Hoon Shin^{4,*}

¹Department of Parasitology, Dankook University College of Medicine, Cheonan 31116, Korea; ²Institute of Parasitic Diseases, Korea Association of Health Promotion, Seoul 07649, Korea; ³Department of Tropical Medicine and Parasitology, Seoul National University College of Medicine, Seoul 03080, Korea; ⁴Institute of Forensic Science/Department of Anatomy, Seoul National University College of Medicine, Seoul 03080, Korea

Abstract: Horace N. Allen, an American physician, was a Presbyterian missionary to Korea. In 1886, he wrote the annual report of the Korean government hospital, summarizing patient statistics according to outpatient and inpatient classification for the first ever in Korean history. In the report, he speculated that hemoptysis cases of outpatient might have been mainly caused by *distoma*. Allen's conjecture was noteworthy because only a few years lapsed since the first scientific report of paragonimiasis. However, he was not sure of his assumption either because it was not evidently supported by proper microscopic or post-mortem examinations. In this letter, we thus revisit his assumption with our parasitological data recently obtained from Joseon period mummies.

Key words: *Paragonimus* spp., Hemoptysis, Joseon Dynasty, Korean mummy, Horace Allen

Horace N. Allen (1858-1932) was born in Delaware, Ohio. After graduated from Miami Medical College, he volunteered to Korea (Joseon Kingdom) in 1884 as a Presbyterian missionary. During his stay in Korea, as a physician, he was involved in the establishment and maintenance of Gwanghyewon, the first Western medicine hospital in Korean history [1]. After running the hospital for a year, he wrote "the First Annual Report of the Korean Government Hospital, Seoul" in 1886 [2] (Fig. 1), mentioning about the medical situation of Joseon Kingdom, the status of the government hospital, and summarizing patient statistics according to outpatient (n=10,460) and inpatient (n=265) classification with brief notes on specific cases [1].

In the report, he classified the outpatients into 18 different signs or diseases: fever, diseases of the digestive system, circulatory system, respiratory system, nervous system, lymphatic system, genito-urinary diseases & syphilis, general diseases, new diseases, eye diseases, diseases of the ear, tumors, diseases of

bones, joints, and tendons, wounds and injuries, malformations, diseases of the connective tissue, skin diseases, diseases of women, and unclassified. Among the diseases of respiratory system, he identified 6 different signs and diseases: arteritis, aneurism finger, aneurism popliteal, epistaxis, hemoptysis, and mitral insufficiency [1].

As for hemoptysis, he reported 92 outpatient cases for a year. According to his report, "The 92 cases of Haemoptysis under Class III, doubtless include a number of cases of *distoma*, but as we have not a microscope nor the privilege of making post mortem examinations, we cannot be sure concerning it." On the hemoptysis, he commented in another report, Dr. H.N. Allen's Report on the Health of Seoul (Corea) [3], as follows: There are many cases of chronic blood-spitting, not connected with the physical signs of lung destruction. These cases, which are treated with dilute sulphuric acid and alum, seem to be of the same nature as the *distoma pulmonale*, discovered recently, and said to have been found in the person of Corean official resident for a short time at Tokio. Of course, postmortems are as yet out of the question here; and as a microscope has not until very recently been at hand, it has been impossible to say positively what the trouble is by examining the sputa.

As we can see, Allen strongly presumed that paragonimiasis could be the major etiology of hemoptysis encountered in the

•Received 18 May 2019, revised 19 August 2019, accepted 25 September 2019.

*Corresponding author (cuteminjae@gmail.com)

© 2019, Korean Society for Parasitology and Tropical Medicine

This is an Open Access article distributed under the terms of the Creative Commons Attribution Non-Commercial License (<http://creativecommons.org/licenses/by-nc/4.0>) which permits unrestricted non-commercial use, distribution, and reproduction in any medium, provided the original work is properly cited.

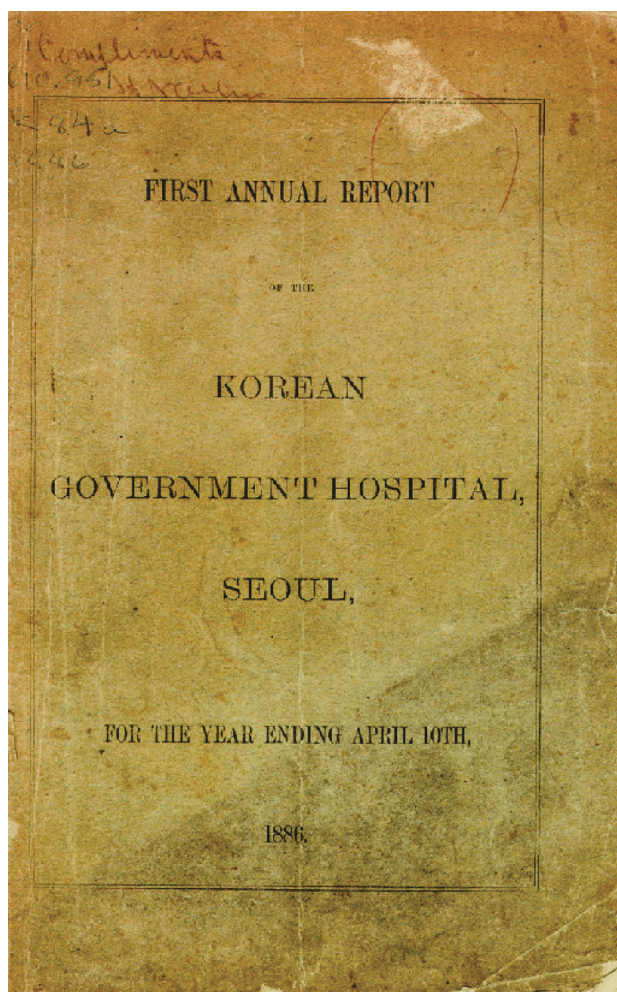


Fig. 1. Dr. Allen's "the First Annual Report of the Korean Government Hospital, Seoul." It was reproduced based on the plate published in Yeo [1] under a CC BY-NC 4.0 (<http://creativecommons.org/licenses/by/4.0/>) license. We abided by the copyright terms and conditions, obtaining the mandatory permit from the original copyright holder (Yeo IS).

late 19th century Joseon. Allen's such a conjecture is noteworthy in several respects. First, human paragonimiasis was only reported by the discovery of the parasite in the lung (by B.S. Ringer in 1879) as well as the eggs in the sputum from human beings (by P. Manson and E. Baelz in 1880) [4]. When he suspected a paragonimiasis in Korea, only a few years lapsed since the first report on the paragonimiasis from humans; and what is also surprising was that there were no reports about human paragonimiasis from Joseon society yet. Allen's conjecture about *P. westermani* as a prime etiology of Joseon people's hemoptysis is therefore noteworthy.

However, as seen in his report, he seems not have been

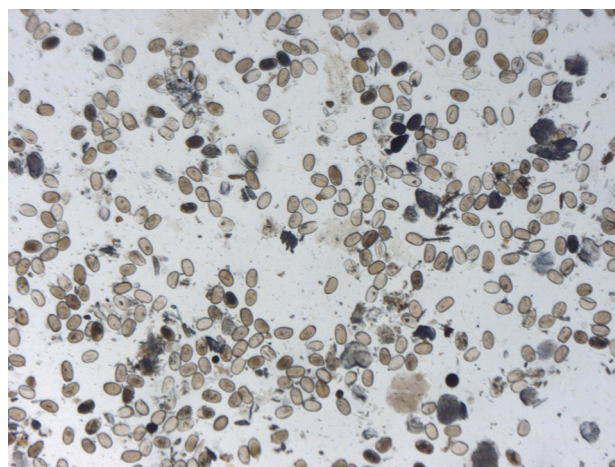


Fig. 2. *Paragonimus* sp. eggs found in the feces of Korean mummy (Hadong-2).

completely convinced of his own assumption either because proper microscopic or post mortem examination was not performed to show the authenticity of his diagnosis. This is also the same for us. In general, modern physicians think of pulmonary tuberculosis, bronchiectasis, bronchitis, pneumonia, lung cancer, and lung abscesses for the common etiologies of patient's hemoptysis. paragonimiasis could not be considered as the most likely cause of hemoptysis though it could be also regarded as one of the etiologies [5]. In this regard, Allen's speculation on whether the hemoptysis of the 19th century Joseon people was mainly due to paragonimiasis became completely inconclusive.

Meanwhile, the archaeoparasitological research in Korea conducted over the past decade has provided some meaningful implications to this century-old Allen's query. As we reported before, paleoparasitological surveys were done on mummies discovered at Joseon period tombs. The ancient parasite eggs identified in the mummy feces specimens (n=25) were *Ascaris*, *Trichuris*, *Paragonimus*, *Clonorchis*, and *Metagonimus* etc., all of which were evidenced by microscopic or molecular techniques [6-8] (Fig. 2). Using the data, we could estimate paragonimiasis prevalence among Joseon people.

According to recent studies on Joseon mummies, the prevalence of paragonimiasis among Joseon mummies reached as high as 36% (9/25) (Table 1) [7]. The prevalence of Korean people was still high at 9.4% (16,866 out of 180,351) in the Japanese colonial era, while it was only 0.1% among Japanese (10 out of 1,154) [9]. In 1971, it was revealed that the prevalence of paragonimiasis has dramatically decreased to 0.09% [7].

Table 1. Prevalences of paragonimiasis in the Joseon mummies previously reported by Seo et al. [7] and Shin et al. [8]

Case ID	Locality	Estimated Date	<i>Paragonimus</i> spp.	Ectopic paragonimiasis
Yongin	Yongin-si, Gyeonggi-do	15-16C	○	
Jinju	Jinju-si, Gyeongsangnam-do	15-16C	○	
Sapgyo	Sapgyo-eup, Yesan-gun, Chungcheongnam-do	16C		
Hadong-2	Hadong-gun, Gyeongsangnam-do	16-17C	○	○
Hadong-1	Hadong-gun, Gyeongsangnam-do	17C		
Sacheon	Sacheon-si, Gyeongsangnam-do	1620-1630		
Gangneung	Gangneung-si, Gangwon-do	1622		
Dangjin	Dangjin-si, Chungcheongnam-do	1633	○	
Mungyeong	Mungyeong-si, Gyeongsangbuk-do	1647		
Waegwan	Waegwan-eup, Chilgok-gun, Gyeongsangbuk-do	1685		
PJ SM ^a	Paju-si, Gyeonggi-do	1699		
Seocheon	Seocheon-gun Chungcheongnam-do	17C		
Yangju	Yangju-si, Gyeonggi-do	1640-1700		
SN ^b 1-2	Sinnae-dong, Seoul	1605-1733		
SN3-7-1	Sinnae-dong, Seoul	16-17C		
SN2-19-1	Sinnae-dong, Seoul	1765±10		
SN2-19-2	Sinnae-dong, Seoul	1755±10		
GJ ^c 1-2	Gongju-si Chungcheongnam-do	17-18C	○	
Hwasung	Hwaseong-si, Gyeonggi-do	18C	○	
Andong	Andong-si, Gyeongsangbuk-do	1571 ca.		
YG ^d 2-4	Yeonggwang-gun, Jeollanam-do	15-16C	○	
YG2-6	Yeonggwang-gun, Jeollanam-do	15-16C	○	
Dalsung	Dalseong-gun, Daegu	16-17C		
Junggye	Junggye-dong, Seoul	16-17C		
Cheongdo	Cheongdo-gun, Gyeongsangbuk-do	1642	○	○

^aPaju Sacheon-Mok, ^bSinnae, ^cGongju, ^dYeonggwang.

In other words, unlike in the recent years when *P. westermani* is not a major cause of hemoptysis, many Joseon patients might have suffered from paragonimiasis-induced hemoptysis. We also consider the ectopic paragonimiasis among Joseon mummies. *Paragonimus* spp. sometimes migrates to extra-pulmonary organs such as the brain, muscle, omentum, and liver etc. [8]. As seen our previous reports, ancient *Paragonimus* sp. eggs were identified in the liver parenchyme (hepatic paragonimiasis) of 2 different Joseon mummies [8,10] (Table 1). We note that hepatic paragonimiasis has been very rarely reported from clinical fields [11]. The repeated reports of hepatic paragonimiasis in Korean mummy cases might have related to the strong-infectivity-enhancing high prevalence of paragonimiasis among the Joseon people [8]. All these findings highly suggest that Dr. Allen might make a sound presumption for *P. westermani* as the most common cause of the hemoptysis at the time.

Of course, we should admit our Joseon period data's limitations from statistical perspectives. Parasitological analysis on Joseon mummies does not represent the infection prevalence of entire Korean population at the time because they were of

high social status people in Joseon society. In addition, we must also consider the number of Korean mummies used for parasitological examination being too insufficient to deduce sound conclusions [7]. Even so, it could be deduced that some portion of hemoptysis patients in Korea might have been resulted from paragonimiasis at the end of the 19th century. Of course, further parasitological studies on archaeological specimens should be required for confirming Allen's report on hemoptysis and paragonimiasis.

ACKNOWLEDGMENT

This work was supported by the National Research Foundation of Korea (NRF) grant funded by the Korea government (MSIP) (NRF-2016R1A2B4015669; NRF-2019R1H1A2080094).

CONFLICT OF INTEREST

The authors declare no conflict of interest related to this study.

REFERENCES

1. Yeo IS. Allen Eui Euiryo Bogoseo. Seoul, Korea. Yeoksagonggan. 2016, pp 1-268 (in Korean).
2. Allen HN, Heron JW. First Annual Report of the Korean Government Hospital. Seoul, Korea. Yokohama, R. Meiklejohn. 1886.
3. Allen HN. Dr. H.N. Allen's Report on the Health of Seoul (Corea). In Medical Reports for the Half-Year Ended 30th September 1885 No. 30. Shanghai, China. Imperial Maritime Customs. pp 17-30.
4. Diaz JH. Paragonimiasis acquired in the United States: native and nonnative species. *Clin Microbiol Rev* 2013; 26: 493-504.
5. Korean Academy of Medicine. Textbook of Family Medicine. 4th ed. Seoul, Korea, Medical Publishing. 2015.
6. Seo M, Araujo A, Reinhard K, Chai JY, Shin DH. Paleoparasitological studies on mummies of the Joseon dynasty, Korea. *Korean J Parasitol* 2014; 52: 235-242.
7. Seo M, Oh CS, Hong JH, Chai JY, Cha SC, Bang Y, Cha IG, Wi YG, Park JM, Shin DH. Estimation of parasite infection prevalence of Joseon people by paleoparasitological data updates from the ancient feces of pre-modern Korean mummies. *Anthropol Sci* 2017; 125: 9-14.
8. Shin DH, Kim YS, Yoo DS, Kim MJ, Oh CS, Hong JH, Lee E, Chai JY, Seo M. A case of ectopic paragonimiasis in a 17th century Korean mummy. *J Parasitol* 2017; 103: 399-403.
9. Kobayashi H. On the Animal Parasites in Korea. *Japan Med World* 1925; 5: 9-16.
10. Shin DH, Oh CS, Lee SJ, Lee EJ, Yim SG, Kim MJ, Kim YS, Lee SD, Lee YS, Lee HJ, Seo M. Ectopic paragonimiasis from 400-year-old female mummy of Korea. *J Archaeol Sci* 2012; 39: 1103-1110.
11. Kim EA, Juhng SK, Kim HW, Kim GD, Lee YW, Cho HJ, Won JJ. Imaging findings of hepatic paragonimiasis: a case report. *J Korean Med Sci* 2004; 19: 759-762.