



# Medical adhesive related skin injury after dental surgery

Tae-Heung Kim<sup>1</sup>, Jun-Sang Lee<sup>1</sup>, Ji-Hye Ahn<sup>2</sup>, Cheul-Hong Kim<sup>2</sup>, Ji-Uk Yoon<sup>3</sup>, Eun-Jung Kim<sup>2</sup>

<sup>1</sup>Department of Oral and Maxillofacial Surgery, School of Dentistry, Pusan National University, Yangsan, Korea

<sup>2</sup>Department of Dental Anesthesia and Pain Medicine, Pusan National University Dental Hospital, Dental Research Institute, Yangsan, Korea

<sup>3</sup>Department of Anesthesia and Pain Medicine, Pusan National University Yangsan Hospital, Yangsan, Korea

An 87-year-old woman was referred for the extraction of residual teeth and removal of tori prior to prosthetic treatment. After surgery under general anesthesia, the surgical tape was removed to detach the bispectral index sensor and the hair cover. After the surgical tape was removed, skin injury occurred on the left side of her face. After epidermis repositioning and ointment application, a dressing was placed over the injury. Her wound was found to have healed completely on follow-up examination. Medical adhesive related skin injury (MARS) is a complication that can occur after surgery and subjects at the extremes of age with fragile skin are at a higher risk for such injuries. Careful assessment of the risk factors associated with MARS is an absolute necessity.

**Keywords:** Medical Adhesive; Skin Injury; Surgical Tape.



This is an Open Access article distributed under the terms of the Creative Commons Attribution Non-Commercial License (<http://creativecommons.org/licenses/by-nc/4.0/>) which permits unrestricted non-commercial use, distribution, and reproduction in any medium, provided the original work is properly cited.



## INTRODUCTION

Medical Adhesive Related Skin Injury (MARS) is a dermatological disorder in which erythema and/or other cutaneous abnormalities including, but not limited to, vesicles, bullae, erosions, or tears appear and persist for 30 min or more after removal of an adhesive [1]. MARS can be caused by various types of adhesive products such as tape, dressing bandage, and electrodes after surgery. It can occur in all ages but is more common in patients at the extremes of age with weak skin [2]. MARS can lead to pain, increased risk of infection, scar formation, prolonged duration of treatment, patient complaints, and many discomforts that reduce a patient's quality of life [3]. In order to prevent MARS, the proper type of

adhesive tape should be applied, and special care should be taken in high risk patients. Here, we report a case of facial skin injury, caused by surgical tape, that was treated in our department.

## CASE

An 87-year old woman visited our dental hospital for prosthetic treatment. She had residual teeth which could not be used as abutments for the denture. For prosthodontic rehabilitation, removal of remaining teeth and full denture placement were planned. Therefore, she was referred to the department of Oral surgery for extraction of the residual teeth and tori removal prior to prosthetic treatment. She had hypertension and was taking amlo-

Received: October 1, 2018 • Revised: October 8, 2018 • Accepted: October 10, 2018

Corresponding Author: Eun-Jung Kim, Department of Dental Anesthesia and Pain Medicine, Pusan National University Dental Hospital, Geumo-ro 20, Yangsan, Gyeongnam 626-787, Korea

Tel: +82-55-360-5370 Fax: +82-55-360-5369 Email: kejdream84@naver.com

Copyright© 2018 Journal of Dental Anesthesia and Pain Medicine

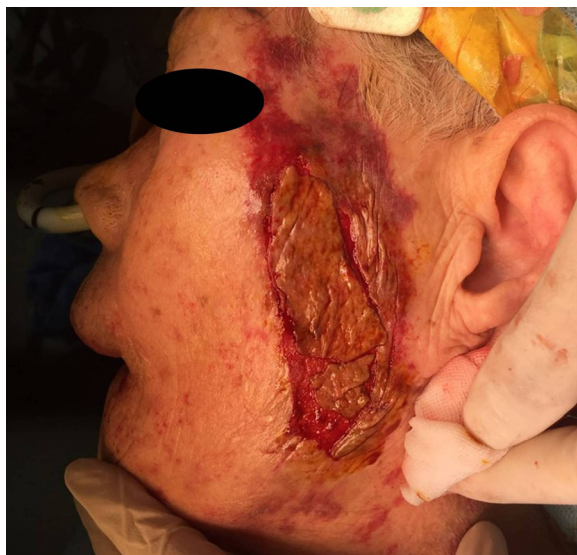

Fig. 1. Tape was removed and the skin peeled off.

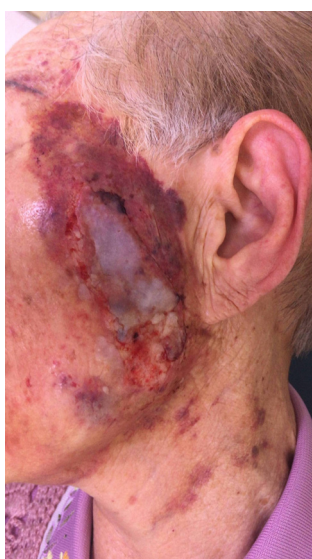

Fig. 2. After 5 days, bruising is worsened, but secondary healing is occurring.

dipine. The American Society of Anesthesiologists physical status of the patient was II. Preoperative laboratory findings and the chest X-ray image were normal. The electrocardiogram showed sinus rhythm with right bundle branch block and left anterior fascicular block. However, no significant abnormality was noted on echocardiography. Her skin was thin and inelastic due to aging, with extensive wrinkling in the face.

General anesthesia was induced for surgery and the patient was monitored. In addition, bispectral index (BIS)

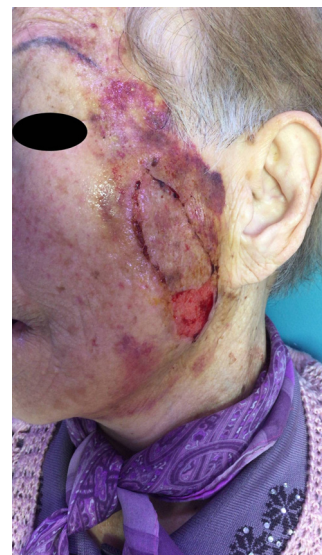


Fig. 3. After 12 days, bruising was fairly reduced.

monitoring was conducted for checking the depth of anesthesia and the BIS sensor was fixed using surgical drape tape (Loban™2 incise drapes; 3M, St Paul, MN, USA). Surgical tape was attached from the bottom of the ear to the forehead for prevention of betadine drape and water. Approximately one hour after the surgery, she was reversed from the effects of the muscle relaxant using pyridostigmine 10 mg and glycopyrrolate 0.4 mg. After extubation, the surgical tape was removed to detach the BIS sensor and the hair cover. After the surgical tape was removed, skin injury occurred on the left side of her face. Along the site of attachment, 1.5 cm by width and 4 cm by length of her skin peeled off with the surgical tape. In addition, a red bruise appeared around the area of the surgical tape (Fig. 1). Immediately after repositioning the epidermis, antibacterial ointment was applied and covered with non-adhesive foam dressing to maintain a moist wound environment. It was maintained for five days, and a repeat dressing was done during the next visit. The epidermis was retained and secondary healing had initiated in the uncovered area. However, the bruising had worsened (Fig. 2). After realignment of the epidermal margin, ointment was applied and a dressing was placed. She changed her dressing daily at home by herself and visited the clinic a week later. The wound had healed well compared to the first visit at outpatient clinic after

surgery. The area of bruising had reduced considerably. No evidence of infection was seen (Fig. 3). There was no problem in the intra-oral surgical site and stitch out was performed. She decided to continue performing the dressing at home by herself.

## DISCUSSION

MARSI is estimated to occur in at least 1.5 million patients annually in the United States [4]. Skin injuries caused by adhesive tapes occur in a variety of surgical situations. There are intrinsic and extrinsic factors related to the skin injury. Intrinsic factors include extremes of age: neonate or elderly, race, dermatologic conditions, underlying medical conditions, malnutrition, and dehydration. Extrinsic factors include skin dryness, prolonged exposure to moisture, certain medications (i.e., anti-inflammatory agents, anticoagulants, chemotherapeutic agents, long-term corticosteroid use), radiation therapy, photo-damage, improper choice of tape, and repeated taping [5-7]. In case of this patient, she was aged and her skin was very thin and loose. In addition, she was poorly nourished because her remaining teeth were not in good condition. Extrinsic factors which had an effect on her skin injury were improper tape selection and tape removal with excessive force.

According to literature, the types of skin injury include skin stripping, blisters, skin tears, allergic dermatitis, and folliculitis, but the treatment for all these is similar [8]. After an initial assessment to determine the severity of the skin injury, the wound should be cleaned with saline to remove adhesive residue and any source of infection. Afterward, ointment and dressing should be applied to create a moist wound environment to aid in healing. If a skin injury does not respond to conservative management within seven days, it is appropriate to consider consultation with a dermatologist [1]. In this case, secondary healing was complete five days later and local application of antibacterial ointment with a wet dressing was helpful.

In our case, using the strong adhesive surgical tape and its removal with excessive force and not considering the age of the patient, predisposed the patient to skin injury and these were preventable factors. In order to prevent MARSI, it is important to check the age and skin condition of the patient to enable the appropriate adhesive tape choice and ensure adequate care for gentle removal. It is also important to know the patient's general condition and allergy history. If the patient's skin is sensitive, it is better to use silicone tape, which is a weak adhesive [9]. Most adhesive tapes used in anesthetic practice are acrylate based. Silicone tapes have lower surface tension to make rapid contact with the entire skin surface and maintain a constant level of adherence [10]. In addition, we should loosen the edges of the tape and separate the tape from the skin with a gentle force and remove the adhesive product at a low angle and slowly back over itself in the direction of hair growth, keeping it horizontal and close to the skin surface [1,11].

This case report emphasizes the risk of MARSI. There are various risk factors associated with MARSI, but most factors are preventable. The selection, application, and careful removal of the adhesive tape are essential for uncomplicated postoperative care in patients.

### AUTHOR ORCIDS

Tae-Heung Kim: <https://orcid.org/0000-0002-1361-4007>

Jun-Sang Lee: <https://orcid.org/0000-0001-9921-4778>

Ji-Hye Ahn: <https://orcid.org/0000-0001-8811-8465>

Cheul-Hong Kim: <https://orcid.org/0000-0003-1536-9460>

Ji-Uk Yoon: <https://orcid.org/0000-0002-3971-2502>

Eun-Jung Kim: <https://orcid.org/0000-0003-4982-9517>

**ACKNOWLEDGMENTS:** This study was supported by the 2017 Clinical Research Grant, Pusan National University Dental Hospital.

**NOTE:** There are no financial or other issues that might lead to conflict of interest.

## REFERENCES

1. McNichol L, Lund C, Rosen T, Gray M. Medical adhesives and patient safety: state of the science: consensus statements for the assessment, prevention, and treatment of adhesive-related skin injuries. *J Wound Ostomy Continence Nurs* 2013; 32: 267-81.
2. Lober CW, Fenske NA. Cutaneous aging: effect of intrinsic changes on surgical considerations. *South Med J* 1991; 84: 1444-6.
3. Cutting KF. Impact of adhesive surgical tape and wound dressings on the skin, with reference to skin stripping. *J Wound Care* 2008; 17: 157-62.
4. Groom M, Shannon RJ, Chakravarthy D, Fleck CA. An evaluation of costs and effects of a nutrient-based skin care program as a component of prevention of skin tears in an extended convalescent center. *J Wound Ostomy Continence Nurs* 2010; 37: 46-51.
5. LeBlanc K, Baranoski S, Skin Tear Consensus Panel Members. Skin tears: state of the science: consensus statements for the prevention, prediction, assessment, and treatment of skin tears(c). *Adv Skin Wound Care* 2011; 24: 2-15.
6. Conway J, Whettam J. Adverse reactions to wound dressings. *Nurs Stand* 2002; 16: 52-4, 56, 58 passim.
7. Norris P, Storrs FJ. Allergic contact dermatitis to adhesive bandages. *Dermatol Clin* 1990; 8: 147-52.
8. Bryant RA. Types of skin damage and differential diagnosis. In: Bryant R, Nix D, eds. *Acute & Chronic wounds: Current Management Concepts*. 4th ed. St Louis, MO: Elsevier Mosby 2012: 83-107.
9. Zeng LA, Lie SA, Chong SY. Comparison of Medical Adhesive Tapes in Patients at Risk of Facial Skin Trauma under Anesthesia. *Anesthesiol Res Pract* 2016; 2016: 4878246.
10. Grove GL, Zerweck CR, Houser TP, Smith GE, Koski NI. A randomized and controlled comparison of gentleness of 2 medical adhesive tapes in healthy human subjects. *J Wound Ostomy Continence Nurs* 2013; 40: 51-9.
11. LaVelle BE. Reducing the risk of skin trauma related to medical adhesives. *Manag Infect Control* 2004; 182: 1289-94.