

## Endoscopic Findings of Children with Familial Mediterranean Fever

Elif Sağ, Ferhat Demir\*, İsmail Saygın†, Mukaddes Kalyoncu\*, and Murat Çakır

*Department of Pediatric Gastroenterology, Hepatology and Nutrition, \*Department of Pediatric Rheumatology, †Department of Pathology, Faculty of Medicine, Karadeniz Technical University, Trabzon, Turkey*

**Purpose:** Familial Mediterranean fever (FMF) is an auto inflammatory disease characterized by periodic fever, synovitis and serositis. Patients may be admitted to gastroenterology units due to gastrointestinal symptoms. In this study; we aimed to analyze endoscopic findings and diagnostic utility of endoscopic procedure in children with FMF.

**Methods:** Patient with FMF that was performed endoscopy for the gastrointestinal symptoms were included to the study (39 of 164 patients, 53 procedure). A control group was randomly designed as age and gender matched four endoscopic procedures per one endoscopic procedure of patients with FMF (n=212).

**Results:** No different was found between the patients and control group in esophagogastrosopy findings. However, the diagnosis of gastrointestinal pathology was made by esophagogastrosopy in 46.2% patients. Colonoscopic examination revealed that the frequency of inflammatory bowel disease (IBD) was higher in undiagnosed patients compared to both the control group (50.0% vs. 6.9%,  $p < 0.05$ , odds ratio [OR]:13.4 and 95% confidence interval [95% CI]: 2.1-84.3) and the patients under colchicine treatment (50.0% vs. 8.3%,  $p < 0.05$ , OR: 11 and 95% CI: 0.8-147.8). Colonoscopic procedure that was made after the diagnosis was found to provide contribution by 16.7% in determining the etiology of the additional symptoms.

**Conclusion:** Patients with FMF may be admitted to pediatric gastroenterology outpatient clinic prior to diagnosis or during the follow-up period. The frequency of IBD is high in undiagnosed patients with FMF. Endoscopic procedures may be helpful in these patients for the diagnosis accompanying mucosal lesions.

**Key Words:** Familial Mediterranean fever, Gastrosopy, Colonoscopy, Inflammatory bowel diseases

### INTRODUCTION

Familial Mediterranean fever (FMF) is an autosomal recessive, autoinflammatory disease charac-

terized by periodic fever, synovitis, serositis and/or skin manifestations [1]. It was first described in 1997, and shown that mutations in the Mediterranean fever (MEFV) gene, which is found in the short

Received : February 7, 2018, Revised : April 4, 2018, Accepted : April 24, 2018

**Corresponding author:** Murat Çakır, Department of Pediatric Gastroenterology, Hepatology and Nutrition, Faculty of Medicine, Karadeniz Technical University, Trabzon 35100, Turkey. Tel: +90-462377589, Fax: +90-5326810318, E-mail: muratcak@hotmail.com

Copyright © 2018 by The Korean Society of Pediatric Gastroenterology, Hepatology and Nutrition

This is an open-access article distributed under the terms of the Creative Commons Attribution Non-Commercial License (<http://creativecommons.org/licenses/by-nc/4.0/>) which permits unrestricted non-commercial use, distribution, and reproduction in any medium, provided the original work is properly cited.

arm of the 16th chromosome (16p13.3), is responsible for FMF. The disease is frequently seen in Turks, Jews, Armenians, Arabs, and Japanese [2]. More than 70 mutations have been identified in the MEFV gene and the most common mutations is M694V [3]. MEFV, regulates neutrophil activation and consists of 781 amino acids, is a gene responsible for the synthesis of pyrin protein, which has anti-inflammatory features. Pyrin plays a role in the natural immune response, and provides interleukin-1 release, leukocyte apoptosis, and blockage of nuclear factor-kappa B pathway. Excessive secretion of inflammatory cytokines occurs as a result of the failed pyrin protein synthesis due to MEFV mutation. Increased cytokine secretion may effected mucosal surface of the gastrointestinal tract, and patients may present with clinical symptoms due to mucosal erosions [1,4]. One of the main clinical finding of FMF is abdominal pain secondary to peritoneal inflammation, and more than 50% of these patients present to gastroenterology departments before the diagnosis [5]. Intestinal amyloidosis, which is one of the most serious and late complications of the disease develops as a result of deposits of amyloid in the intestinal lamina propria and submucosal veins. It may be asymptomatic as well as manifests as gastrointestinal system (GIS) symptoms such as abdominal pain, dysmotility, diarrhea, pseudo-obstruction, perforation, and malabsorption [6]. In addition, colchicine which is used in the treatment has many GIS side effects including chronic diarrhea, chronic abdominal pain and colitis [7].

The studies in the literature on the endoscopic findings of patients with FMF, which has so widespread gastrointestinal involvement, are not sufficient especially in children. Therefore, we aimed to analyze the clinical and endoscopic findings of FMF patients who underwent endoscopic intervention due to GIS symptoms in our pediatric gastroenterology outpatient clinic. Additionally, we aimed to analyze the diagnostic utility of endoscopic procedure in patients with FMF under colchicine treatment.

## MATERIALS AND METHODS

Patients with FMF, that were underwent endoscopic procedures between January 2010 and December 2017 due to GIS symptoms before or after the diagnosis, were included into the study. Demographic characteristics, laboratory values (complete blood count, C-reactive protein [CRP], erythrocyte sedimentation rate [ESR]), medical treatment, endoscopic and histopathologic findings were recorded, retrospectively. The diagnosis of FMF was made according to the Tel Hashomer criteria by pediatric rheumatologist [8].

Thirty-nine (23.8%) of the 164 FMF patients were underwent 53 endoscopic procedures (21 esophagogastroscope, 4 colonoscopy, and 14 both esophagogastroscope and colonoscopy). Of all patients, 64.1% (n=25) were girls, the mean age at the diagnosis of FMF was  $7.2 \pm 3.7$  years, and the mean age at the time of endoscopy was  $8.2 \pm 4$  years. A total of 13 patients (15 endoscopic procedures; 9 esophagogastroscope, 6 colonoscopies) underwent endoscopy due to GIS symptoms before the diagnosis of FMF. Other 26 patients, who underwent endoscopy after the diagnosis of FMF, were receiving medical therapy colchicine (Colchicum-Dispert; Recordati İlaç; Istanbul, Turkey; 0.03-0.05  $\mu\text{g}/\text{kg}$ ). The demographic characteristics of the patients are shown in Table 1.

Age and gender matched four patients who underwent endoscopic procedure in the pediatric gastroenterology unit were randomly selected as the control subjects for each endoscopic procedure (n=212, 62.1% female, median age of  $8.4 \pm 3.9$  years). Total number of patients who underwent endoscopic procedure between 2010 and 2017 were 6,435 in our pediatric endoscopy unit (after excluding the patients with FMF). Only inclusion criteria was age and gender matching, and exclusion criteria were used.

Detection of endoscopic appearance of reflux esophagitis (Los Angeles classification) and/or histopathological anomaly (papillary elongation, basal cell hyperplasia, increased intraepithelial neutrophil) on the esophagogastroscope examination was considered as reflux esophagitis. In addition, de-

**Table 1.** Demographic Characteristics of Patients with Familial Mediterranean Fever (FMF)

Parameter	Data (n=39)
Sex, female	25 (64.1)
Age for endoscopy (y)	8.2±4.0
Age at FMF diagnosis (y)	7.2±3.7
Frequency of genotype	
Homozygote M694V mutation	2 (5.1)
Other homozygote mutation	1 (2.5)
Double homozygote mutation	3 (7.7)
Compound heterozygote mutation	9 (23.1)
Three heterozygote mutation	4 (10.3)
One homozygote & one heterozygote mutation	1 (2.6)
Heterozygote mutation	16 (41.0)
No mutation	3 (7.7)
Frequency of alleles	
Total number of alleles	67
M694V	24 (35.8)
R202Q	16 (23.9)
V726A	8 (11.9)
M680I	7 (10.4)
E148Q	4 (6.0)
P369S	3 (4.5)
R761H	2 (3.0)
E167D	1 (1.5)
F479L	1 (1.5)
R408Q	1 (1.5)
Total number of procedures	53
Endoscopy	35
Colonoscopy	18
Time of endoscopic intervention*	
Before diagnosis	15/13
After diagnosis	38/26

Values are presented as number (%), mean±standard deviation, or number only.

\*Number of interventions/number of patients.

tection of an abnormal number of eosinophil on the esophageal histopathological examination was considered as esophageal eosinophilia [9]. On the colonoscopic examination; more than 10 lymphoid nodules with a diameter greater than 2 mm were defined as lymphoid nodular hyperplasia (LNH) [10]. The diagnosis of inflammatory bowel disease (IBD) was made according to Porto criteria [11].

Informed verbal and written consent were obtained from the parents before the endoscopic procedure in all patients. The study was retrospective and based on the file records (observational study),

**Table 2.** Indications of Endoscopic Intervention and Laboratory Findings in Patients with FMF Who Underwent Endoscopic Procedures and Control Group

Parameter	FMF patients (n=39)	Control group (n=212)
Esophagogastrosopy		
Number of interventions	35	140
Indication		
Chronic abdominal pain	23 (65.7)	84 (60)
Chronic dyspepsia	6 (17.1)	25 (17.9)
Chronic diarrhea	3 (8.6)	2 (1.4)
Growth retardation	1 (2.9)	1 (0.7)
Anorexia	1 (2.9)	4 (2.9)
Vomiting	1 (2.9)	16 (11.4)
Anemia	1 (2.9)	4 (2.9)
Dysphagia	-	1 (0.7)
Bloody vomiting	-	3 (2.1)
Colonoscopy		
Number of interventions	18	72
Indication		
Chronic abdominal pain	7 (38.9)	16 (22.2)
Chronic diarrhea	4 (22.2)	9 (12.5)
Bloody diarrhea	3 (16.7)	1 (1.4)
Rectal bleeding	3 (16.7)	40 (55.5)
Growth retardation	1 (5.6)	4 (5.6)
Weight loss	-	1 (1.4)
Anemia	-	1 (1.4)
Laboratory finding		
Presence of anemia	21 (39.6) <sup>a</sup>	52 (24.4) <sup>b</sup>
Leukocytosis (>15.000×10 <sup>3</sup> μL)	16 (30.2) <sup>c</sup>	10 (4.7) <sup>d</sup>
Thrombocytosis (>400.000/mm <sup>3</sup> )	19 (35.8) <sup>e</sup>	34 (16) <sup>f</sup>
High CRP (>0.5 g/dL)	23 (43.4) <sup>g</sup>	28 (13.2) <sup>h</sup>
High ESR (>20 mm/hr)	22 (41.5) <sup>j</sup>	13 (6.1) <sup>k</sup>

Values are presented as number only or number (%).

FMF: familial Mediterranean fever, CRP: C-reactive protein, ESR: erythrocyte sedimentation rate.

*p*-value<sup>a-b,c,d,e-f,g-h,j,k</sup> <0.05.

therefore no approval was made to the ethics committee, only written permission was received from the pathology department for to use the results of pathological examination. The study was made in accordance to Helsinki Declaration.

### Statistical analysis

All calculations in our study were performed using the IBM SPSS Statistics, ver. 23.0 (IBM Co, Armonk, NY, USA), and the continuous variables were expressed as mean±standard deviation and catego-

rical variables as percentage (%). Comparison of the quantitative data between the groups was performed using Student *t*-test in the normally distributed variables, and Mann-Whitney test in the non normally distributed variables. Whereas qualitative data were compared using chi-square test. The *p*-values  $\leq 0.05$  were considered statistically significant.

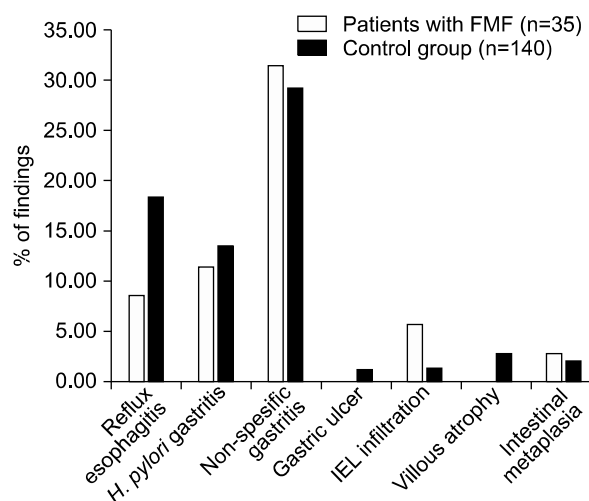
## RESULTS

Indications for endoscopic procedures and laboratory findings of 39 patients (53 procedures) and control group are shown in Table 2. There was no significant difference between the groups in terms of esophagogastrosopy and colonoscopy indications. Pre-procedural anemia and elevated inflammatory markers (leukocytosis, thrombocytosis, CRP, and ESR elevation) were more common in FMF patients ( $p < 0.05$  for all).

When the esophagogastrosopic examinations of the patients were compared with the control group, there was no significant difference in esophageal, gastric and duodenal findings (Fig. 1). Three of 13 patients without any abnormal finding on esophagogastrosopy were diagnosed FMF based on their clinical and laboratory findings on the follow up. Other patients (n=10) were diagnosed FMF based on recurrence of abdominal symptoms in addition to periodic fever despite the treatment of endoscopic pathology. Of the 26 FMF patients who underwent esophagogastrosopy after diagnosis, proton pump inhibitor therapy was administered in seven patients for nonspecific gastritis, and two for reflux eso-

phagitis. Three patients with *Helicobacter pylori* gastritis were treated with tripple eradication regimen. Patients' symptoms improved during the follow-up, and endoscopic procedure was found to provide contribution by 46.2% (12/26 patients) in determining of the etiology of the additional symptoms.

Colonoscopic examination revealed that the frequency of IBD was higher in undiagnosed patients compared to both the control group (50% vs. 6.9%,  $p < 0.05$ , OR:13.4 and 95% CI: 2.1-84.3) and the patients under colchicine treatment (50% vs. 8.3%,  $p < 0.05$ , OR: 11 and 95% CI: 0.8-147.8). No significant difference was found in terms of incidence of LNH and non-specific colitis both in undiagnosed and in patients under treatment compared to controls



**Fig. 1.** Esophagogastrosopic findings of the patients with familial Mediterranean fever (FMF) and control group. IEL: intraepithelial lymphocyte.

**Table 3.** Colonoscopic Examinations of the Patients and Control Group

Colonoscopy finding	Before diagnosis (n=6)	After diagnosis (n=12)	Total (n=18)	Control group (n=72)
LNH	2 (33.3)	3 (25.0)	5 (27.8)	9 (12.5)
IBD	3 (50.0) <sup>a</sup>	1 (8.3) <sup>c</sup>	4 (22.2)	5 (6.9) <sup>b</sup>
Nonspecific colitis	-	1 (8.3)	1 (5.6)	10 (13.9)
Colonic polyp	-	-	-	10 (13.9)
Normal	1 (16.7)	7 (58.3)	8 (44.4)	38 (52.8)

Values are presented as number (%).

LNH: lymphonodular hyperplasia, IBD: inflammatory bowel disease.

*p*-value<sup>a-b,a-c</sup> <0.05 (odds ratio [OR]: 13.4, 95% confidence interval [95% CI]: 2.1-84.3 and OR: 11, 95% CI: 0.8-147.8, respectively).

(Table 3). The diagnosis of IBD was made based on clinical, laboratory and histopathologic findings in three patients in undiagnosed FMF patients. All of them were early onset IBD (ages at the time of first symptoms; 10 days, 4 years, and 4.5 years old), and receiving immunosuppressive therapy, but they were unresponsive to immunosuppressive treatment on the follow-up. Examination for the monogenic disorders revealed homozygous mutation for MEFV in all of them. Immunosuppressive therapy was discontinued and colchicine treatment was initiated. Clinical and laboratory remission were observed during the follow up in all patients. Other patient who was receiving colchicine for FMF, was admitted with bloody diarrhea, and colonoscopic-histopathologic examination revealed ulcerative colitis. Mesalazine was added to the existing treatment. She was on remission during the follow up. Budesonide was initiated for the treatment of the patient with non-specific colitis (n=1). Colonoscopic procedure that was made after the diagnosis was found to provide contribution by 16.7% (2/12 patients) in determining the etiology of the additional symptoms. The patients with LNH were followed up without any medical treatment.

## DISCUSSION

In this study, we investigated the endoscopic findings of pediatric patients with FMF, we found that (i) anemia and elevation in the inflammatory markers were more common in patients with FMF than the control group; (ii) there was no significant difference in esophagogastrosopic findings; (iii) IBD is more common in undiagnosed patients with FMF; and (iv) endoscopic procedure was helpful in determining the additional pathologies and guiding treatment in patients on colchicine treatment.

Studies in the literature about GIS mucosal involvement of FMF in pediatric patients are scarce. Only Gurkan and Dalgic [12] reported the endoscopic findings of the patients with FMF who admitted to the pediatric gastroenterology outpatient clinic. They were reported that colitis and aphthous

bulbitis were common findings in patients with FMF, and these findings were associated with uncontrolled recurrent FMF attacks. Amyloid deposition was not found in any patient. In another study by the same authors, FMF was shown to be one of the most common causes of colonic LNH [13]. In an adult study, endoscopic findings of the patients on colchicine treatment was analyzed and histopathologic changes were found in jejunal biopsies that were compatible with colchicine side effects [7]. In another adult study, esophagogastrosocopy, colonoscopy and small bowel capsule endoscopy were performed in patients under the colchicine treatment. Similar to our study, there was no significant difference in endoscopy findings but an increased amount of mucosal lesions were found in small bowel capsule endoscopy. Approximately half of the patients had mucosal lesions (such as ulcer, erosion) on small bowel capsule endoscopy. Mitotic changes in the lesions were attributed to the colchicine effect rather than autoinflammatory conditions [4].

The association of FMF and IBD has been emphasized more markedly, especially in the studies conducted in recent years. In a study by Beşer et al. [14], IBD was found in 15.4% of 78 FMF patients that were receiving medical treatment. Particularly M694V and K695R mutations were shown to be more frequent in these patients. In studies with larger series, the incidence of IBD was found as 1.16% in FMF patients [15]. On the other hand, in studies conducted in patients with IBD, the incidence of FMF was found between 5% and 25% [14,16]. Salah et al. [17] analyzed the frequency of MEFV mutations in children with IBD and they found that 88% of the IBD patients carried the one of the MEFV mutations and especially common in indeterminate colitis. FMF should be considered in differential diagnosis especially in cases of early-onset and treatment-resistant IBD. The frequency of IBD was found higher in undiagnosed patients than the patients under colchicine treatment in our study, it may be related with anti-inflammatory effect of colchicine that may suppress the IBD related symptoms.

Functional GIS disorders such as diarrhea, con-

stipation, dyspepsia and chronic abdominal pain are commonly observed in patients with FMF. These are encountered both as secondary to medical treatment or complications of FMF [18]. Clinical conditions such as *H. pylori* gastritis, reflux esophagitis and non-specific gastritis may also cause gastrointestinal symptoms in patients with FMF. Although accompanying fever may suggest a FMF episode, inflammatory diseases such as IBD may also cause fever. If the gastrointestinal symptoms are chronic and do not likely with FMF attacks, esophagogastrosopic and colonoscopic procedures should be performed to make the differential diagnosis of all these clinical conditions.

The limitations of our study were (i) detailed histopathological examination may be made, such as analyzing the mitotic activity in detail, may give additional about information colchicine effect; (ii) the lack of small bowel examination (small bowel capsule endoscopy); and (iii) small number of patients may cause type 2 mistakes during the statistical examinations.

In conclusion, we investigated the endoscopic findings of FMF patients, and we thought that FMF has very broad endoscopic findings. FMF should be considered in differential diagnosis in early onset (<5 years) and treatment resistant IBD patients, and endoscopic examination should be performed when patients have chronic gastrointestinal symptoms.

## REFERENCES

1. Wang DQH, Bonfrate L, de Bari O, Wang TY, Portincasa P. Familial Mediterranean fever: from pathogenesis to treatment. *J Genet Syndr Gene Ther* 2014;5:1-11.
2. Kitade T, Horiki N, Katsurahara M, Totoki T, Harada T, Tano S, et al. Usefulness of small intestinal endoscopy in a case of adult-onset familial Mediterranean fever associated with Jejunoileitis. *Intern Med* 2015;54:1343-7.
3. Koshy R, Sivadas A, Scaria V. Genetic epidemiology of familial Mediterranean fever through integrative analysis of whole genome and exome sequences from Middle East and North Africa. *Clin Genet* 2018;93:92-102.
4. Demir A, Akyüz F, Göktürk S, Evirgen S, Akyüz U, Örmeci A, et al. Small bowel mucosal damage in familial Mediterranean fever: results of capsule endoscopy screening. *Scand J Gastroenterol* 2014;49:1414-8.
5. Mor A, Gal R, Livneh A. Abdominal and digestive system associations of familial Mediterranean fever. *Am J Gastroenterol* 2003;98:2594-604.
6. Isomoto H, Kamo Y, Chen CC, Nakao K. Clinical management of gastrointestinal amyloidosis. *Open J Gastroenterol* 2012;2:155-62.
7. Hart J, Lewin KJ, Peters RS, Schwabe AD. Effect of long-term colchicine therapy on jejunal mucosa. *Dig Dis Sci* 1993;38:2017-21.
8. Pras M. Familial Mediterranean fever: from the clinical syndrome to the cloning of the pyrin gene. *Scand J Rheumatol* 1998;27:92-7.
9. Tutar E, Kutluk G, Bayrak NA, Çelikel CA, Pehlivanoglu E, Ertem D. What is the diagnostic utility of endoscopic scoring systems in children? *Turk J Gastroenterol* 2013;24:22-9.
10. Iacono G, Ravelli A, Di Prima L, Scalici C, Bolognini S, Chiappa S, et al. Colonic lymphoid nodular hyperplasia in children: relationship to food hypersensitivity. *Clin Gastroenterol Hepatol* 2007;5:361-6.
11. Levine A, Koletzko S, Turner D, Escher JC, Cucchiara S, de Ridder L, et al; European Society of Pediatric Gastroenterology, Hepatology, and Nutrition. ESPGHAN revised porto criteria for the diagnosis of inflammatory bowel disease in children and adolescents. *J Pediatr Gastroenterol Nutr* 2014;58:795-806.
12. Gurkan OE, Dalgic B. Gastrointestinal mucosal involvement without amyloidosis in children with familial Mediterranean fever. *J Pediatr Gastroenterol Nutr* 2013;57:319-23.
13. Gurkan OE, Yilmaz G, Aksu AU, Demirtas Z, Akyol G, Dalgic B. Colonic lymphoid nodular hyperplasia in childhood: causes of familial Mediterranean fever need extra attention. *J Pediatr Gastroenterol Nutr* 2013;57:817-21.
14. Beşer OF, Kasapçopur O, Cokuğraş FC, Kutlu T, Arsoy N, Erkan T. Association of inflammatory bowel disease with familial Mediterranean fever in Turkish children. *J Pediatr Gastroenterol Nutr* 2013;56:498-502.
15. Özçakar ZB, Çakar N, Uncu N, Çelikel BA, Yalçinkaya F. Familial Mediterranean fever-associated diseases in children. *QJM* 2017;110:287-90.
16. Cakir M, Unal F, Dinler G, Baran M, Yuksekkaya HA, Tumgor G, et al. Inflammatory bowel disease in Turkish children. *World J Pediatr* 2015;11:331-7.
17. Salah S, El-Shabrawi M, Lotfy HM, Shiba HF, Abou-Zekri M, Farag Y. Detection of Mediterranean fever gene mutations in Egyptian children with in-

flammatory bowel disease. Int J Rheum Dis 2016;19:  
806-13.  
18. Brekci E, Celikbilek M, Soytrrk M, Akar S, Brekci H,

Gnaydin I. Functional gastrointestinal disorders in  
patients with familial Mediterranean fever. Int J  
Rheum Dis 2017;20:2101-5.