



후방 발목 충돌 증후군에서의 후족부 내시경 사용: 고식적 방법과 보호 도관을 이용한 방법의 비교

김응수, 이창락*, 김영준*, 노상명*, 박재근[†], 곽희철*, 정선규*

광명새움병원 정형외과, *인제대학교 부산백병원 정형외과, [†]동래봉생병원 정형외과

Hindfoot Endoscopy for the Treatment of Posterior Ankle Impingement Syndrome: A Comparison of Two Methods (a Standard Method versus a Method Using a Protection Cannula)

Eung-Soo Kim, Chang-Rak Lee*, Young-Jun Kim*, Sang-Myung Roh*,
Jae-Keun Park[†], Heui-Chul Gwak*, Sun-Gyu Jung*

Department of Orthopedic Surgery, Gwangmyeong Saeum Hospital, Gwangmyeong,

*Department of Orthopedic Surgery, Inje University Busan Paik Hospital,

[†]Department of Orthopedic Surgery, Dongrae Bongseng Hospital, Busan, Korea

Purpose: The purpose of this study is to compare the clinical results between two different methods of hindfoot endoscopy to treat posterior ankle impingement syndrome.

Materials and Methods: Between January 2008 and January 2014, 52 patients who underwent hindfoot endoscopy were retrospectively reviewed. Two methods of hindfoot endoscopy were used; Group A was treated according to van Dijk and colleagues' standard two-portal method, and group B was treated via the modified version of the above, using a protection cannula. For clinical comparison, the American Orthopaedic Foot and Ankle Society (AOFAS) hindfoot score, time required to return to activity, and the presence of complications were used.

Results: There was no statistically significant difference in the AOFAS scores at the final follow-up, and there was also no statistically significant difference in the times for the scores to return to the preoperative level. There were no permanent neurovascular injuries and wound problems in either group.

Conclusion: Use of protection cannula may provide additional safety during hindfoot endoscopy. We could not prove whether protection cannula can provide superior safety for possible neurovascular injury. Considering the possible safety and risk of using additional instrument, the use of this method may be optional.

Key Words: Hindfoot, Endoscopy, Os trigonum

INTRODUCTION

Posterior ankle pain can result from many causes and may be difficult to diagnose its etiology. Symptomatic posterior ankle impingement syndrome is one of the most common reasons for hindfoot pain and is usually found in athletes and ballet dancers. If conservative treatment is unsuccessful, surgical treatment is considered. The surgical treatment chosen is usually a hindfoot endos-

Received April 13, 2017 Revised October 23, 2017 Accepted November 20, 2017

Corresponding Author: Heui-Chul Gwak

Department of Orthopedic Surgery, Inje University Busan Paik Hospital,
75 Bokji-ro, Busanjin-gu, Busan 47392, Korea

Tel: 82-51-890-6129, Fax: 82-51-890-6619, E-mail: ortho1@hanmail.net

ORCID: <http://orcid.org/0000-0003-1062-0580>

Financial support: None.

Conflict of interest: None.

Copyright ©2018 Korean Foot and Ankle Society. All rights reserved.

© This is an Open Access article distributed under the terms of the Creative Commons Attribution Non-Commercial License (<http://creativecommons.org/licenses/by-nc/4.0>) which permits unrestricted non-commercial use, distribution, and reproduction in any medium, provided the original work is properly cited.

copy. The posterior compartment of the ankle is difficult to reach via the conventional anterior portals, even with the posterolateral portal. However, the conventional posteromedial portal of the ankle is not recommended by several previous reports because of the potential risk of injury to the medial neurovascular bundle and tendinous tissue.¹⁻⁵⁾ In this study, we used a protection cannula for approaching via the posteromedial portal to ensure safety and compared the results with the standard hindfoot endoscopy method.

MATERIALS AND METHODS

1. Patient selection

After obtaining approval from the Institutional Review Board of Inje University Busan Paik Hospital, 52 patients who underwent

hindfoot endoscopy in Gwangmyeong Saeum Hospital and Inje University Busan Paik Hospital between January 2008 and January 2014 were retrospectively reviewed. These patients had a follow-up period of at least 2 years (Fig. 1, 2). The patients with a history of previous surgery of the ipsilateral foot and ankle or an accompanying deformity were excluded. For 6 months, all 52 patients were treated by conservative treatment; anti-inflammatory medications, ultrasonography-guided local injection, removal of strenuous activity, and physical therapy. If there was no relief of the symptoms after 6 months of conservative treatment, a hindfoot endoscopy was done for posterior ankle impingement syndrome. Two methods of hindfoot endoscopy were used for each group, and all surgeries were carried out by one surgeon. Group A (n=25) was treated by van Dijk et al.'s standard two-portal method,⁶⁾ and group B (n=27) was treated by a modification of the method, using a protection cannula. Technical details are provided below.

2. Surgical methods

All the surgeries were performed basically following the same operative technique described by van Dijk et al.'s method.⁶⁾

1) Standard method

The patient is placed in the prone position, and the thigh tourniquet is inflated. The following landmarks are marked; joint line, figure of tendons, and medial and lateral malleolar tips. Then, a 0.5-inch posterolateral skin incision is made for the posterolateral portal at the level or slightly above the tip of the lateral malleolus, just anterolateral to the Achilles tendon. After making a vertical incision, the subcutaneous tissue is split by a mosquito clamp. The mosquito clamp is directed anteriorly, pointing in the direction of the interdigital web space between the first and second toe. When

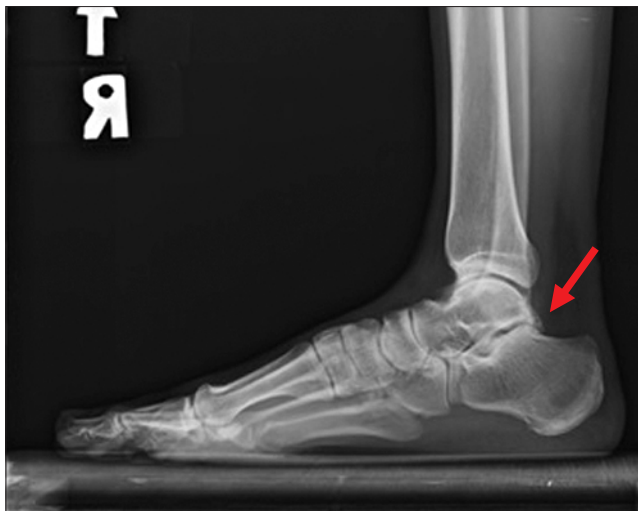


Figure 1. Simple lateral radiograph of ankle revealed osteophyte of posterior aspect of the talus on lateral view (arrow).

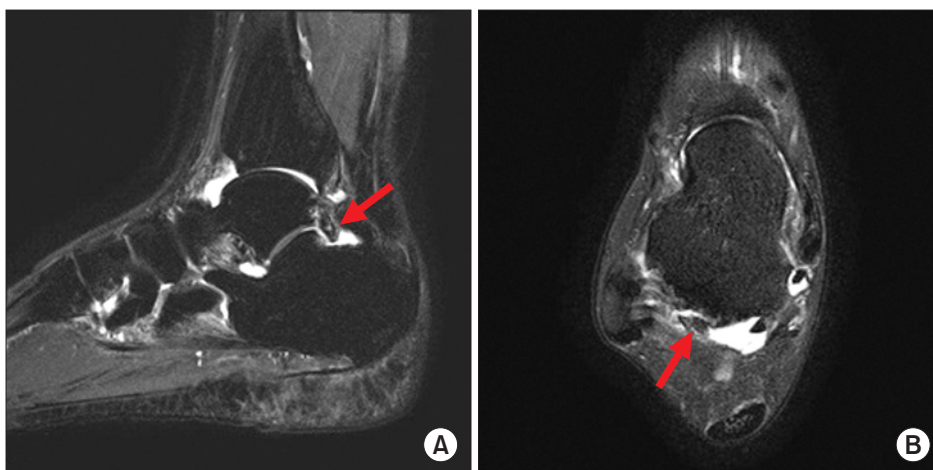


Figure 2. Magnetic resonance images showing prominent osteophyte at posterior aspect of the talus at sagittal view (A; arrow) and at axial view (B; arrow).

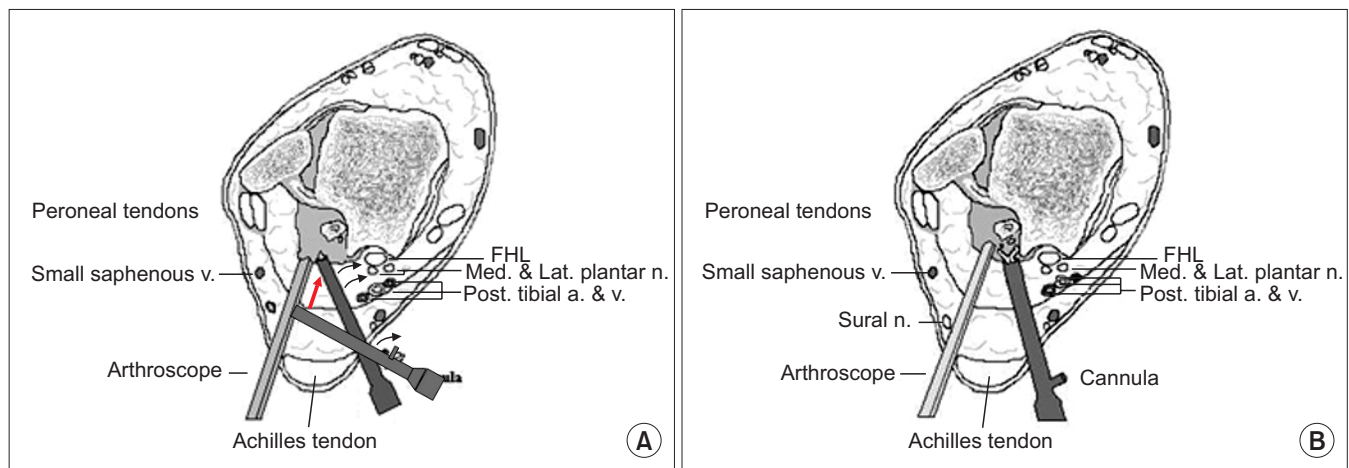


Figure 3. Note the posteromedial cannula inserted for safety (A; arrow), and the cannula can be used for retracting and protecting the surrounding soft tissue, including the neurovascular bundle (B). v.: vein, FHL: flexor hallucis longus tendon, Med.: medial, Lat.: lateral, n.: nerve, Post.: posterior, a.: artery.

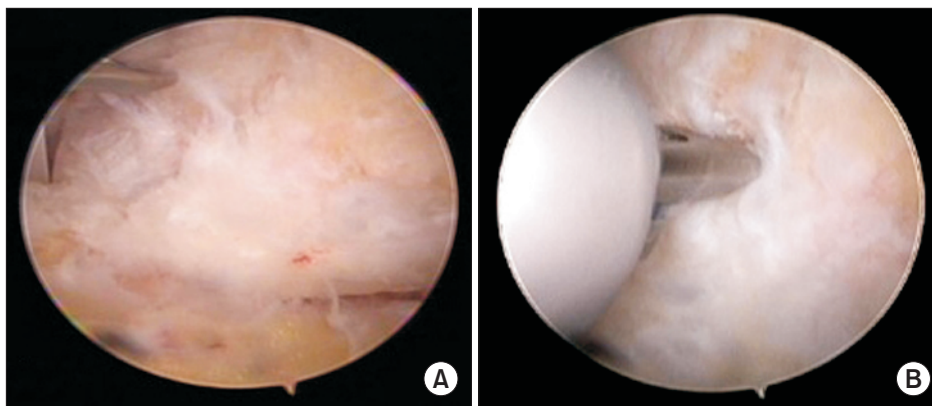


Figure 4. The osteophyte and the loose body were visualized (A) and removed (B) through the posteromedial portal with a protection cannula.

the tip of the clamp touches the bone, it is exchanged for a 2.9-mm arthroscope with a blunt trocar pointing in the same direction. The posteromedial portal is made just medial to the Achilles tendon. After making the skin incision, a mosquito clamp touches the tube of the arthroscope. After the clamp is used to spread the extra-articular soft tissue, the clamp is exchanged for a 4-mm full-radius shaver. The subtalar joint capsule and fatty tissue can be removed. After removal of the capsule of the subtalar joint, the posterior compartment of the subtalar joint can be visualized. The posterior tibiofibular ligament and the posterior talofibular ligament are recognized. The posterior talar process can be freed from scar tissue, and the flexor hallucis longus (FHL) tendon is identified. A shaver, burr, or chisel is used for posterior talar process removal. Instruments are introduced through the posteromedial portal. At this point, the FHL tendon sheath can be approached with the scope, and exploration of the tendon can be performed.

2) A method using a safety cannula for posteromedial portal

Usually, hindfoot endoscopy is performed according to the method of van Dijk et al.⁽⁶⁾ The difference in this second method from van Dijk et al.'s method⁽⁶⁾ applies to the procedure that is performed after making the skin incision at the posteromedial portal. Blunt dissection of the extra-articular soft tissue is done using a mosquito clamp, touching along the tube of the arthroscope. After blunt dissection of the extra-articular soft tissue is done, the mosquito clamp is exchanged for a cannula (Universal Cannula, 5.5 mm [internal diameter] × 70.0 mm; CONMED, Utica, NY, USA). This cannula is used for retracting and protecting the surrounding soft tissue, including the neurovascular bundle (Fig. 3~5).

3. Clinical evaluation

General demographic data were collected (e.g., age, sex, and follow-up period). The American Orthopaedic Foot and Ankle So-

ciety (AOFAS) hindfoot score was recorded during the preoperative period, immediate postoperative period, and every 6 months postoperatively until 2 years of the planned final follow-up period. During the follow-up period, the time to return to activity and the presence of any complication were also recorded.

4. Statistical analysis

All statistical analyses were performed with IBM SPSS Statistics 21.0 (IBM Co., Armonk, NY, USA) and a p-value of less than 0.05 was considered significant.

Mean \pm standard deviations were reported for continuous variables. Preoperative demographic data (e.g., age, sex, and follow-up period) of both groups were compared. The preoperative and postoperative AOFAS scores were compared in each group using a Wilcoxon signed rank test. In addition, the time to return to activity was compared in both groups.

Comparison between the two groups was performed using the

Mann-Whitney U-test. The chi-square test was used for categorical variables. The Wilcoxon signed rank test was used to compare functional scores between the preoperative and final follow-up periods. The time to return to activity and the presence of any complication were also recorded.

RESULTS

1. Preoperative demographics

Preoperative demographic data were as follows. The mean age was 23.8 years (15~45 years) in group A and 33.8 years (17~56 years) in group B. The mean follow-up period was 38.5 months (24~84 months) in group A and 27.7 months (24~42 months) in group B (Table 1).

2. Clinical score

In both groups, each patient's AOFAS score was increased significantly during the postoperative period. The mean AOFAS score at final follow-up was 96 ± 5 in group A and 94 ± 5 in group B (Table 2). There was no significant difference ($p=0.648$). The time to return to activity was 10.9 months (8.3~15.3 months) in group A and 11.3 months (7.5~18.5 months) in group B. There was no

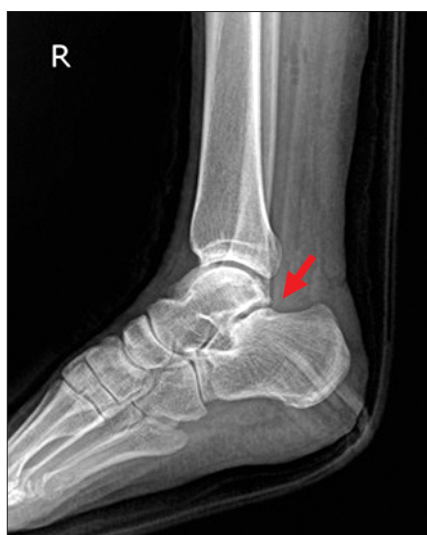

Figure 5. Postoperative radiograph. Osteophyte was removed on lateral view (arrow).

Table 2. The Comparison of the AOFAS Score between the Preoperative and Postoperative Periods in Each Group

	Preoperative period	Postoperative period	p-value
AOFAS in group A (n=25)	61 ± 9	96 ± 5	$<0.0000^*$
AOFAS in group B (n=27)	60 ± 9	94 ± 5	$<0.0000^*$

Values are presented as mean \pm standard deviation.

Group A was treated according to van Dijk et al.'s standard two-portal method,⁽⁶⁾ and group B was treated by a modification of the same method, using a protection cannula.

AOFAS: American Orthopaedic Foot and Ankle Society.

*Wilcoxon signed rank test.

Table 1. Preoperative Demographic Data in Both Groups

	Group A (n=25)	Group B (n=27)	p-value
Age (yr)	23.8 ± 10.5 (15~45)	33.8 ± 14.4 (17~56)	0.0502*
Sex (M:F)	14:11	16:11	0.8139 [†]
Baseline AOFAS score	61 ± 9	60 ± 9	0.3435*
Follow-up period (mo)	38.5 ± 19.3 (24~84)	27.7 ± 5.9 (24~42)	0.0283*

Values are presented as mean \pm standard deviation (range), number only, or mean \pm standard deviation.

Group A was treated according to van Dijk et al.'s standard two-portal method,⁽⁶⁾ and group B was treated by a modification of the same method, using a protection cannula.

M: male, F: female, AOFAS: American Orthopaedic Foot and Ankle Society.

*Mann-Whitney U-test. [†]Chi-square test.

Table 3. The Time to Return to Activity in Both Groups

	Group A (n=25)	Group B (n=27)	p-value
Time (mo)	10.9±2.1 (8.3~15.3)	11.3±3.3 (7.5~18.5)	0.8397*

Values are presented as mean ± standard deviation (range).

Group A was treated according to van Dijk et al.'s standard two-portal method,⁶⁾ and group B was treated by a modification of the same method, using a protection cannula.

*Mann-Whitney U-test.

significant difference ($p=0.8397$) (Table 3).

3. Identified accompanying injuries during endoscopy

Chronic ankle instability was identified in 7 cases in group A and 12 cases in group B.

Accompanying FHL lesions were identified in 8 cases in group A and 10 cases in group B.

4. Complications

There were no permanent vascular injuries and no wound problems in either group. In group A, one patient had a sural nerve problem, but it resolved after 2 months. In group B, one patient had numbness on the medial aspect of the heel, but it resolved after 3 months (Table 4).

DISCUSSION

Surgical treatment for symptomatic posterior ankle impingement syndrome is reserved for failure of conservative management. Surgical treatment of posterior ankle impingement syndrome involves an open posterolateral or posteromedial excision. An arthroscopic approach was also used. Abramowitz et al.⁷⁾ reported on the outcomes of open resections in 41 cases of symptomatic os trigonum. The postoperative AOFAS score averaged 87.6 points. Eight patients had sural nerve sensory loss, which was temporary in four patients and permanent in four patients. A superficial wound infection developed in one patient, and reflex sympathetic dystrophy developed in another. Guo et al.⁸⁾ compared open versus endoscopic excision of symptomatic os trigonum. In this study, 16 patients had an open os trigonum excision, and 25 patients had hindfoot endoscopic surgery. The endoscopic excision group had a significantly shorter mean time to return to previous sports level. There was no difference in the postoperative visual analogue scale score, AOFAS score, subjective satisfaction rating, or rating of sensory nerve loss between the two groups. However, the conven-

Table 4. Postoperative Complications in Both Groups

	Group A (n=25)	Group B (n=27)
Incision anesthesia	0	1
Medial calcaneal neuritis	0	0
Superficial peroneal neuritis	0	0
Sural neuritis	1	0
Sinus tract formation	0	0
Infection	0	0
Superficial	0	0
Deep	0	0
Injection for recurrent symptoms	0	0
Reoperation for recurrent symptoms	0	0

Group A was treated according to van Dijk et al.'s standard two-portal method,⁶⁾ and group B was treated by a modification of the same method, using a protection cannula.

tional arthroscopic posteromedial portal passes between the Achilles tendon and the posteromedial neurovascular bundle. A variety of neurovascular injuries have been reported with the conventional posteromedial portal.^{3,5)} So, the conventional posteromedial portal is seldom used. van Dijk et al.⁶⁾ described the posterior or hindfoot endoscopic portals. These two portals are a modification of the method for establishing the conventional lateral and medial posterior portals of the ankle.^{3,5)} van Dijk et al.⁶⁾ stated that he and his colleagues have performed 86 endoscopic hindfoot procedures without any complications. Some studies have been carried out to find new portals that are relatively safe from neurovascular injury.^{6,9-11)} Jerosch and Fadel²⁾ reported the surgical outcomes of endoscopic excision of symptomatic os trigonum. Of their 10 patients, 9 were symptom free for activities of daily living within 4 weeks after surgery. The average postoperative AOFAS score was 87, and there were no complications in any patients.

A modified posteromedial portal and coaxial portal have been introduced from cadaveric studies. However, some anatomic studies described that the modified posteromedial portal is not completely free from potential neurovascular injury,¹⁰⁾ and the coaxial portal has the risk of posterior tibial tendon injury during instrument passage.⁹⁾

Therefore, we tried some modifications to this technique by using a protection cannula. This technique of posteromedial portal with a cannula also has lower potential risk of injury to the posteromedial neurovascular bundle and allows wide arthroscopic visualization during hindfoot arthroscopy and endoscopy. Our clinical results reflect the safety of the posteromedial portal technique with a protection cannula. There was no incidence of neurovascu-

lar injury in our clinical study. The safety in this procedure may be secured by maintaining passage after the initial portal making and may lead to a reduced risk of neurovascular injury. Thus, if given attention at the initial portal making, a hindfoot endoscopy using this method may lead to good, safe clinical result.

There are several limitations in this study. First, we tried to find relative safety or possible superiority of the modified method in this study; however, there were no clinically significant difference between both groups. Thus we still could “assume” that protection cannula may provide more safe instrument passage than classic method. Second, there is a possible problem of using additional, larger instrument. The use of protection cannula could provide additional safety, but at the same time, thickness of the cannula (5.5 mm [internal diameter]) also may be related to complication.

CONCLUSION

A use of protection cannula does not provide additional safety for possible neurovascular injury during hindfoot endoscopy. Considering possible safety and risk of using additional instrument, the use of this method would be optional.

REFERENCES

1. Stone JW, Guhl JF. *Diagnostic arthroscopy of the ankle*. In: Andrews JR, Tinnerman LA, editors. *Diagnostic and operative arthroscopy*. Philadelphia: WB Saunders; 1997. p.423-30.
2. Jerosch J, Fadel M. Endoscopic resection of a symptomatic os trigonum. *Knee Surg Sports Traumatol Arthrosc*. 2006;14:1188-93.
3. Golanó P, Vega J, Pérez-Carro L, Götzens V. Ankle anatomy for the arthroscope. Part I: the portals. *Foot Ankle Clin*. 2006;11:253-73.
4. Ferkel RD, Scranton PE Jr. Arthroscopy of the ankle and foot. *J Bone Joint Surg Am*. 1993;75:1233-42.
5. Ferkel RD, Heath DD, Guhl JF. Neurological complications of ankle arthroscopy. *Arthroscopy*. 1996;12:200-8.
6. van Dijk CN, Scholten PE, Krips R. A 2-portal endoscopic approach for diagnosis and treatment of posterior ankle pathology. *Arthroscopy*. 2000;16:871-6.
7. Abramowitz Y, Wollstein R, Barzilay Y, London E, Matan Y, Shabat S, et al. Outcome of resection of a symptomatic os trigonum. *J Bone Joint Surg Am*. 2003;85:1051-7.
8. Guo QW, Hu YL, Jiao C, Ao YF, Tian DX. Open versus endoscopic excision of a symptomatic os trigonum: a comparative study of 41 cases. *Arthroscopy*. 2010;26:384-90.
9. van Dijk CN. Hindfoot endoscopy. *Foot Ankle Clin*. 2006;11:391-414.
10. van Dijk CN. Hindfoot endoscopy for posterior ankle pain. *Instr Course Lect*. 2006;55:545-54.
11. Acevedo JI, Busch MT, Ganey TM, Hutton WC, Ogden JA. Coaxial portals for posterior ankle arthroscopy: an anatomic study with clinical correlation on 29 patients. *Arthroscopy*. 2000;16:836-42.