

Case Report



A Case of Plastic Bronchitis Associated Influenza A Pneumonia Requiring ECMO Assistance

Hong Yul An ,¹ Seung Min Baek,¹ Youn Young Choi,¹ You sun Kim,¹ Eui Jun Lee,¹ Yu Hyeon Choi,¹ Yun Jung Choi,¹ Dong In Suh,¹ Jae Gun Kwak,² Woong-Han Kim,² June Dong Park ¹

¹Department of Pediatrics, Seoul National University College of Medicine, Seoul, the Republic of Korea

²Department of Thoracic and Cardiovascular Surgery, Seoul National University College of Medicine, Seoul, the Republic of Korea

OPEN ACCESS

Received: Sep 15, 2017

Revised: Oct 3, 2017

Accepted: Oct 14, 2017

Correspondence to

June Dong Park

Division of Intensive Care, Department of Pediatrics, Seoul National University College of Medicine, 101 Daehak-ro, Jongno-gu, Seoul 03080, the Republic of Korea.
E-mail: jdparkmd@snu.ac.kr

Copyright © 2018 The Korean Society of Pediatric Infectious Diseases

This is an Open Access article distributed under the terms of the Creative Commons Attribution Non-Commercial License (<https://creativecommons.org/licenses/by-nc/4.0/>) which permits unrestricted non-commercial use, distribution, and reproduction in any medium, provided the original work is properly cited.

ORCID iDs

Hong Yul An

<https://orcid.org/0000-0003-1083-4589>

June Dong Park

<https://orcid.org/0000-0001-8113-1384>

Conflict of Interest

No potential conflict of interest relevant to this article was reported.

ABSTRACT

A 6-year-old boy with underlying hemolytic anemia of unknown etiology, atopic dermatitis, and recurrent urticaria visited our hospital because of acute respiratory failure induced by influenza A. Despite mechanical ventilation after endotracheal intubation along with inhalation of nitric oxide, respiratory acidosis and hypoxemia persisted. Veno-venous extracorporeal membrane oxygenation (VV ECMO) insertion was performed to provide respiratory support. After performing flexible bronchoscopy, we found that thick mucus plugs were obstructing the right bronchus intermedius and the upper lobe orifice. After bronchial washing and removal of the plugs, we were able to wean the patient off VV ECMO and transfer him to the general ward. He was discharged without any neurologic or pulmonary sequelae.

Keywords: Bronchitis; Mucus; Influenza A virus; Extracorporeal membrane oxygenation; Bronchoscopy

INTRODUCTION

Plastic bronchitis has previously been referred to as fibrinous bronchitis, cast bronchitis, Hoffman bronchitis, and pseudomembranous bronchitis. The main pathogenesis of this disease is the presence of obstructive mucus plugs in the bronchus that do not resolve by themselves. In plastic bronchitis, mucus plugs interfere with air flow and block the bronchial tubes, inducing acute respiratory insufficiency. This condition was first identified as bronchial wrinkles by Galen in the 2nd century. The first case of plastic bronchitis in published literature was described in an autopsy report of a person who died of pneumonia or croup in 1899.^{1,2)} Plastic bronchitis can be caused by several factors, such as congenital heart disease, allergy, sickle cell disease, and cystic fibrosis. It has also been reported in infectious diseases such as influenza virus in children.³⁾ Pathologically, it is divided into type I and type II, depending on the presence or absence of inflammatory cells, and can be classified based on the underlying diseases. Type I is known as the inflammatory type. Type I bronchial casts are formed when there is an inflammatory response, infectious disease, and allergic reaction. On the other hand, type II bronchial casts have mucinous

Author Contributions

Conceptualization: Park JD, Lee EJ, Choi YH, Choi YJ, Suh DI, Kwak JG, Kim WH; Data curation: An HY; Formal analysis: An HY; Investigation: An HY, Baek SM, Choi YY, Kim YS; Project administration: Park JD; Supervision: Park JD; Validation: Park JD; Visualization: An HY; Writing - original draft: An HY; Writing - review & editing: Park JD.

components. Type II plastic bronchitis is usually observed in patients with underlying cardiac diseases.⁴⁾ Plastic bronchitis is a very rare disease, with fewer than 1,000 cases reported worldwide so far, and therefore, the prevalence of this disease according to age is unknown. It is known to predominantly occur in women, but the cause of this female predominance is not known.⁵⁾

CASE

A 6-year-old boy visited emergency room of Seoul National University Children's Hospital during winter, complaining of respiratory difficulty. When he was an infant, he developed macrocytic hypochromic anemia. At that time, it was suspected that the anemia was due to a drug allergy. We tried to determine the cause of the patient's anemia but found no apparent cause, and the anemia spontaneously recovered. He subsequently suffered from atopic dermatitis and egg allergy, but he was lost to follow-up.

Three days before visiting the emergency room, the patient had a cough with sputum and a body temperature of 37.8°C. Within a day, his symptoms aggravated and he had difficulty in breathing. He was unable to sleep because of the cough. His parents also recently had a respiratory infection. When he arrived at the emergency room, the pulse oximetry was 68%. His blood pressure was 108/67 mmHg, pulse rate was 154 beats/min, respiratory rate was 52 breaths/min, and the body temperature was 37.4°C. Crackles and wheezing were audible in both lung fields. The lung sound of the right lung was weaker than that of the left lung.

Oxygen (15 L/min) was supplied via a facial mask with a reservoir bag, but the oxygen saturation did not rise above 70%. The white blood cell count was 32,280 cells/ μ L, of which 89.1% were segmented neutrophils and 4.5% were lymphocytes. Hemoglobin level was 12.4 g/dL. The platelet count was 526,000/ μ L. The level of C-reactive protein in blood was 3.16 mg/dL. His arterial blood gas analysis revealed that blood pH was 7.14; pCO₂ was 63 mmHg, pO₂ was 46 mmHg; and oxygen index was 35. Endotracheal intubation was performed immediately, and he was transferred to the pediatric emergency intensive care unit. The initial chest radiograph showed that the patient's right lung was totally collapsed (**Fig. 1A**). Endotracheal tube adjustment and massive pulmonary physiotherapy were performed. The mechanical ventilator was adjusted to a higher setting which included an FiO₂ of 1.0, and empirical antibiotics (piperacillin/tazobactam, vancomycin) were administered. Oseltamivir was also administered because the patient fell ill during the flu epidemic season. Inhalation of nitric oxide was started. However, respiratory acidosis, hypercapnia, and hypoxemia remained persistent, with the arterial blood gas analysis showing that the blood pH was 7.09, pCO₂ was 86 mmHg, pO₂ was 45 mmHg, and oxygenation index was 40. Thus, we performed veno-venous (from the right femoral to the right internal jugular vein) extracorporeal membrane oxygenation (VV ECMO) within 9 hours of the patient's emergency room arrival. Three hours after ECMO insertion, we performed flexible bronchoscopy. We found that thick mucus plugs were obstructing the right bronchus intermedius and upper lobe orifice (**Fig. 2**). After removal of the thick mucus plugs, the right lung could be ventilated, and the tracheal deviation decreased, as observed using a chest radiograph (**Fig. 1B**). The endotracheal aspiration samples tested negative on the flu rapid antigen test and the respiratory syncytial virus rapid antigen test. However, real-time multiplex polymerase chain reaction (PCR) detected the presence of influenza A virus in

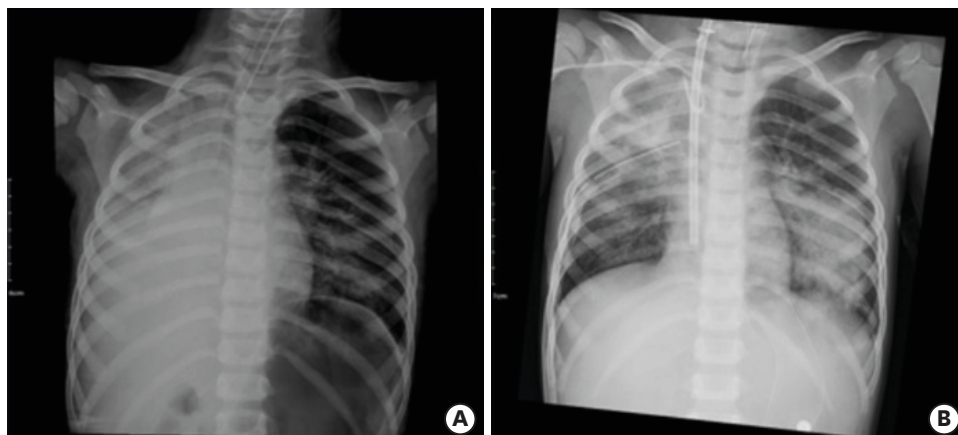


Fig. 1. (A) Initial status of plastic bronchitis; initial chest radiograph showed that the 6-year-old patient's right lung was totally collapsed. (B) Status of plastic bronchitis after bronchoalveolar lavage; after removal of the thick mucus plugs, the right lung could be ventilated, and the tracheal deviation decreased. Infiltration of the left lower lung was present.

the endotracheal aspiration. There was no bacterial growth in blood, endotracheal and bronchoalveolar lavage cultures. The *Mycoplasma pneumoniae* antibody titer was 1:640, but PCR did not detect the presence of *M. pneumoniae* in endotracheal aspiration and bronchoalveolar lavage fluid. After 4 days, we could decrease the FiO_2 to 0.3 on the ventilator settings, and the oxygenation index was lower than 10 (**Fig. 3**). We performed washing via bronchoscopy 2 more times due to persistent right upper lobe atelectasis. We stopped the VV ECMO on hospital day 6. The patient could breathe without a ventilator on hospital day 11, and was discharged without any sequelae on hospital day 19. After discharge, he was able to breathe normally and is currently undergoing regular follow-up.

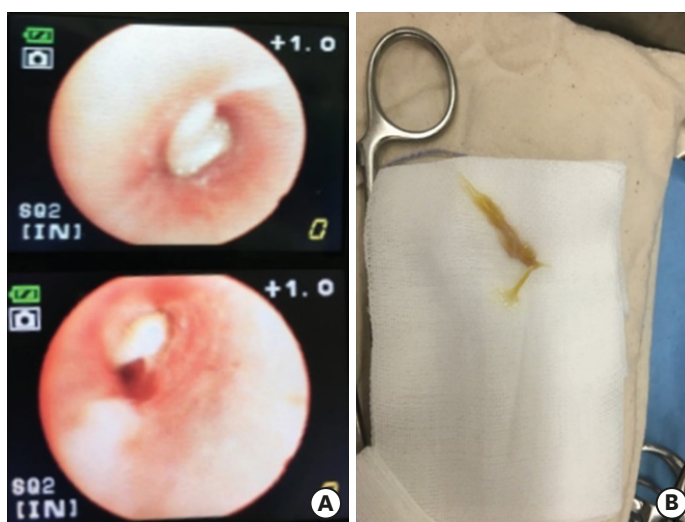


Fig. 2. (A) Findings of flexible bronchoscopy; yellowish and thick mucus plugs were observed at the opening of the right main bronchus. (B) Removal of thick mucus using flexible bronchoscopy; the size of mucus plugs was about 3.5 cm.

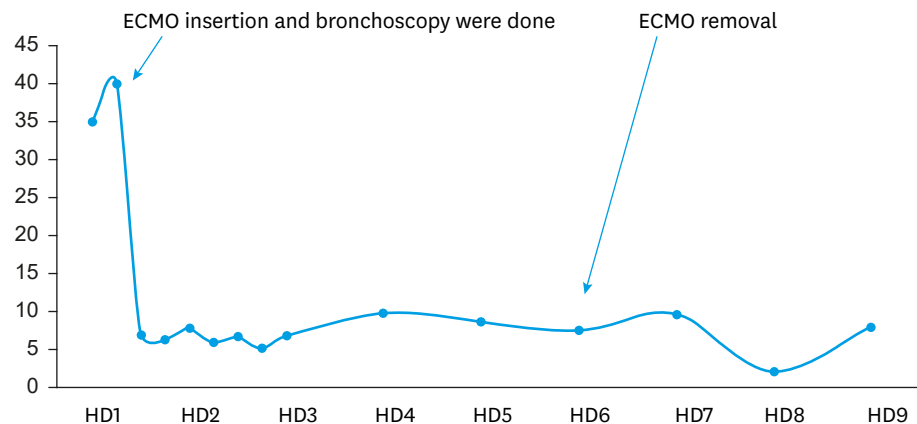


Fig. 3. Oxygenation index graph status during the days of hospital stay.
Abbreviations: ECMO, extracorporeal membrane oxygenation; HD, hospital day.

DISCUSSION

Usual symptoms of plastic bronchitis are dyspnea, cough, fever, chest pain, and hemoptysis, and these symptoms may not be distinguishable from those of other diseases, such as pneumonia, status asthmaticus, or foreign body aspiration.⁶⁾ On imaging, routine chest radiographs of patients with plastic bronchitis can show atelectasis or compensatory hyperinflation. Pneumomediastinum and emphysema are common to radiographic findings for this group of diseases. Urgent bronchoscopy is very important for the diagnosis and treatment of plastic bronchitis because it cannot be easily distinguished from other diseases. Ultimately, urgent removal of the mucus plugs using bronchoscopy is crucial, but it should be performed while providing a supplement of oxygenation. This is to avoid the risk of hypoxic ischemic encephalopathy due to the hypoxemia before and after the procedure. In order to prevent hypoxic damage, we perform ECMO on patients before the bronchoscopy procedure.⁷⁾

Most influenza infections in children improve spontaneously over time, but in some patients, they lead to neurological or pulmonary sequelae because of severe pneumonia or encephalitis.⁸⁾ Recently, several papers on influenza and plastic bronchitis in children have been published.^{9,11)} In particular, a paper from a single center in China reported that 2 out of 14 patients died from hypoxia due to plastic bronchitis and multiple organ failure associated with it between 2009 and 2014.¹¹⁾ In another study, influenza B, which is known to be more infectious than influenza A, was reported to cause plastic bronchitis.¹⁰⁾

The patient described in the present case report was not diagnosed with asthma but had allergic diseases, such as atopic dermatitis and recurrent urticaria. It is possible that the patient's susceptibility to allergies influenced the development of plastic bronchitis. Several plastic bronchitis cases are associated with asthma; however, there is controversy about the inclusion of plastic bronchitis in the asthma spectrum and severe asthma or secretory hyper-responsiveness.¹²⁾

In the present case, immediate respiratory support was achieved, and emergent bronchoscopy enabled early discharge without sequelae. The most important treatment for plastic bronchitis is to remove the plugs using bronchoscopy. Rigid bronchoscopy is needed

if the plugs cannot be removed by flexible bronchoscopy.¹³⁾ In some cases, the treatment of an underlying disease that can cause plastic bronchitis is important. If there is a problem in the circulation of the lymphatics, interventions, such as embolization or duct ligation may be required.^{14,15)} Viral infection is often associated with plastic bronchitis, and therefore antiviral agents can be helpful, such as in our case. Although the association between bacterial infection and plastic bronchitis is low, there are reports that plastic bronchitis can cause a tracheoesophageal fistula.¹⁶⁾ In such cases, appropriate antimicrobial agents that the bacteria are susceptible to should be administered. Supportive care, including inhaled steroids, bronchodilators, mucolytics, inhaled heparin or tissue plasminogen activator, and dornase alfa may also be used, but their effectiveness are unclear.³⁾ Consequently, we think that removing the mucus plugs emergently and preventing the worsening of hypoxemia during the procedure can improve the prognosis of patients with plastic bronchitis.

REFERENCES

1. Oliver T. Remarks on plastic or croupous bronchitis. *BMJ* 1899;2:69-72.
[PUBMED](#) | [CROSSREF](#)
2. Werkhaven J, Holinger LD. Bronchial casts in children. *Ann Otol Rhinol Laryngol* 1987;96:86-92.
[PUBMED](#) | [CROSSREF](#)
3. Rubin BK. Plastic bronchitis. *Clin Chest Med* 2016;37:405-8.
[PUBMED](#) | [CROSSREF](#)
4. Panchabhai TS, Mukhopadhyay S, Sehgal S, Bandyopadhyay D, Erzurum SC, Mehta AC. Plugs of the air passages: a clinicopathologic review. *Chest* 2016;150:1141-57.
[PUBMED](#) | [CROSSREF](#)
5. Eberlein MH, Drummond MB, Haponik EF. Plastic bronchitis: a management challenge. *Am J Med Sci* 2008;335:163-9.
[PUBMED](#) | [CROSSREF](#)
6. Ding XF, Zhong LL, Zhang B, Lin L, Huang H, Liang M. Clinical features and pathogens of plastic bronchitis in children: an analysis of 9 cases. *Zhongguo Dang Dai Er Ke Za Zhi* 2014;16:729-33.
[PUBMED](#)
7. Colt HG, Matsuo T. Hospital charges attributable to bronchoscopy-related complications in outpatients. *Respiration* 2001;68:67-72.
[PUBMED](#) | [CROSSREF](#)
8. Frobert E, Sarret C, Billaud G, Gillet Y, Escuret V, Floret D, et al. Pediatric neurological complications associated with the A(H1N1)pdm09 influenza infection. *J Clin Virol* 2011;52:307-13.
[PUBMED](#) | [CROSSREF](#)
9. Kim S, Cho HJ, Han DK, Choi YD, Yang ES, Cho YK, et al. Recurrent plastic bronchitis in a child with 2009 influenza A (H1N1) and influenza B virus infection. *J Korean Med Sci* 2012;27:1114-9.
[PUBMED](#) | [CROSSREF](#)
10. Nogan SJ, Cass ND, Wiet GJ, Ruda JM. Plastic bronchitis arising from solitary influenza B infection: a report of two cases in children. *Int J Pediatr Otorhinolaryngol* 2015;79:1140-4.
[PUBMED](#) | [CROSSREF](#)
11. Zhang J, Kang X. Plastic bronchitis associated with influenza virus infection in children: a report on 14 cases. *Int J Pediatr Otorhinolaryngol* 2015;79:481-6.
[PUBMED](#) | [CROSSREF](#)
12. Turgut T, In E, Özeran IH, Kaplan M. A case of plastic bronchitis. *Arch Iran Med* 2014;17:589-90.
[PUBMED](#)
13. Soyer T, Yalcin Ş, Emiralioğlu N, Yılmaz EA, Soyer O, Orhan D, et al. Use of serial rigid bronchoscopy in the treatment of plastic bronchitis in children. *J Pediatr Surg* 2016;51:1640-3.
[PUBMED](#) | [CROSSREF](#)
14. Ugaki S, Lord DJ, Sherwood MC, Winlaw DS. Lymphangiography is a diagnostic and therapeutic intervention for patients with plastic bronchitis after the Fontan operation. *J Thorac Cardiovasc Surg* 2016;152:e47-9.
[PUBMED](#) | [CROSSREF](#)

15. Hess NR, Piercecchi C, Desai N, Fisher MR, Lee EH, Force SD. Successful thoracic duct ligation for plastic bronchitis in an adult. *Ann Thorac Surg* 2017;103:e539-40.
[PUBMED](#) | [CROSSREF](#)
16. Garcia-Henriquez N, Toloza EM, Khalil F, Echavarría MF, Garrett JR, Moodie CC, et al. Extensive plastic bronchitis: etiology of a rare condition. *J Thorac Dis* 2016;8:E961-5.
[PUBMED](#) | [CROSSREF](#)

요약

6세 남아가 인플루엔자 A 바이러스 감염 이후 급성 호흡부전 상태에서 내원하였다. 기관 삽관 이후 인공 호흡 및 산화 질소 공급에도 호흡성 산증 및 저산소증의 호전이 없어 내원 9시간 이후 체외막 산소 공급을 이용하여 호흡 보조를 시행하였다. 내원 12시간 이후 기관지경을 이용하여 우측 중간 기관지부터 상엽 구멍을 막고 있는 단단한 점액 막개를 제거하였다. 이후 환자는 신경계와 호흡기계 후유증 없이 퇴원하였다. 저자들은 플라스틱 기관지염으로 인한 급성 호흡 부전 상태의 환자에서 신속한 체외막 산소 공급 및 기관지경술의 처치를 시행함으로써 후유증 없이 치료한 사례를 보고한다.