

<Case Report>

## Idiopathic type-4 hiatal hernia in a middle-aged cat

Gi-Na Kim<sup>1,2</sup>, Soon-Wuk Jeong<sup>1,2</sup>, Hun-Young Yoon<sup>2</sup>, Hyun-Jung Han<sup>1,\*</sup>

*Departments of <sup>1</sup>Veterinary Emergency Medicine, and <sup>2</sup>Veterinary Surgery, Konkuk Veterinary Medical Teaching Hospital, Konkuk University, Seoul 05029, Korea*

(Received: February 19, 2018; Revised: April 9, 2018; Accepted: May 9, 2018)

**Abstract:** A 6-year-old female domestic short hair cat presented with acute onset of vomiting, anorexia, lethargy, and tachypnea. The cat was apparently healthy prior to presentation without history of trauma. On diagnostic imagings, the entire stomach and spleen were detected in the thoracic cavity. An emergent celiotomy was performed, and a type-4 hiatal hernia was confirmed; the stomach, spleen, pancreas, and duodenum were herniated through the esophageal hiatus. It was corrected using phrenicoplasty, esophagopexy, and left-sided gastropexy and there was no recurrence 16 months after surgery. This is the first case report of an idiopathic type-4 hiatal hernia in a cat.

**Keywords:** cats, phrenico-esophageal ligament, type-4 hiatal hernia

In small animals, a hiatal hernia is traditionally classified as one of three types depending on the shape of gastric herniation; sliding (type-1), para-esophageal (type-2) and combination of type-1 and 2 (type-3) [10]. In humans, a type-4 hernia is also classified and is defined as the massive herniation of other abdominal organs such as the spleen, pancreas, and intestines due to a defect in the phrenico-esophageal ligament [9]. Hernias similar to type-4 have rarely been reported in veterinary fields; three reports exist, which include two cats and one dog, and all reported cases were congenital hernias [2, 11, 13].

This study describes a type-4 hiatal hernia in a middle-aged cat. The stomach, spleen, pancreas, and duodenum were acutely herniated through the hiatus. It was considered an idiopathic hernia because the cat was middle-aged and apparently healthy, until the hernia occurred, and no history or cause of hernia was found. To the authors' knowledge, this is the first case report describing an idiopathic type-4 hiatal hernia in a healthy, middle-aged cat.

A 6-year-old female domestic short hair cat weighing 4.2 kg was presented with one-day history of acute vomiting, anorexia, lethargy, and tachypnea with a respiratory rate of 84 breaths per min. The cat was apparently healthy prior to presentation and had no history of previous illnesses or trauma. Thoracic auscultation revealed muffled heart sounds on the right thorax with no abnormal respiratory sounds. Diagnostic imaging revealed severely distended stomach surrounded by soft tissue in the right hemithorax (Fig. 1). On thoracic radiographs, the heart and mediastinum were dis-

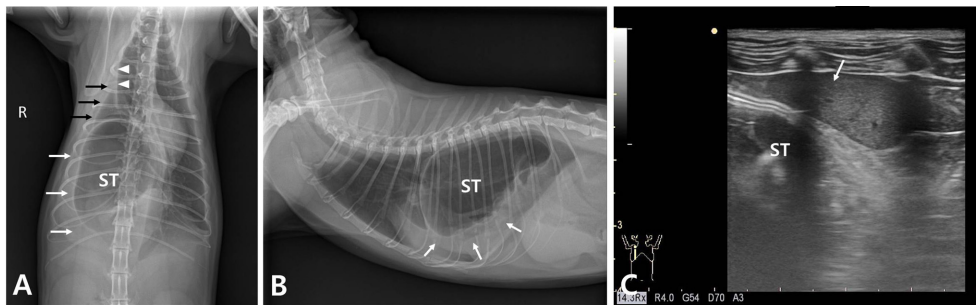
placed to the left, and the right middle lung lobe appeared to be slightly retracted from the thoracic wall. Mild thoracic pleural effusion was observed in the right thorax. Ultrasound examination also confirmed all parts of the stomach surrounded by spleen in the thoracic cavity and the pancreas was not detected in the abdominal cavity. Routine hematology and serum biochemistry revealed no abnormalities except for increase in creatinine kinase: 418 U/L (U/L, international units per liter; reference range 10 to 200 U/L) and hyperlactatemia: 6.97 mg/dL (reference range 0.5 to 2.5 mg/dL).

On the basis of diagnostic findings, a diaphragmatic hernia or hiatal hernia with herniation of the entire stomach was suspected and an emergent celiotomy was performed. After the cranial ventral midline abdominal incision, a hiatal hernia was confirmed. The stomach, spleen, duodenum, and pancreas were not observed in the abdominal cavity; only the distal section of the descending duodenum and the omentum entering the hiatus were observed. The herniated organs were reduced by gentle traction without any extension of the defect (Fig. 2A). The spleen and pancreas were hyperemic and locally discolored as signs of congestion (Fig. 2B). The stomach and duodenum appeared grossly normal with no signs of devitalisation. The hernia ring was examined; the defect was located on the left dorsal side of the esophagus and surrounded by the thin, severely loosened phrenico-esophageal ligament, but the gastro-esophageal junction was in the normal position (Fig. 2C). The hiatal hernia was corrected by phrenicoplasty, esophagopexy, and left-sided fundic gastropexy (Fig. 2D-F). After preserving the vagal trunks

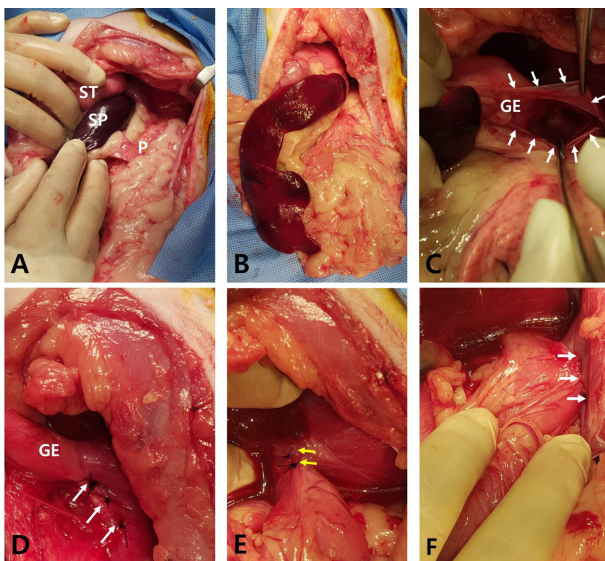
\*Corresponding author

Tel: +82-2-450-3664, Fax: +82-2-444-4396

E-mail: ab1234@konkuk.ac.kr



**Fig. 1.** Plain thoracic radiographs of ventrodorsal (A) and right lateral view (B), and ultrasonograph (C) showing the distended stomach (ST) surrounded by spleen (white arrows) in the right caudal thorax. The herniated stomach and spleen displaces the heart and mediastinum to the left. The right middle lung lobe retracts slightly from the thoracic wall (black arrows), and the interlobar fissure line is observed in the right thorax (white arrowheads).



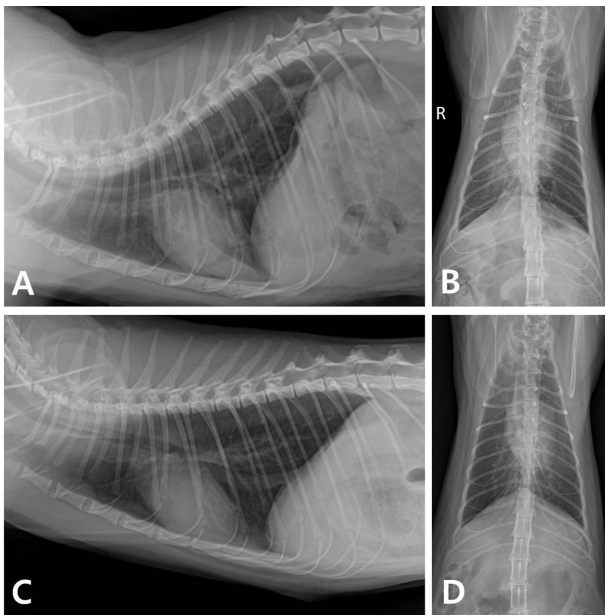
**Fig. 2.** Surgical correction of a type-4 hiatal hernia in this cat. (A–C) Intraoperative views of a type-4 hiatal hernia; (A) Herniated organs including the ST, spleen (SP), pancreas (P), and proximal duodenum are reduced into the abdominal cavity with gentle traction. (B) The SP and P are hyperemic, represented by patchy discoloration. (C) The hernia ring is located dorso-left lateral to the esophagus and the thin, loosened phrenico-esophageal ligament surrounds the defect (arrows). The gastro-esophageal junction (GE) is in a normal position. (D–F) Phrenicoplasty, esophagopexy, and left-sided gastropexy are performed to correct the hiatal hernia. (D) Phrenicoplasty: the hiatal defect is narrowed by diaphragmatic plication with three horizontal mattress sutures between the left and right crus located dorsal to the esophagus (white arrows). The GE is normally located in the abdominal cavity. (E) Esophagopexy: the abdominal esophagus is sutured to the diaphragm with simple interrupted sutures (yellow arrows). (F) Left-sided gastropexy: an incisional gastropexy is performed between the fundus and the left side of the abdominal wall (thick arrows).

and esophageal vessels, the diaphragmatic muscle around the hernia ring was plicated with three horizontal mattress sutures of 3-0 polydioxanone (PDS Plus; Ethicon, USA). Gastric car-

dia patency was confirmed via passage of one finger through the narrowed hiatal ring and passage the 12-Fr orogastric tube. Esophagopexy and a left-sided incisional gastropexy were performed with 3-0 PDS in a routine fashion. After hiatal herniorrhaphy, intrathoracic air evacuation was not performed in the cat because diaphragmatic movement was normal throughout the surgery.

The cat recovered from anesthesia without complications. Maropitant (Cerenia; Zoetis, USA) 1 mg/kg SC q24h, famotidine (Gaster inj.; Dong-A Pharmaceutical, Korea) 0.5 mg/kg IV q12h, and butorphanol (Butophan inj.; Myungmoon Pharm, Korea) 0.1 mg/kg/min continuous rate infusion for 12 h were administered postoperatively. The cat was stabilized immediately after surgery; the respiration rate was 36 breaths per min with normal vital signs. The following day, the cat was fed a liquid diet, and no regurgitation or vomiting was observed after feeding. The appetite improved gradually, and the cat was discharged three days after surgery. The postoperative radiographs showed all herniated organs re-positioned in the abdominal cavity with an intact diaphragm (Fig. 3). At 16 months follow-up appointment, the cat was still in good condition, without any symptoms.

Unlike humans, the definition of a type-4 hiatal hernia is still ambiguous in small animals [11, 12]. Several veterinary reports have defined the type-4 hernia as a complex type-3 hiatal hernia; therefore, they designated type-4 only if the patient had both a type-1 and a type-2 hernia with hiatal herniation of other abdominal organs [11-13]. In those reports, if the patient did not have a type-1 hernia representing the normal position of the gastro-esophageal junction, it was regarded as a type-2 hernia even though there was massive hiatal herniation of other abdominal organs [2, 13]. Similar to the human literature, we defined this cat as a type-4 hiatal hernia without focusing on the existence of a type-1 hernia. We considered that massive hiatal herniation of other abdominal organs should be classified separately from other types of hiatal hernia, as it should be treated the most urgently due to the higher risk of fatal complications such as respiratory compromise and organ strangulation.



**Fig. 3.** Postoperative radiographs showing the reduction of all herniated organs with an intact diaphragm. (A) and (B) On radiographs taken immediately after surgery, pleural effusion and pulmonary infiltration in the right caudal lung lobe were detected. (C) and (D) On radiographs taken 3 days after surgery, there was no remarkable finding without pleural effusion and pulmonary infiltration.

In small animals, congenital hiatal hernia is more common [1, 7]. In particular, all of the cases of type-4 hiatal hernia were diagnosed with the congenital form [2, 13]. The phrenico-esophageal ligament is thick in both the thoracic and abdominal cavities, and the right crus of the diaphragm surrounds the lower esophageal sphincter, so that age-related degenerative changes of the phrenico-esophageal ligament that induce hiatal widening do not occur as often in small animals, unlike humans [6]. On the other hand, an acquired hiatal hernia related to age-associated degenerative change of the phrenico-esophageal ligament including a decrease of elastic tissue and an increase in the laxity of the ligament is more common in human beings [1, 8, 12]. Most cases of acquired type in small animals have an obvious underlying disease causing the hiatal hernia such as upper airway obstruction, trauma, or complications related to diaphragmatic hernia repair [1, 3, 4-6, 7, 9]. In this cat, it was considered as an idiopathic hiatal hernia because there was no history or obvious underlying disease causing the hiatal hernia. There was no doubt regarding the acquired nature of the hiatal hernia, as the cat was middle-aged and had been apparently healthy, with no clinical signs and no radiographic abnormalities on regular check-up before presentation. In addition, surgical findings suggested an acute lesion, as adhesion of the herniated organs was not detected. Interestingly, in this cat, the phrenico-esophageal ligament near the hiatus was severely thinned and loosened and it was similar to gross

findings of age-related degenerative changes of the ligament in human beings. We assumed that these changes of the phrenico-esophageal ligament might lead to the massive hiatal herniation of abdominal organs and be the reason why an idiopathic type-4 hiatal hernia occurred in this middle-aged cat. However, we could not find any histologic evidences to ascertain this assumption.

Type-4 hiatal hernias, even with mild symptoms, require emergency surgery because massive herniation of the abdominal organs through the relatively narrow hiatus can increase the risk of organ strangulation and because the large volume of the abdominal organs in the thoracic cavity can collapse the lung severely. Therefore, delayed surgical correction of a type-4 hiatal hernia may induce more fatal complications, such as ischemic necrosis, reperfusion injury, and re-expansion pulmonary edema. In this report, despite massive hiatal herniation of the abdominal organs, there was no severe compromise of the herniated organs or the lungs due to rapid reduction via urgent surgery within 24 h after hernia occurrence. In addition, the excessively widened hiatus with the thin, loosened phrenico-esophageal ligament may have helped minimise strangulation of the herniated organs.

This is the first case report describing an acquired type-4 hiatal hernia in a middle-aged cat. Age-associated degenerative changes of the phrenico-esophageal ligament are suspected as the primary cause, inducing massive hiatal herniation of the abdominal organs in a healthy, middle-aged cat with no underlying disease or trauma. Rapid reduction of the herniated organs via emergent surgery leads to a successful outcome and minimisation of complications in type-4 hiatal hernia.

## References

1. **Bright RM, Sackman JE, DeNovo C, Toal C.** Hiatal hernia in the dog and cat: a retrospective study of 16 cases. *J Small Anim Pract* 1990, **31**, 244-250.
2. **Brinkley CH.** Hiatus hernia in a cat. *Vet Rec* 1990, **127**, 46-47.
3. **DeSandre-Robinson DM, Madden SN, Walker JT.** Nasopharyngeal stenosis with concurrent hiatal hernia and megaesophagus in an 8-year-old cat. *J Feline Med Surg* 2011, **13**, 454-459.
4. **Gualtieri M, Olivero D.** Reflux esophagitis in three cats associated with metaplastic columnar esophageal epithelium. *J Am Anim Hosp Assoc* 2006, **42**, 65-70.
5. **Hwang Y, Kim S, Park M, Lee J, Chang D, Choi S, Kim G.** Acquired hiatal hernia after surgical repair of diaphragmatic hernia in a cat. *J Vet Clin* 2014, **31** (Suppl 1), 9.
6. **Jeong SM, Jeong ES, Kim SY, Choi SC, Son HJ, Lee CH, Yang JW, Kim WH, Seo M, Kweon OK, Nam TC.** [Congenital esophageal hiatal hernia in a cat]. *J Vet Clin Med* 2001, **18**, 61-64. Korean.
7. **Jergens AE.** Diseases of the Esophagus. In: Ettinger SJ, Feldman EC (eds.). *Textbook of Veterinary Internal Medicine*. 7th ed. pp. 1487-1499, Saunders Elsevier, St. Louis, 2010.
8. **Kahrilas PJ, Kim HC, Pandolfino JE.** Approaches to the

- diagnosis and grading of hiatal hernia. *Best Pract Res Clin Gastroenterol* 2008, **22**, 601-616.
9. **Lorinson D, Bright RM.** Long-term outcome of medical and surgical treatment of hiatal hernias in dogs and cats: 27 cases (1978-1996). *J Am Vet Med Assoc* 1998, **213**, 381-384.
  10. **Radlinsky MG.** Surgery of the esophagus. In: Fossum TW, Dewey CW, Horn CV, Johnson AL, MacPhail CM (eds.). *Small Animal Surgery*. 4th ed. pp. 436-478, Mosby Elsevier, St. Louis, 2013.
  11. **Rahal SC, Mamprim MJ, Muniz LMR, Teixeira CR.** Type-4 esophageal hiatal hernia in a Chinese Shar-pei dog. *Vet Radiol Ultrasound* 2003, **44**, 646-647.
  12. **Sivacolundhu RK, Read RA, Marchevsky AM.** Hiatal hernia controversies—a review of pathophysiology and treatment options. *Aust Vet J* 2002, **80**, 48-53.
  13. **Tong K, Guillou R, Vét D.** Congenital paraesophageal hernia in a cat. *J Am Anim Hosp Assoc* 2015, **51**, 252-255.