

Osseous metaplasia showing heterotopic ossification in the maxillary sinus

Sang-Hoon Kang¹, Jung Hyun Chang^{2,*}

¹Department of Oral and Maxillofacial Surgery, National Health Insurance Service Ilsan Hospital, Goyang, Republic of Korea

²Department of Otorhinolaryngology, National Health Insurance Service Ilsan Hospital, Goyang, Republic of Korea

ABSTRACT

Radiopacity in the maxillary sinus can be observed in various conditions, such as in the presence of lesions in the maxillary sinus or as a sequela of maxillary sinus surgery. This report describes the case of a 57-year-old female patient who had no previous history of surgical treatment or traumatic injury of the nose or maxillary sinus. Both maxillary sinuses were indistinguishable on panoramic radiography and showed signs of radiopacity. Computed tomography images revealed that the maxillary sinuses were filled with bony tissue and exhibited signs of sinus mucosal thickening. Biopsy results showed fragments of trabecular bone with fibrous tissue. (*Imaging Sci Dent* 2018; 48: 127-9)

KEY WORDS: Maxillary Sinus; Metaplasia; Osteogenesis

Radiopacity in the maxillary sinus can be observed in various conditions, such as in the presence of lesions in the maxillary sinus or as a sequela of maxillary sinus surgery.¹ Herein, we report a rare case of osseous metaplasia with bone and fibrous tissue in the bilateral maxillary sinuses in a patient with no relevant history of surgery or trauma.

Case

A 57-year-old female patient was referred for evaluation of the maxilla and oral cavity. She had a 2-year history of occasional nasal pain and no history of medical problems, trauma, surgical treatment of the nose or maxillary sinus, or use of drugs related to bone metabolism. The clinical examination at admission did not reveal nasal obstruction, postnasal drip, foul odor, anosmia, or snoring.

In panoramic radiographic images taken for a dental evaluation, both maxillary sinuses were indistinguishable and showed signs of radiopacity (Fig. 1). Computed

tomography images showed bony tissue filling the maxillary sinuses, as well as signs of sinus mucosal hypertrophy (Figs. 2 and 3). Ossification was predominantly observed in the left maxillary sinus, and was detected to some degree in the right frontal sinus region, but not in the ethmoid region. To examine the bony tissue, an intra-oral incisional biopsy of the left maxillary sinus was performed under local anesthesia. Biopsy analysis revealed trabecular bone fragments and fibrous tissue without cortical bone (Fig. 4). These histologic findings confirmed that the radiopaque lesion of the maxillary sinus was osseous metaplasia.^{1,2} The patient was advised to visit the hospital again if her symptoms of rhinitis recurred.

Discussion

Maxillary sinus ossification has been described in various conditions. Ossification can occur at the base of the maxillary sinus following maxillary sinus floor elevation for dental implant placement.³ Moreover, surgical treatments, such as radical curettage of the maxillary sinus, can induce a pattern of heterotopic ossification originating from the bone at the maxillary sinus wall.¹ However, the patient in the present case had no history of trauma or surgical treatment of the maxillary sinus or surrounding

Received February 2, 2018; Revised April 26, 2018; Accepted May 18, 2018

*Correspondence to : Dr. Jung Hyun Chang

Department of Otorhinolaryngology, National Health Insurance Service Ilsan Hospital, 100 Ilsan-ro, Ilsan-donggu, Goyang, Gyeonggi-do 10444, Republic of Korea
Tel) 82-31-900-0346, Fax) 82-303-3448-7138, E-mail) manbang5@naver.com

Copyright © 2018 by Korean Academy of Oral and Maxillofacial Radiology

This is an Open Access article distributed under the terms of the Creative Commons Attribution Non-Commercial License (<http://creativecommons.org/licenses/by-nc/3.0>) which permits unrestricted non-commercial use, distribution, and reproduction in any medium, provided the original work is properly cited.

Imaging Science in Dentistry · pISSN 2233-7822 eISSN 2233-7830

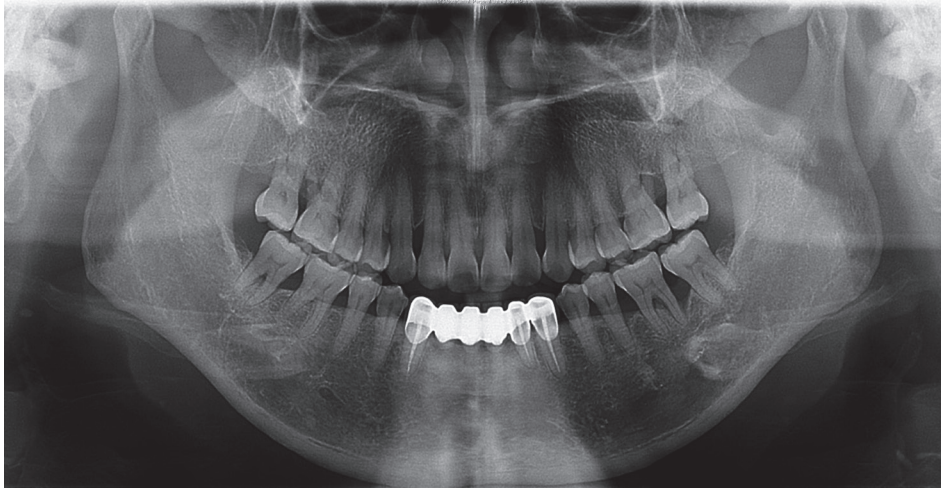


Fig. 1. Panoramic image showing the indistinguishable maxillary sinuses that both exhibited signs of radiopacity.

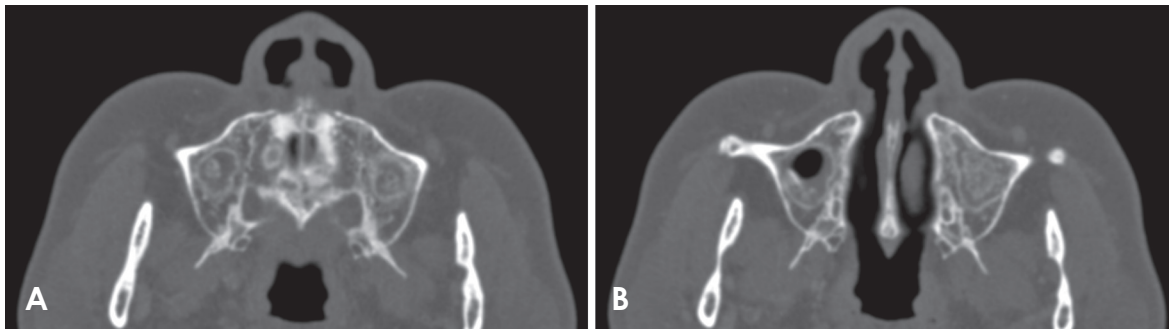


Fig. 2. Axial computed tomography images show dense calcifications within both maxillary sinuses, especially the left maxillary sinus, and loss of sinus cavity volume. A. A dense calcified radiopacity with mucosal thickening in the floor of the maxillary sinus. B. A dense, irregular, relatively well-defined, calcified radiopacity attached to the maxillary sinus wall.

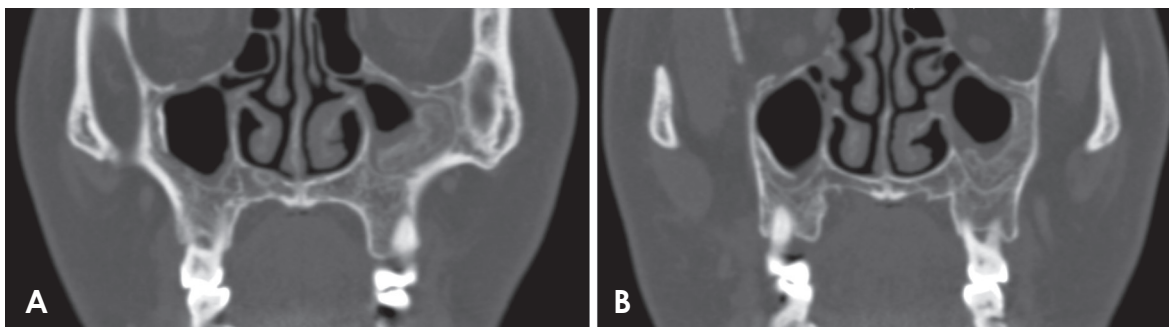


Fig. 3. Coronal computed tomography images show dense calcifications within both maxillary sinuses, especially the left maxillary sinus. A. A dense calcified radiopacity with mucosal thickening in the floor of the maxillary sinus and loss of sinus cavity volume. B. A dense, relatively well-defined, calcified radiopacity attached to the maxillary sinus wall and a more or less homogeneous radiopacity extending from the maxillary sinus lateral wall, with an especially filled area in the left maxillary sinus.

tissue. Radiopacity of the maxillary sinus has also been observed in cases of tumorous lesions of the maxillary sinus, which can be confirmed by biopsy based on the pattern of growth and invasion of surrounding anatomical structures.⁴ Ossification in both maxillary sinuses should

be differentiated from other lesions, such as antroliths and fungal disease of the maxillary sinus.⁵

Maxillary antroliths are masses formed by the gradual deposition of mineral salts. Calcium phosphate and calcium carbonate are endogenous minerals that can form

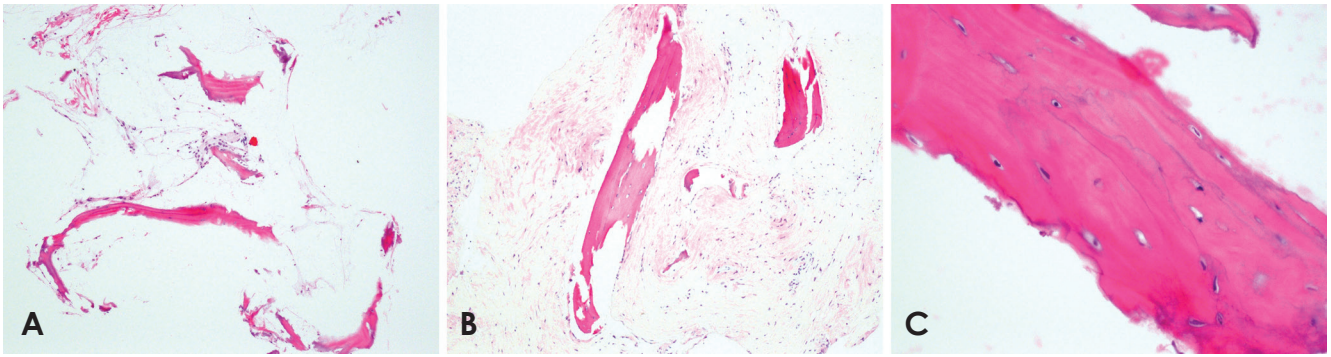


Fig. 4. Histopathological images of the left maxillary sinus region show trabecular bone and fibrous tissue (H&E stain, original magnification: A. $\times 100$, B. $\times 200$, C. $\times 400$. A and B. The slides show lamellar bone with fatty bone marrow and focal fibrosis of the marrow. C. The image shows lamellar bone tissue formation with osteocytes and lamellae.

antroliths.⁵ In this case, a dense and irregular, yet well-defined mass was radiographically identified in the maxillary sinus antrum. Antroliths must be included in the differential diagnosis of radiopacities found in or near the maxillary sinus region.⁶ They can be ruled out because antroliths form around a nidus or concentrated mucus and grow heterogeneously, with well-defined concentric layers extending from the maxillary sinus lateral wall. *Aspergillus* should be considered, as it is the most common pathogen involved in fungal sinus disease. It can cause complete or near-complete opacification of the sinus cavity, and is associated with thickening of the sinus mucosa.⁵ This point may be relevant in the differential diagnosis between *Aspergillus* infection and osseous metaplasia of the maxillary sinus. Other possible diagnoses include complex odontoma, mature cementoma, foreign bodies, and osteoma, which has the radiological appearance of a more or less homogeneous radiopaque lesion that is attached to the sinus wall with a small stem.⁴

Osseous metaplasia involves the bone in the maxillary sinus, including the Haversian system and bone marrow.² When a biopsy is required, the oral vestibular approach under local anesthesia can be useful, as was performed in the present case. The cause of osseous metaplasia in the present case is unknown.

Osseous metaplasia of the maxillary sinus, which appears as heterotopic ossification in radiographic images, should be considered as an additional possibility in patients with no history of surgery or trauma to the maxillary sinus.

References

1. Buyukakyuz N, Ergun S, Olgac V, Tanyeri H. Heterotopic ossification in the maxillary sinus. *J Craniofac Surg* 2008; 19: 684-6.
2. Maitra S, Gupta D, Radojkovic M, Sood S. Osseous metaplasia of the maxillary sinus with formation of a well-developed haversian system and bone marrow. *Ear Nose Throat J* 2009; 88: 1115-20.
3. Khalighi Sigaroudi A, Dalili Kajan Z, Rastgar S, Neshandar Asli H. Frequency of different maxillary sinus septal patterns found on cone-beam computed tomography and predicting the associated risk of sinus membrane perforation during sinus lifting. *Imaging Sci Dent* 2017; 47: 261-7.
4. Arslan HH, Tasli H, Cebeci S, Gerek M. The management of the paranasal sinus osteomas. *J Craniofac Surg* 2017; 28: 741-5.
5. Henriques JC, Kreich EM, Rosa RR, Castilho JC, de Moraes LC, de Moraes ME. Noninvasive aspergillosis as a maxillary antrolith: report of a rare case. *Quintessence Int* 2012; 43: 143-6.
6. Wu CW, Tai CF, Wang LF, Tsai KB, Kuo WR. Aspergillosis: a nidus of maxillary antrolith. *Am J Otolaryngol* 2005; 26: 426-9.