

## COMMUNICATION

## A novel concept for determining the direction of implanted hair in hairline correction surgery in East Asian women

Jae Hyun Park

Dana Plastic Surgery Clinic, Seoul, Korea

**Correspondence:** Jae Hyun Park

Dana Plastic Surgery Clinic, 606 Gangnam-daero, Gangnam-gu, Seoul 06038, Korea  
Tel: +82-2-512-0922, Fax: +82-2-512-0942, E-mail: jay8384@naver.com

Received: 1 Dec 2017 • Revised: 9 Mar 2018 • Accepted: 15 Mar 2018  
pISSN: 2234-6163 • eISSN: 2234-6171  
<https://doi.org/10.5999/aps.2017.01767> • Arch Plast Surg 2018;45:292-294



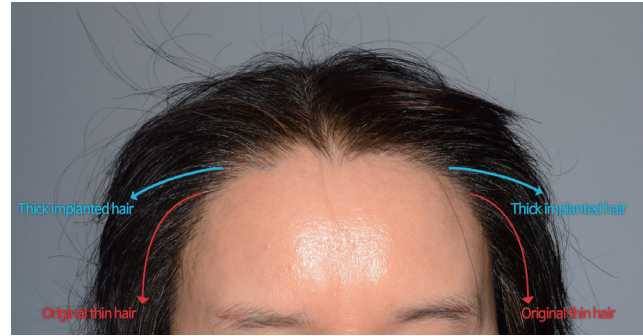Copyright © 2018 The Korean Society of Plastic and Reconstructive Surgeons  
This is an Open Access article distributed under the terms of the Creative Commons Attribution Non-Commercial License (<http://creativecommons.org/licenses/by-nc/4.0/>) which permits unrestricted non-commercial use, distribution, and reproduction in any medium, provided the original work is properly cited.

Modern hair transplant surgery is based on follicular unit transplantation [1]. The four major concepts describing the direction of an implanted hair's growth that are applied in the clinic are angle, direction, curl, and flow. Among these, angle and direction are the most basic and important. Hair angle refers to the angle at which a hair shaft exits the scalp; hair direction refers to whether the angle is to the left or the right [2,3].

Hair curliness varies according to race and genetic factors, and from person to person [4]. Every person has a unique curl, and the curl of all hairs is not the same in any one person; each individual's hair has a wide variety of curl patterns. East Asians' hair is neither straight nor curly, but has properties of both moderately wavy and straight hair. Nagase et al. [5] reported that 53% of Japanese women had straight hair, while the remaining 47% had curved hair, ranging from slightly wavy to frizzy. Transplanted curly or wavy hair does not grow with the angle and direction of the implanted follicle; instead, it grows according to its own curl after the hair shaft exits the skin.

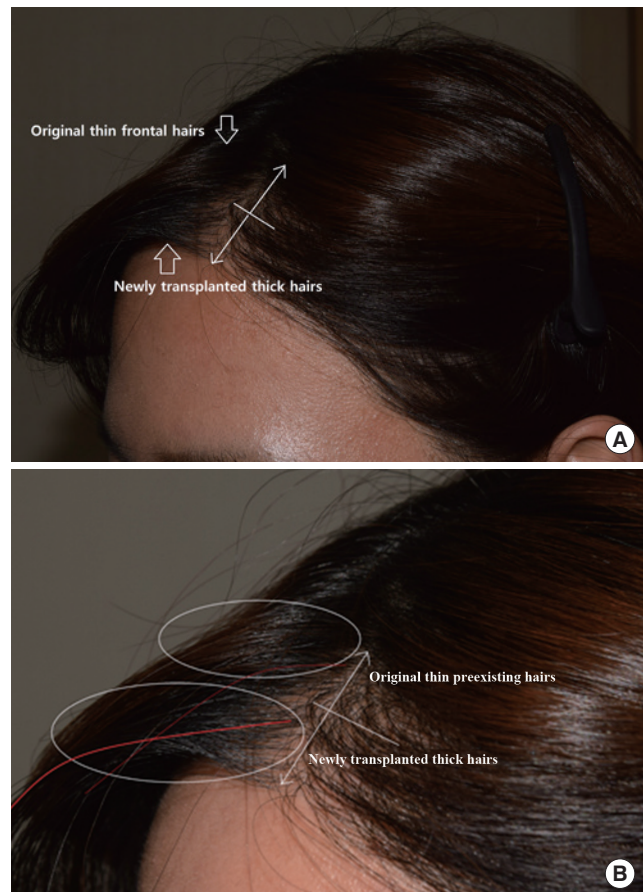
Flow refers to the pattern of directionality of a group of hairs in a region, rather than to the directionality of individual hair shafts. Hair flow along the frontal hairline is completely different in females and males. Hair flow does not follow a single pattern over the entire scalp; in particular, the hair flow pattern varies around the parietal whorl.

Even when the angle, direction, curl and, flow of a transplanted follicle are exactly matched with the natural angle and direction of the preexisting adjacent hairs, the transplanted hair can show a different growth direction, which results in an awkward appearance (Figs. 1, 2). To solve this problem, the author has developed the new concept of the hair growth vector. By applying this concept to hair transplant surgery, problems with awkward directions of hair growth are resolved.



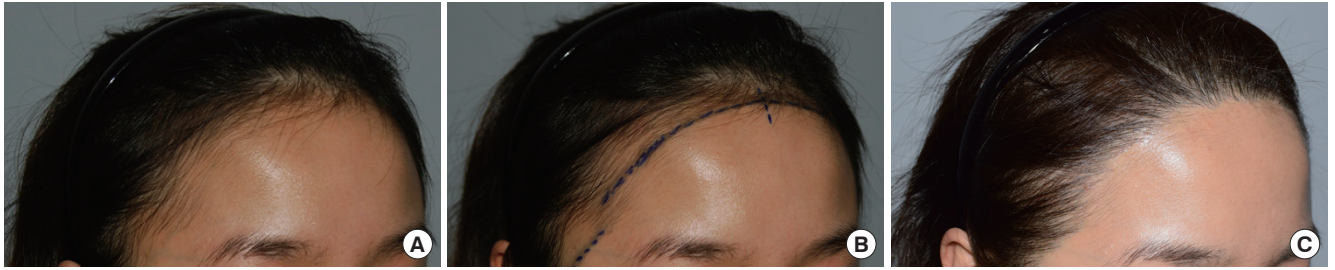
**Fig. 1.**

Incongruence of growth vectors, example 1. A 48-year-old female patient had undergone hairline correction surgery from the frontotemporal recess area to the side hairline 3 years previously. The implantation was performed in accordance with the angle and direction of the preexisting hair. However, unlike thin, frontal hairs (red arrows), which easily bend downwards under the influence of gravity, the thick, implanted hairs (blue arrows) created an awkward result by projecting outwards, more horizontally.



**Fig. 2.**

Incongruence of growth vectors, example 2. A 42-year-old female patient had undergone hairline correction surgery 2 years previously. The slit incision angles for the thick, newly transplanted hairs (thick red line) were identical to the direction of the thin, preexisting hairs (thin red line), but the direction of actual hair growth was completely different. (A) Ten-month postoperative view. (B) Magnified view.



**Fig. 3.**

Female hairline correction using growth vectors. The growth vector concept was employed when placing hairs in a 30-year-old female undergoing hairline correction surgery. (A) Preoperative view. (B) Surgical plan. (C) Twelve-month postoperative view, showing natural-looking results. Reprinted from Park. *Plast Reconstr Surg Glob Open* 2016;3:e589 [6].

Gravity has a greater effect on hair angle than on left or right directionality. The size and direction of the impact of gravity is constant. It acts equally on the inferior side of all hairs, but it affects hairs differently according to their direction of growth. Hair shaft thickness is important for determining how much the direction of hair growth is affected by its curliness and gravity, and in achieving a natural-looking match with the surrounding hair.

East Asians have coarse, wavy-to-curly, black hair, and have a lighter skin complexion than people of other Asian populations. Despite the surgeon's best attempts to observe the major principles of hair placement at the time of transplantation, patients who undergo hair transplantation often express complaints regarding the direction of the transplanted hair follicles. Women with thin individual hairs in the frontal hairline area and thick, curly hairs in the occipital donor area are most likely to be dissatisfied with the appearance of the implanted hair.

In men undergoing hair transplantation, hairs are placed at a relatively upright angle, so that the texture, thickness, and curl of individual hair shafts are rarely noticeable. In hairline correction surgery in women, in contrast, the grafts are placed at a more acute angle. The curl, thickness, and growth direction of each hair shaft are more visible, and this visibility affects the naturalness of the appearance. This trend tends to be especially pronounced when the side hairline is transplanted rather than when correction aims to lower the hairline height. These are all important factors in hairline correction surgery in East Asian women [6-8].

In hairline correction for East Asian women, precise surgical matching is necessary, with a complex analysis not only of the angle and direction of the follicle, but also specifically of hair growth direction. The follicle direction and the angle at which the hair exits the skin are the same as the angle of the slit incision. However, it can be seen that the direction of growth of the thin original hair differs from that of the newly transplanted hair over approximately 2 to 3 cm, as the hair orientation starts to be affected by curliness, gravity, and shaft thickness. The preexisting frontal hair bends downwards under the influence of gravity, in the form of a parabola. However, the newly transplanted hair is less affected by gravity, eventually stretching and bending. In other words, even if the hair exit angle and direction

are the same, the ultimate hair growth direction can be different. All hairs include the same components, and thus the most important variable in the directional nature of hair growth is shaft thickness. In the above case, in addition to the angle, direction, curl, and flow, the direction of hair growth also varies.

The hair growth vector refers to the ultimate growth direction, which comprehensively combines angle, direction, curl, flow, gravity, and shaft thickness. The thickness of the hair shafts is not an independent factor, but it exerts a significant effect on the relationships among the other five factors. For example, because the growth vector of thick, implanted hairs is different from that of thin, preexisting hairs, a more natural look can be achieved by implanting hair at a slightly different direction and angle from the preexisting hair, thereby compensating for the different effects of gravity on shafts of different thickness (Fig. 3).

Implanting hair according to the growth vector requires experience. When dealing with cases where the donor hair varies greatly in thickness and curl from the hair of the frontal hairline, or preexisting hairs take a peculiar growth direction (e.g., due to cowlick), even more caution is required when assessing the hair growth vector. Much thicker grafts can be inserted at a slightly more acute angle than that of preexisting thinner hairs in parallel with an attempt to match hair curl, thereby preventing implanted grafts from sticking out and ensuring that they are congruent with the preexisting hair.

Experience with this concept can be obtained by examining many patients during the follow-up period and observing the actual direction of implanted hair growth.

## Notes

### Conflict of interest

No potential relevant to this article was reported.

### Patient consent

The patients provided written informed consent for the publication and the use of their images.

## References

1. Bernstein RM, Rassman WR. The logic of follicular unit transplantation. *Dermatol Clin* 1999;17:277-95.
2. Shapiro R, Shapiro P. Hairline design and frontal hairline restoration. *Facial Plast Surg Clin North Am* 2013;21:351-62.
3. Unger WP. Recipient area hair direction and angle in hair transplanting. *Dermatol Surg* 2004;30:829-36.
4. Loussouarn G, Garcel AL, Lozano I, et al. Worldwide diversity of hair curliness: a new method of assessment. *Int J Dermatol* 2007;46 Suppl 1:2-6.
5. Nagase S, Tsuchiya M, Matsui T, et al. Characterization of curved hair of Japanese women with reference to internal structures and amino acid composition. *J Cosmet Sci* 2008;59:317-32.
6. Park JH. Novel principles and techniques to create a natural design in female hairline correction surgery. *Plast Reconstr Surg Glob Open* 2016;3:e589.
7. Park JH. Side-hairline correction in Korean female patients. *Plast Reconstr Surg Glob Open* 2015;3:e336.
8. Park JH. Masking the close eye appearance in the East Asian female population: infratemporal hairline reduction with hair grafting. *Aesthetic Plast Surg* 2016;40:921-5.