

Acute Rotator Cuff Tears due to Low Voltage Electrical Injury: A Case Report

Jae Hyun Yoo, Sung-Min Rhee¹, Ho Yong Shim², Jae Sung Lee^{3✉}

Department of Orthopaedic Surgery, Goodmorning Orthopaedic Hospital, Incheon, ¹Department of Orthopaedic Surgery, Seoul National University Bundang Hospital, Seoul National University College of Medicine, Seongnam, ²Department of Physical Medicine and Rehabilitation, Cleansu Hospital, ³Department of Orthopaedic Surgery, Chung-Ang University College of Medicine, Seoul, Korea

Since shoulder have a higher proportion of muscle which would have low electrical resistance, there could be more electrical damage to the rotator cuff muscles. We present a patient with acute rotator cuff tear by sudden uncontrolled jerking contractions caused by an electrical shock. A case of 42-year-old man with acute rotator cuff tear due to electrical injury to the shoulder was presented. Magnetic resonance imaging showed a full thickness tear and an undulating appearance of the peripheral end of the torn supraspinatus and infraspinatus muscle, suggesting an acute complete rupture. By arthroscopic surgery, the torn rotator cuff tendons were repaired with a suture bridge technique. At the final follow-up, the patient had a full, pain-free range of motion and had fully recovered shoulder muscle power.

(Clin Shoulder Elbow 2018;21(2):101-104)

Key Words: Rotator cuff tears; Electric burns; Muscle contraction; Trauma; Outcomes

Injuries through electric current are infrequently seen, and 75% to 88% of all electrical injuries involve the upper extremity.¹⁾ The distal forearm or hand, which have a relatively small cross-sectional area, demonstrate high resistance, which leads to disproportionately high generation of heat. The clinical manifestations of electrical injury in this area may be primarily in the form of electrical burns. More proximal areas such as the shoulder have a higher proportion of muscle with a larger cross-sectional area, and these demonstrate low electrical resistance. However, more than 20 mA in this area may exceed the 'let go threshold' due to tetanic muscular contractions caused by the alternating current, which can be strong enough to cause joint dislocation and even fractures.^{2,3)} Clinical manifestations in the shoulder region include posterior dislocation or fractures.^{4,5)} Previous studies have reported that 2.3% to 17.7% of RCTs occurred after a fall or another form of trauma.^{6,7)} Here, we report an rare case of a patient with acute RCT by sudden uncontrolled jerking contractions caused by an electrical shock.

Case Report

A healthy 42-year-old man presented with pain, a 2nd degree burn wound, and pseudoparalysis in his right shoulder; he had sustained an electrical injury to his right shoulder 3 weeks previous. He was a worker at a public bath and was injured while working in a bath machinery room. He heard an explosive, abrupt 'pop' in his right shoulder at the time of injury and became unable to elevate his right arm with severe pain. He was injured with an estimated 380 V. There were no symptoms in the right shoulder before the accident and no prior therapeutic procedures on the affected shoulder. On inspection, there was an approximately 6×5-cm-sized 2nd degree burn wound to his right shoulder (Fig. 1). Physical examination showed passive full range of motion, tenderness on the greater tuberosity, and positive findings on the Neer, Hawkins and empty can tests, but a negative horn-blower sign. His University of California at Los Angeles (UCLA) score was 2, neurologic and vascular functions

Received March 10, 2018. **Accepted** April 5, 2018.

✉ **Correspondence to:** Jae Sung Lee

Department of Orthopaedic Surgery, Chung-Ang University College of Medicine, 102 Heukseok-ro, Dongjak-gu, Seoul 06973, Korea

Tel: +82-2-6299-1577, **Fax:** +82-2-822-1710, **E-mail:** boneman@hanmail.net, **ORCID:** <https://orcid.org/0000-0002-3745-9048>

IRB approval: Chung-Ang University Hospital (No. 1701-006-16033).

Financial support: None. **Conflict of interests:** None.

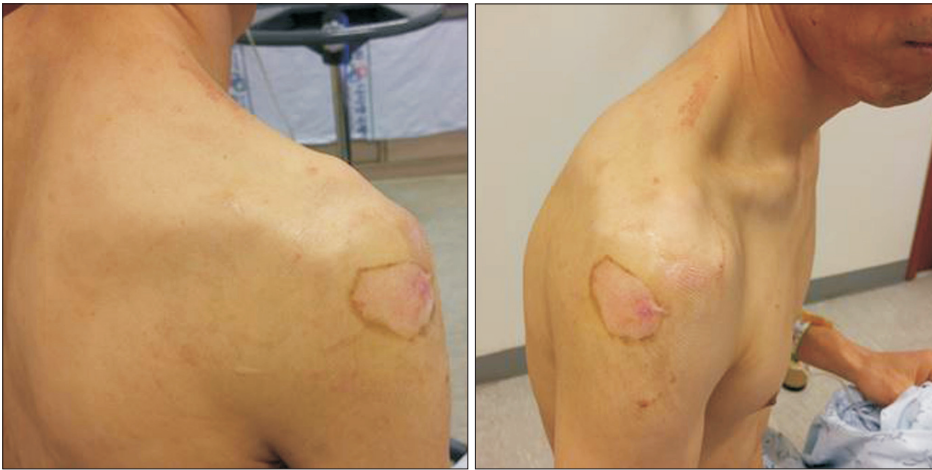

Fig. 1. Second degree burn wound on the deltoid area 3 weeks after the injury.

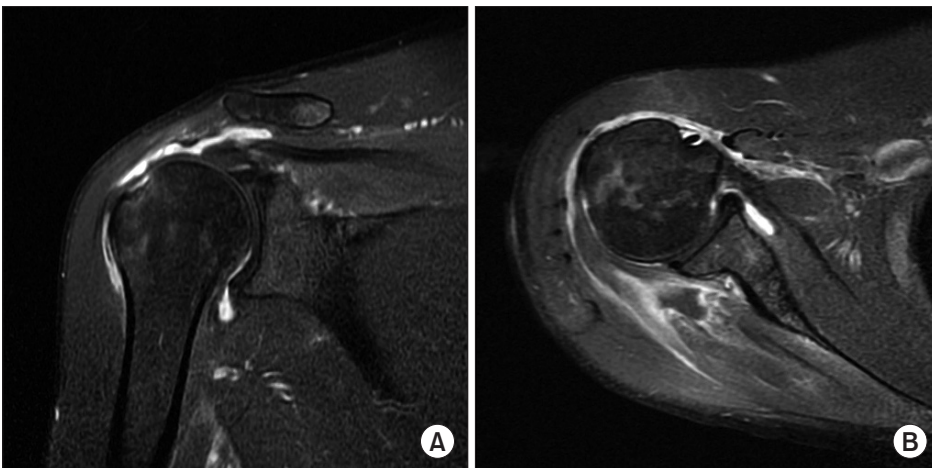


Fig. 2. (A) Preoperative magnetic resonance imagings showed full thickness tears and edematous changes in the supraspinatus and the infraspinatus. There was also an undulating appearance of the peripheral end of the torn muscle, but no tear in the subscapularis and labrum (B).

were not impaired, and preoperative electromyogram/nerve conduction velocity was within the normal range.

Radiographic imaging showed no specific findings except slightly superior migration of the humeral head. Magnetic resonance imaging (MRI) showed a full thickness tear and signal enhancement in the musculotendinous transition area of the supraspinatus (SSP) and the infraspinatus (ISP). There was also an undulating appearance of the peripheral end of the torn muscle, suggesting an acute complete rupture of the SSP and ISP. In addition, we could not detect atrophy in the torn muscle, ruptures of the subscapularis (SSC) or biceps tendon, or any labral tears (Fig. 2).

A decision was made to perform arthroscopic surgery. Under general anesthesia, the patient was prepared in a beach-chair position. At arthroscopy, the size of the RCT was estimated 5 cm in the anteroposterior diameter with medially retraction. The torn ends of the SSP and ISP were changed with blunt shapes and an ivory colored margin, and the SSP and ISP muscles were separated and torn longitudinally with several bleeding points in the torn muscular substance (Fig. 3).

The medially retracted SSP and ISP with blunt margins were fully mobilized, removing any adhesions to the surrounding tissue. The edges of the tendon were gently debrided, and a retention suture was placed to aid in tendon mobilization. The SSP and ISP were repaired with a suture bridge technique using two medial anchors (HEALICOIL PK, 4.5 mm; Smith & Nephew, London, UK), two lateral low anchors (FOOTPRINT PK [4.5 mm], Smith & Nephew; SwiveLock SP, Arthrex, Munich, Germany) and one additional lateral row anchor (Y-Knot, 1.8 mm; Conmed, Utica, NY, USA). Footprint coverage was about 100%. The surgery was uneventful, and the patient's arm was placed in an abduction brace.

Postoperatively, the patient was immobilized in a sling for 6 weeks with passive range of motion beginning at week 4 and active range of motion beginning at week 6. The rehabilitation progressed to passive stretching and muscle strengthening exercises after 2 months. The UCLA score was 35 at 18 months after surgery, and other clinical results and healing integrity of the rotator cuff upon ultrasound examination were very good (Fig. 4). At the final follow-up, the patient had a full, pain-free range of

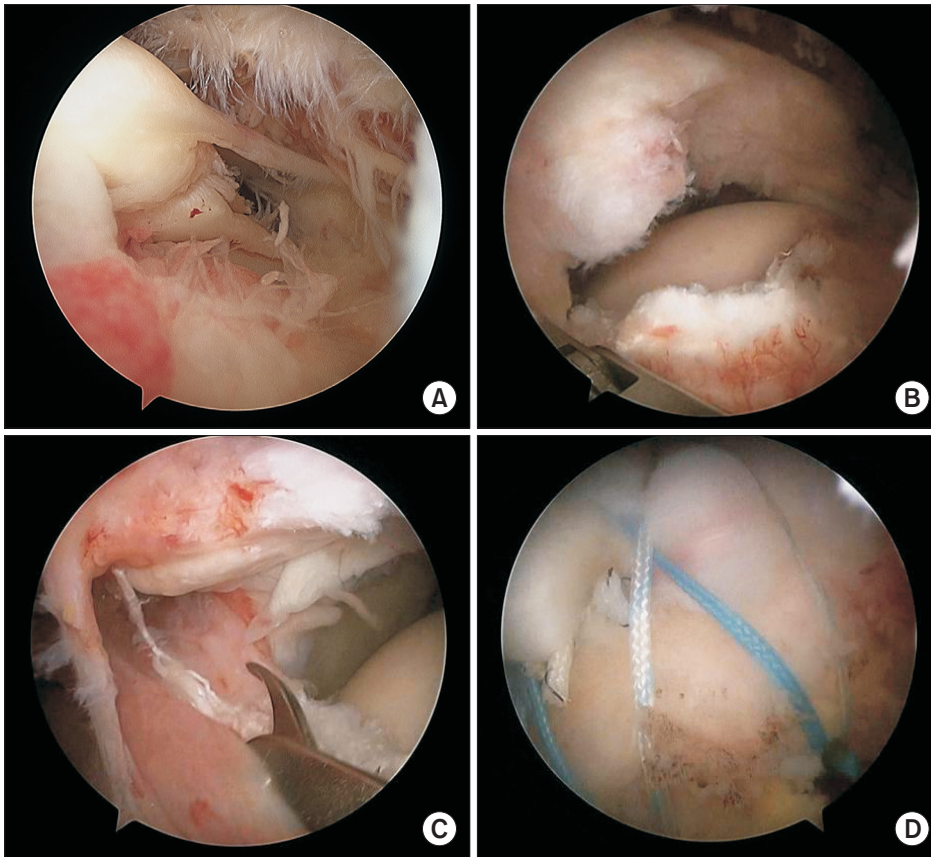


Fig. 3. (A) Arthroscopic findings show that the end of the torn supraspinatus (SSP) and infraspinatus (ISP) were changed, with a blunt shape and ivory colored margins. The SSP and ISP were medially retracted and (B) the SSP and ISP muscles were separated and torn longitudinally (C). Several bleeding points were seen in the torn muscular substance, and suture bridge repair was performed (D).

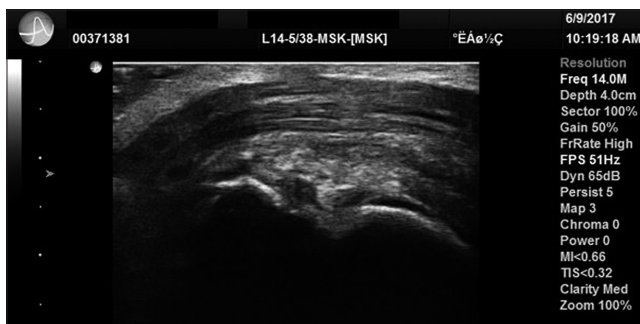


Fig. 4. An 18-month postoperative ultrasound demonstrated an intact surgical repair site.

motion and had fully recovered shoulder muscle power.

Discussion

This case report showed that an electrical current caused sudden, violent contraction of the rotator cuff muscles, resulting in acute rupture of the tendon without dislocation or fractures. This can be particularly valuable for understanding of the pathomechanism of a traumatic rotator cuff rupture. Traumatic ruptures to the rotator cuff are obviously less frequent. Some studies have estimated the proportion of traumatic RCTs

at between 2.3% and 17.7%.^{6,7)} The most common injury pattern was a fall, often onto an outstretched arm; other injury patterns included forceful external rotation with an abducted or adducted arm, motor vehicle accident, lifting a heavy object, sporting activities, and reaching out to grab a rail to prevent falling.⁷⁾ Although other possibilities (rupture by direct contact) are also conceivable, this case suggests that sudden muscle contraction may play an important role in traumatic tendon rupture. In addition, several reports showed that electric current caused powerful muscle contractions which were strong enough to produce fractures and dislocations which could lead to traumatic tendon rupture.^{4,5,8)}

The characteristics of traumatic RCTs without pre-existing degenerative impairment of the tendons include a relatively large tear (more than 3 cm in size and with 2 or more tendons involved) occurring at a relatively young age.⁷⁾ MRI findings suggesting a traumatic tendon rupture include muscle edema and kinking of the injured proximal tendon, accompanied by hemarthrosis.⁹⁾ These findings are relatively consistent with this case. Although some authors reported that traumatic tears were more likely to involve the SSC,⁷⁾ there was no injury of the SSC in this case. This can be explained by electric current which directly contacted on the posterolateral side of his shoulder. Shoulder injuries related to electric current have been reported

as a posterior dislocation and fracture of the proximal humerus and scapula.^{4,5)} Posterior dislocation of the shoulder due to forceful internal rotation is common during electrical injury, which suggests that the tetanic contraction acted primarily on the SSC, also only SSC rupture occurring through a similar mechanism has been previously reported.⁸⁾

The severity of electric injury is determined by numerous factors; the voltage, current, current type (alternating or direct), body resistance, electrical flow path, and duration of contact.¹⁰⁾ Among them, the most important factors are voltage and the type of current. Therefore, electrical injuries are classified as low-voltage (<1,000 V) or high voltage (>1,000 V) injuries.^{2,3)} High-voltage current may cause massive soft tissue injury or considerable skin necrosis at the contact site while passing through the body across the shortest distance without regard to tissue type. In contrast, low-voltage current has a tendency to transmit through tissues with low resistance including muscles, vessels and nerves. This is why low currents can result in fatal injuries, such as ventricular fibrillation or even cardiac arrest without any skin lesions.^{2,3,10)} Two thirds of all electrical injuries are low-voltage injuries. The skin has relatively effective resistance to electricity, which can be reduced 1,000-fold in the presence of moisture.³⁾ This patient was injured while working in the boiler room of a public bath house, where there would have been high humidity. Generally, where skin resistance is low, the direct cutaneous effect is also low, but a higher energy current tends to flow through the deeper tissue. Therefore, though he had a less severe electrical burn wound, the electric current would have directly affected the rotator cuff muscle and caused vigorous contraction.

In conclusion, Low voltage electric injury to the shoulder region can cause sudden violent contraction of the rotator cuff muscles, resulting in acute tendon rupture in addition to posterior dislocation and fracture of the proximal humerus and scapula.

References

1. Benmeir P, Lusthaus S, Ad-El D, et al. Very deep burns of the hand due to low voltage electrical laboratory equipment: a potential hazard for scientists. *Burns*. 1993;19(5):450-1.
2. Sokhal AK, Lodha KG, Kumari M, Paliwal R, Gothwal S. Clinical spectrum of electrical burns: a prospective study from the developing world. *Burns*. 2017;43(1):182-9.
3. Germann G. Hand reconstruction after burn injury: functional results. *Clin Plast Surg*. 2017;44(4):833-44.
4. Ketenci IE, Duymus TM, Ulusoy A, Yanik HS, Mutlu S, Durakbasa MO. Bilateral posterior shoulder dislocation after electrical shock: a case report. *Ann Med Surg (Lond)*. 2015;4(4):417-21.
5. Beswick DR, Morse SD, Barnes AU. Bilateral scapular fractures from low-voltage electrical injury. *Ann Emerg Med*. 1982;11(12):676-7.
6. Hantes ME, Karidakis GK, Vlychou M, Varitimidis S, Dailiana Z, Malizos KN. A comparison of early versus delayed repair of traumatic rotator cuff tears. *Knee Surg Sports Traumatol Arthrosc*. 2011;19(10):1766-70.
7. Mall NA, Lee AS, Chahal J, et al. An evidenced-based examination of the epidemiology and outcomes of traumatic rotator cuff tears. *Arthroscopy*. 2013;29(2):366-76.
8. Ji JH, Kim SJ, Kim WY, Lee YS, Ra KH. Subscapularis tendon tear after an electrical burn: a case report. *J Shoulder Elbow Surg*. 2008;17(2):e16-8.
9. Loew M, Magosch P, Lichtenberg S, Habermeyer P, Porschke F. How to discriminate between acute traumatic and chronic degenerative rotator cuff lesions: an analysis of specific criteria on radiography and magnetic resonance imaging. *J Shoulder Elbow Surg*. 2015;24(11):1685-93.
10. Parvathy G, Shaji CV, Kabeer KA, Prasanth SR. High-voltage electrocution causing bulbar dysfunction. *J Neurosci Rural Pract*. 2016;7(3):453-5.