

# Heart Transplantation in Patients with Superior Vena Cava to Pulmonary Artery Anastomosis: A Single-Institution Experience

Bo Bae Jeon, M.D., Chun Soo Park, M.D., Tae-Jin Yun, M.D., Ph.D.

Division of Pediatric Cardiac Surgery, Asan Medical Center, University of Ulsan College of Medicine

**Background:** Heart transplantation (HTx) can be a life-saving procedure for patients in whom single ventricle palliation or one-and-a-half (1½) ventricle repair has failed. However, the presence of a previous bidirectional cavopulmonary shunt (BCS) necessitates extensive pulmonary artery angioplasty, which may lead to worse outcomes. We sought to assess the post-HTx outcomes in patients with a previous BCS, and to assess the technical feasibility of leaving the BCS in place during HTx. **Methods:** From 1992 to 2017, 11 HTx were performed in patients failing from Fontan (n=7), BCS (n=3), or 1½ ventricle (n=1) physiology at Asan Medical Center. The median age at HTx was 12.0 years (range, 3–24 years). Three patients (27.3%) underwent HTx without taking down the previous BCS. **Results:** No early mortality was observed. One patient died of acute rejection 3.5 years after HTx. The overall survival rate was 91% at 2 years. In the 3 patients without BCS take-down, the median anastomosis time was 65 minutes (range, 54–68 minutes), which was shorter than in the patients with BCS take-down (93 minutes; range, 62–128 minutes), while the postoperative central venous pressure (CVP) was comparable to the preoperative CVP. **Conclusion:** Transplantation can be successfully performed in patients with end-stage congenital heart disease after single ventricle palliation or 1½ ventricle repair. Leaving the BCS in place during HTx may simplify the operative procedure without causing significant adverse outcomes.

*Key words:* 1. Heart transplantation  
2. Fontan procedure  
3. One and a half ventricle repair

## Introduction

Since the Fontan procedure was first described in 1971 for patients with tricuspid atresia, it has become the surgical procedure of choice for patients with a functionally single ventricle [1]. Although serial circulation without a pulmonary pump after the completion of the Fontan procedure is initially well tolerated, severe hemodynamic abnormalities may eventually result in Fontan failure. In addition to de-

terioration of the pulmonary vascular micro-circulation, Fontan failure is attributed to a range of other pathologic processes such as progressive ventricular failure, atrioventricular valve regurgitation, pulmonary vein obstruction, systemic outflow tract obstruction, and atrial arrhythmias [1,2].

Heart transplantation (HTx) can be a life-saving procedure for patients who are failing due to single ventricle or one-and-a-half (1½) ventricle physiology and are unresponsive to conventional measures.

Received: November 13, 2017, Revised: November 16, 2017, Accepted: November 16, 2017, Published online: June 5, 2018

Corresponding author: Tae-Jin Yun, Division of Pediatric Cardiac Surgery, Asan Medical Center, University of Ulsan College of Medicine, 88 Olympic-ro 43-gil, Songpa-gu, Seoul 05505, Korea (Tel) 82-2-3010-3589 (Fax) 82-2-3010-6966 (E-mail) [tjyun@amc.seoul.kr](mailto:tjyun@amc.seoul.kr)

© The Korean Society for Thoracic and Cardiovascular Surgery. 2018. All right reserved.

© This is an open access article distributed under the terms of the Creative Commons Attribution Non-Commercial License (<http://creativecommons.org/licenses/by-nc/4.0>) which permits unrestricted non-commercial use, distribution, and reproduction in any medium, provided the original work is properly cited.

Table 1. Preoperative patient characteristics

No.	Initial Dx	Pre-HTx state	Age at LO (yr)	Age at HTx (yr)	Bwt at HTx (kg)	CVP (mm Hg)	Vent. dysfnc.	Pre-HTx MV	Pre-HTx PLE
1	TA (Ic)	Post-BCS	1.7	3	10.9	25	-	-	-
2	TGA, VSD, PS	Post-Fontan	7.8	10	50	29	+	-	-
3	TGA, VSD, PS	Post-Fontan	4.0	12	35.4	29	+	+	-
4	TA (IIb)	Post-Fontan	3.8	11	26.3	24	-	-	+
5	HLHS	Post-Fontan	3.0	15	34.4	14	-	-	+
6	HLHS	Post-BCS	0.5	3	8.88	23	-	-	+
7	TGA, VSD, PS	Post-Fontan	3.9	16	45.1	22	+	+	-
8 <sup>a)</sup>	PA with IVS	Post-1½	5.7	24	90	17	+	-	-
9 <sup>a)</sup>	TGA, VSD, PS	Post-Fontan	2.6	14	58.5	23	+	-	-
10	DORV, cAVSD, PS	Post-BCS	15.7	18	45	11	-	-	+
11 <sup>a)</sup>	DORV, cAVSD, PS	Post-Fontan	4.7	5.7	20.7	20	+	-	+

Dx, diagnosis; HTx, heart transplantation; LO, last operation; Bwt, body weight; CVP, central venous pressure; Vent. dysfnc, ventricular dysfunction; MV, mechanical ventilation; PLE, protein losing enteropathy; TA, tricuspid atresia; BCS, bidirectional cavopulmonary shunt; TGA, transposition of the great arteries; VSD, ventricular septal defect; PS, pulmonary stenosis; HLHS, hypoplastic left heart syndrome; PA, pulmonary atresia; IVS, intact ventricular septum; 1½, one-and-a-half ventricle repair; DORV, double outlet right ventricle; cAVSD, complete atrioventricular septal defect.

<sup>a)</sup>Patients whose BCS was left intact after HTx.

Several factors may increase the risk of HTx in these populations, including the complexity of the original congenital heart anomalies and comorbidities such as hepatic and renal dysfunction [3]. Surgical dissection before heart excision is a difficult and time-consuming procedure due to previous operations. Furthermore, take-down of the previous bidirectional cavopulmonary shunt (BCS) and re-anastomosis of the superior vena cava (SVC) to the donor SVC with an extensive pulmonary artery angioplasty may render the operation even more complicated [4]. Because these patients are accustomed to high central venous pressure (CVP) prior to HTx, they can tolerate post-operative central venous hypertension. However, whether the clinical outcomes of HTx differ depending on whether the previous BCS is taken down or left in place has not been investigated.

The purpose of this study was to investigate post-HTx outcomes in patients failing from single ventricle or 1½ ventricle physiology and to assess the technical feasibility of leaving the BCS in place during HTx.

## Methods

Of the 666 patients who underwent orthotopic HTx at Asan Medical Center from 1992 to 2017, 11 (6 males) had failing Fontan (n=7), BCS (n=3), or 1½

ventricle (n=1) physiology. Information regarding patients' initial diagnosis, pre-HTx state, age at the last operation and HTx, and the presence or absence of preoperative ventricular dysfunction, mechanical ventilator support, and protein losing enteropathy (PLE) is presented in Table 1. The median age at HTx was 12.0 years (range, 3 to 24 years), and the median interval from the last operation to HTx was 8.6 years (range, 1.0 to 18.6 years). The number of previous cardiac operations was 1 in 1 patient (9.1%), 2 in 2 patients (18.2%), and 3 or more in 8 patients (72.7%).

Patients with a previous Fontan or BCS procedure were indicated for transplantation if they had ongoing heart failure symptoms despite optimal medical therapy, including maximal afterload reduction such as home inotropic support, or if they had PLE refractory to standard medical therapy, Fontan baffle refenestration, or enlargement of a preexisting fenestration [2]. No patient in this study had undergone extra-cardiac conduit Fontan conversion from a previous atriopulmonary Fontan procedure prior to HTx. The indications for HTx were impaired ventricular function in 6 patients (54.5%) and PLE in 5 patients (45.5%).

Patients' pre-transplantation clinical condition was assessed in the context of previous cardiac operations, ventricular systolic and diastolic function,

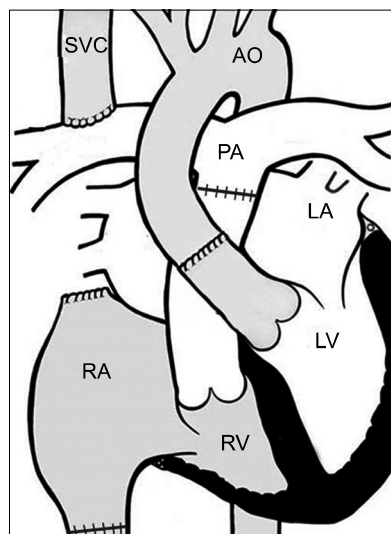
competence of the atrioventricular valves and semi-lunar valves, CVP, and the presence or absence of co-morbidities such as atrial and ventricular arrhythmia, renal failure, hepatic insufficiency, PLE, and ventilator and/or inotrope dependency. Three patients (patients #8, #9, and #11) underwent cardiac transplantation leaving the previous bidirectional Glenn anastomosis intact (Table 1). The prevalence of central venous hypertension symptoms, such as upper extremity edema, numbness, and jugular vein engorgement was assessed, and preoperative and postoperative CVP values were compared.

### 1) Preoperative clinical state

All patients had been hospitalized prior to HTx, and 7 patients (63.6%) were on inotropic support including dopamine, dobutamine, and/or milrinone. Moderate to severe ventricular dysfunction was present in 6 patients (54.5%). Valve insufficiency and arrhythmia were present in 4 (36.4%) and 3 (27.3%) patients, respectively. Mechanical ventilation was required in 2 patients (18.2%), and extracorporeal membrane oxygenation with continuous renal replacement therapy was applied in 1 patient (9.1%).

### 2) Operative technique

Perfect coordination of the donor and recipient operations is the key to reducing donor heart ischemic time and recipient cardiopulmonary bypass time [5]. Following a repeated median sternotomy, the aorta, the main pulmonary artery, the SVC, and the inferior vena cava (IVC) were dissected and isolated from the adjacent structures. Cardiopulmonary bypass was instituted via cannulation in the ascending aorta and both venae cavae except for 1 patient (patient #8), who underwent femoral artery and venous cannulation prior to the dissection of a dense retrosternal adhesion. After cardiectomy, conventional anastomosis was done in the following sequence: the left atrium, the IVC, the main pulmonary artery, and the ascending aorta. After the aortic cross-clamp was released, the SVC was divided from the right pulmonary artery and reanastomosed to the donor SVC. Extensive pulmonary artery angioplasty was performed on the SVC division site prior to SVC anastomosis [4]. In 3 patients, the pre-existing BCS was left *in situ* without SVC take-down from the pulmonary artery (Fig. 1).



**Fig. 1.** An illustration of the heart after transplantation with the bidirectional cavopulmonary shunt left in place. SVC, superior vena cava; Ao, aorta; PA, pulmonary artery; LA, left atrium; LV, left ventricle; RA, right atrium; RV, right ventricle.

## Results

There were no early deaths. Perioperative patient characteristics are summarized in Table 2. The median follow-up duration was 18 months (range, 1–176 months). One patient died of acute rejection at 3.5 years postoperatively, and the overall survival rate was 91% at 2 years. All patients who had PLE preoperatively showed elevated serum albumin levels at the last follow-up after transplantation (1.4–2.0 g/dL to 3.4–4.0 g/dL). The median anastomosis time of the patients in whom the BCS was left in place was 65 minutes (range, 54–68 minutes), which was shorter than that of the BCS take-down patients (93 minutes; range, 62–128 minutes) (Table 3). There was no significant CVP elevation after transplantation in the patients in whom the BCS was left in place (17 to 14 mm Hg in patient #8, 23 to 14 mm Hg in patient #9, and 20 to 20 mm Hg in patient #11).

## Discussion

The Fontan procedure has been established as a standard form of surgical palliation for single-ventricle physiology [6]. However, long-term complications, such as systemic ventricular dysfunction, insufficiency of the atrioventricular or semilunar valves,

Table 2. Perioperative patient characteristics

No.	Procedure time (min)	CPB time (min)	Ischemic time (min)	Warm ischemic time (min)	Anastomosis time (min)	Postop CVP (mm Hg)	Postop ICU stay (day)	C-tube IT (day)	Postop hospital stay (day)
1	335	127	155	62	62	8	19	8	31
2	540	260	102	87	87	11	13	6	31
3	432	239	175	83	128	13	16	13	232
4	503	298	159	32	109	8	14	21	49
5	502	213	130	69	67	16	6	8	31
6	622	364	319	82	82	13	78	44	133
7	584	323	271	86	102	14	17	60	116
8 <sup>a)</sup>	595	420	171	64	68	14	6	28	31
9 <sup>a)</sup>	417	209	135	56	54	14	6	35	46
10	385	215	252	49	83	4	6	5	41
11 <sup>a)</sup>	480	228	281	79	65	20	43	65	90

CPB, cardiopulmonary bypass; CVP, central venous pressure; ICU, intensive care unit; postop, postoperative; C-tube IT, chest tube indwelling time.

<sup>a)</sup>Patients whose bidirectional cavopulmonary shunt was left intact after heart transplantation.

Table 3. Comparison of perioperative variables according to BCS take-down during heart transplantation

Variable	BCS take-down group (n=8)	BCS left in place group (n=3)
Operative variables		
Total procedure time (min)	503 (335-622)	480 (417-595)
Cardiopulmonary bypass time (min)	250 (127-364)	228 (209-420)
Total ischemic time (min)	167 (102-319)	171 (135-281)
Anastomosis time (min)	93 (62-128)	65 (54-68)
Postoperative variables		
Mechanical ventilation (day)	5 (0.5-77)	2 (1-28)
Intensive care unit stay (day)	15 (6-78)	6 (6-43)
Hospital stay (day)	49 (31-232)	46 (31-90)
Chest-tube indwelling time (day)	17 (5-60)	35 (28-65)

Values are presented as median (range).

BCS, bidirectional cavopulmonary shunt.

atrial and ventricular arrhythmias, renal failure, hepatic insufficiency, and PLE, are not infrequent [6,7]. With these complications, impaired functional capacity and hemodynamic deterioration may lead to failure of the Fontan circulation. Patients with failing Fontan physiology who are not responsive to medical or surgical interventions are listed as candidates for HTx [8-10]. Similar patients with BCS or 1½ ventricle may also experience circulation failure, which is attributed to the complications mentioned above. If medical and surgical interventions are not effective for the reversal of a patient's clinical deterioration, HTx should also be considered. Given the difficulties in finding size-matched donors for this rapidly deteriorating subset of patients, listing for HTx should be

carried out far in advance. Risk factors for mortality of HTx after a Fontan operation are known to be preoperative renal failure, preoperative mechanical ventilation, and preserved systolic ventricular function with PLE [1,8,11]. However, as long as these risk factors are mitigated prior to HTx, the mid-term outcomes of pediatric HTx recipients with failing Fontan physiology are deemed similar to those of other pediatric HTx recipients [2].

Because surgical dissection for recipient heart excision in this subset takes a long time due to multiple previous operations and changes in the structural configuration of the heart and its adjacent structures, reducing the donor heart ischemic time and recipient bypass time is the key to successful HTx [5].

Removing the previous BCS with extensive pulmonary artery reconstruction also takes a long time and may impair the postoperative outcomes [4,12]. Furthermore, abnormalities in the position of the SVC or the presence of bilateral SVC requires different complex approaches during transplantation. In this regard, leaving the previous BCS in place is expected to be beneficial. One of the most important concerns after employing this strategy is central venous hypertension. However, we presume that patients can tolerate a high CVP after transplantation because (1) their pre-transplant CVP was already high and (2) CVP is expected to decrease with the improvement of ventricular diastolic function, due to the postoperative decrease of left ventricular end-diastolic pressure (EDP) compared to the preoperative EDP of a single ventricle. The outcomes of the first patient who underwent transplantation with the BCS left in place were successful, and this technique has been our institutional strategy ever since. In this study, anastomosis time appeared to be shorter in patients in whom the BCS was left in place than in the patients who underwent take-down of the previous BCS, while postoperative elevation of CVP was not observed in patients in whom the BCS was left in place.

As previously mentioned, HTx is the only surgical option for patients with failing Fontan, BCS, or 1½ ventricle physiology. Although the study population was small and we did not investigate long-term outcomes, the early outcomes of transplantation were acceptable in this subset. Furthermore, leaving BCS in place during HTx for patients with previous single ventricle palliation or 1½ ventricle repair may simplify the operative procedure, without significant adverse effects.

### Conflict of interest

No potential conflict of interest relevant to this article was reported.

### Acknowledgments

This study was supported by a Grant of the Samsung Vein Clinic Network (Daejeon, Anyang, Cheongju, Cheonan; Fund no. KTCS04-104).

### References

1. Backer CL, Russell HM, Pahl E, et al. *Heart transplantation for the failing Fontan*. Ann Thorac Surg 2013;96:1413-9.
2. Jayakumar KA, Addonizio LJ, Kichuk-Christant MR, et al. *Cardiac transplantation after the Fontan or Glenn procedure*. J Am Coll Cardiol 2004;44:2065-72.
3. Tabarsi N, Guan M, Simmonds J, et al. *Meta-analysis of the effectiveness of heart transplantation in patients with a failing Fontan*. Am J Cardiol 2017;119:1269-74.
4. Chen JM, Davies RR, Mital SR, et al. *Trends and outcomes in transplantation for complex congenital heart disease: 1984 to 2004*. Ann Thorac Surg 2004;78:1352-61.
5. Cheng A, Slaughter MS. *Heart transplantation*. J Thorac Dis 2014;6:1105-9.
6. Kanter KR, Mahle WT, Vincent RN, Berg AM, Kogon BE, Kirshbom PM. *Heart transplantation in children with a Fontan procedure*. Ann Thorac Surg 2011;91:823-9.
7. Deal BJ, Jacobs ML. *Management of the failing Fontan circulation*. Heart 2012;98:1098-104.
8. Davies RR, Sorabella RA, Yang J, Mosca RS, Chen JM, Quaegebeur JM. *Outcomes after transplantation for "failed" Fontan: a single-institution experience*. J Thorac Cardiovasc Surg 2012;143:1183-92.
9. Voeller RK, Epstein DJ, Guthrie TJ, Gandhi SK, Canter CE, Huddleston CB. *Trends in the indications and survival in pediatric heart transplants: a 24-year single-center experience in 307 patients*. Ann Thorac Surg 2012;94:807-15.
10. Carey JA, Hamilton JR, Hilton CJ, et al. *Orthotopic cardiac transplantation for the failing Fontan circulation*. Eur J Cardiothorac Surg 1998;14:7-13.
11. Griffiths ER, Kaza AK, Wyler von Ballmoos MC, et al. *Evaluating failing Fontans for heart transplantation: predictors of death*. Ann Thorac Surg 2009;88:558-63.
12. Cooper MM, Fuzesi L, Addonizio LJ, Hsu DT, Smith CR, Rose EA. *Pediatric heart transplantation after operations involving the pulmonary arteries*. J Thorac Cardiovasc Surg 1991;102:386-94.