

# Panton-Valentine Leukocidin Positive Methicillin-Susceptible *Staphylococcus aureus*: A Case Report of Two Pediatric Patients with Thrombotic Complications

David Chun Ern Ng, L. Alexis Anand, Fu Lung Khiu, Kah Kee Tan

Department of Pediatric, Tuanku Ja'afar Hospital, Seremban, Malaysia

*Staphylococcus aureus* is a well-recognized human pathogen that causes a wide range of infections as a result of its extensive virulence factors. One of these factors is Panton-Valentine leukocidin (PVL), a potent pore-forming cytotoxin that has been linked to invasive *S. aureus* infections. PVL is one of the important virulence factors for *S. aureus* and has been largely recognized as one of the markers for community-acquired methicillin-resistant *S. aureus*. However, the presence of PVL in methicillin-susceptible *S. aureus* infections is not widely reported in the literature. Thrombotic sequelae of *S. aureus* infections associated with PVL expression are uncommon in children. We hereby report two children with thrombotic complications associated with PVL-producing methicillin-susceptible *S. aureus*. Both patients responded well to antibiotic and anticoagulant therapies, and survived without any long-term sequelae.

**Key Words:** Panton-Valentine leukocidin; *Staphylococcus aureus*; Child

## Introduction

*Staphylococcus aureus* is a common pathogen in skin, soft tissue, catheter-related, bone, joint, pulmonary and cardiovascular system infections. *S. aureus* bacteremias are particularly problematic due to the high incidence of complications associated with the infection. Here we report 2 pediatric patients with thrombotic complications due to *S. aureus* infections associated with the production of Panton-Valentine leukocidin (PVL).

**Received:** 9 August 2017

**Revised:** 8 November 2017

**Accepted:** 1 December 2017

**책임저자:** David Chun Ern Ng

Department of Pediatric, Tuanku Ja'afar Hospital, Seremban, Malaysia

Tel: +60-6-768-4000, Fax: +60-6-763-2900

E-mail: [davidngce@gmail.com](mailto:davidngce@gmail.com)

## Cases

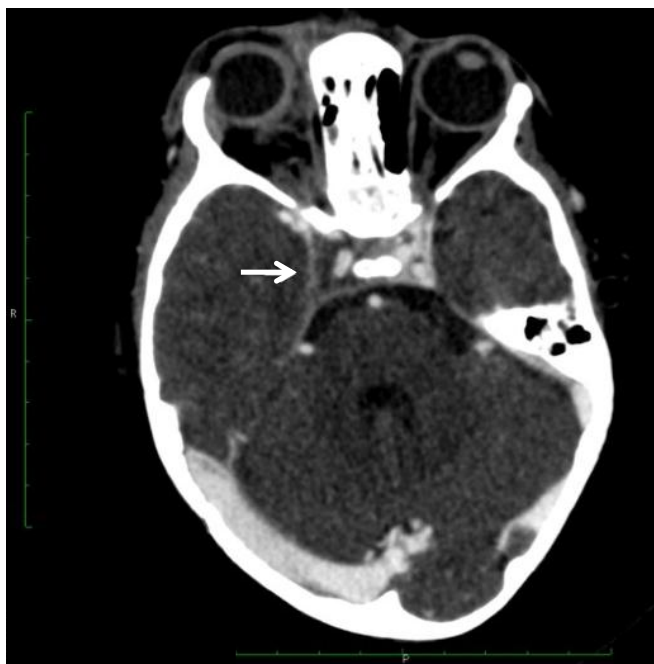### 1. Case 1

A previously healthy 19-month-old girl was admitted with fever and progressive bilateral periorbital swelling for 5 days which was preceded by a pustule over the nasal bridge that ruptured after scratching. She did not receive any antibiotics prior to admission. Physical examination revealed bilateral periorbital swelling with proptosis, chemosis, and partial ptosis of the right eyelid. Further neurological and ophthalmological findings were normal. Laboratory evaluation on admission showed white blood cell (WBC) counts  $26.0 \times 10^3/\mu\text{L}$  (neutrophils 68%, lymphocytes 24%) and C-reactive protein (CRP) of 160 mg/L. Blood culture on admission grew gram positive cocci, which were identified as methicillin-susceptible *S. aureus* (MSSA). The isolate was also susceptible to clindamycin, cefuroxime, fusidic acid, cotrimoxazole, rifampin, and gentamicin. Computed tomography (CT) brain revealed right maxillary and ethmoidal sinusitis with right cavernous sinus thrombosis (Fig. 1). A spinal tap was not performed as the child

did not exhibit any signs of meningism. Intravenous (IV) cloxacillin was given for 2 weeks in combination with IV gentamicin for the first 5 days. The periorbital swelling reduced remarkably after 72 hours of antibiotics and by the end of the first week, the fever settled and there was just minimal partial ptosis over the right eye. The child was discharged with normal physical examination findings after 2 weeks of inpatient treatment. CRP on discharge was 2.6 mg/L. Medications were converted to oral cefuroxime and clindamycin for 4 weeks upon discharge. Subcutaneous low molecular weight heparin (LMWH) was given for 4 months and stopped when the repeated CT brain showed resolution of the cavernous sinus thrombosis and the thrombophilia screen returned negative. The child remained well during the 6th month follow-up with no long term neurological or ophthalmological sequelae. Genes encoding PVL (*lukS*-PV and *lukF*-PV) were detected by polymerase chain reaction amplification on the blood culture isolate sent to the reference laboratory.

## 2. Case 2

A previously healthy 7-year-old boy was admitted



**Fig. 1.** Filling defect seen within the enlarged right cavernous sinus (arrow) with proptosis of right globe for patient 1.

with a 3-day history of fever and painful right knee swelling without any preceding history of trauma. He did not receive prior antibiotics. At presentation, he was febrile with a temperature of 39.3°C. An erythematous swelling measuring 2×2 cm was seen over the medial aspect of the right knee. The swelling was warm, tender and joint movements of the affected knee was restricted. An ultrasound examination revealed a subcutaneous abscess over the medial aspect of the right knee. Laboratory tests showed WBC  $20.2 \times 10^3/\mu\text{L}$  (neutrophils 89%, lymphocytes 6%) and raised CRP levels 102 mg/L. Treatment was started with IV cloxacillin. Surgical incision and drainage was performed on the superficial abscess, which drained 5 mL of pus. On the third day of admission, PVL positive MSSA was isolated from pus and blood cultures. The isolates were also susceptible to clindamycin, cefuroxime, fusidic acid, cotrimoxazole, rifampin, and gentamicin. At the same time, the patient developed a diffuse swelling over the right thigh extending to the calf. Doppler ultrasonography revealed a long segment thrombus along the right iliac, right common femoral, superficial femoral, and popliteal vein with no flow within the veins (Fig. 2). Echocardiography showed no signs of infective endocarditis. IV clindamycin and gentamicin were added to the treatment regime. Subcutaneous LMWH was administered for the extensive deep vein thrombosis (DVT). The right lower limb swelling reduced remarkably within 72 hours of LMWH administration. The patient completed 2 weeks of inpatient IV antibiotics and repeated blood cultures showed no bacterial growth. His fever settled completely by the 6th day of admission. Antibiotics were switched to oral cloxacillin and rifampin on discharge. CRP on discharge was 16 mg/L. Resolution of the right lower limb DVT on Doppler ultrasonography was noted after 4 months of treatment. The follow-up musculoskeletal and respiratory examination at outpatient clinic at 6 months post-discharge were normal. He completed a total of 8 weeks of antibiotics and 4 months of LMWH. The thrombophilia screen was negative. The patient experienced no major complications during the entire course of antibiotic and anticoagulant treatment.

## Discussion

Venous thromboembolism is rare in childhood but carry devastating consequences. The estimated incidence in children is 0.07 to 0.14 per 10,000 children with a bimodal age distribution, particularly in neonates and adolescents<sup>1)</sup>. Venous thrombosis in children is usually associated with predisposing factors such as sepsis, trauma, presence of a central line, malignancies, and pre-existing coagulation disorders<sup>2)</sup>. *S. aureus* is well recognized as an important pathogen involved in infection-associated DVT and cavernous sinus thrombosis<sup>3,4)</sup>.

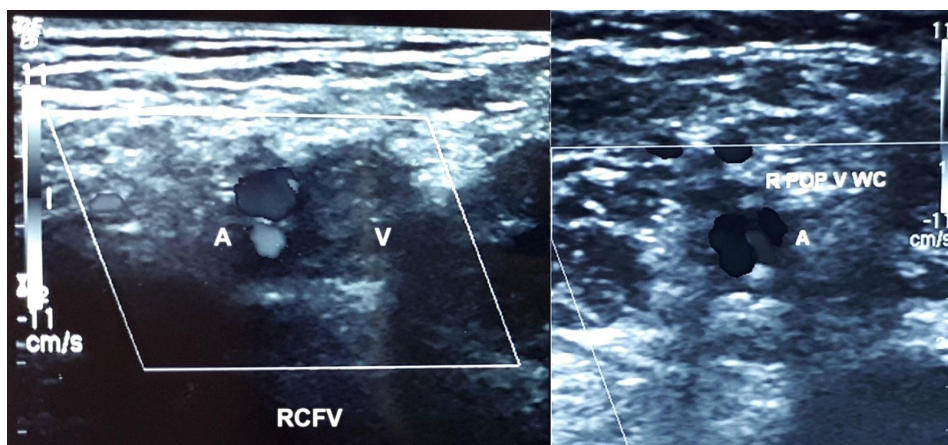
Septic cavernous sinus thrombosis can be associated with significant complications and neurologic disability if not detected early. The most common clinical manifestations include chemosis, ptosis, ophthalmoplegia and diplopia due to involvement of specific structures within the cavernous sinus. For our patient, the infection which started over the danger triangle of the face likely lead to bacterial invasion of the paranasal sinus and hematogenous spread through the valveless system of the facial and ophthalmic veins into the cavernous sinus.

Lower extremity DVT usually develops as a consequence of venous stasis, hypercoagulability and endothelial damage, which is known as the Virchow triad. *S. aureus* surface proteins and exotoxins (such as PVL) contribute to thrombus formation through the release

of various inflammatory chemical mediators and through effects on the coagulation pathway and anticoagulation factors. Furthermore, the invasion of endothelial cells triggers fibrin formation, leukocyte adhesion, and platelet aggregation<sup>3,5)</sup>.

The PVL toxin is one of the important factors in the virulence mechanism of the bacteria. PVL is a potent pore-forming cytotoxin produced by certain strains of *S. aureus* which is encoded by two genes, *lukS-PV* and *lukF-PV*<sup>6)</sup>. PVL-producing strains of *S. aureus* are highly associated with necrotizing infections and increased severity of disease, such as necrotizing fasciitis, venous thrombosis, purpura fulminans, and necrotizing pneumonia<sup>5-8)</sup>. The presence of PVL has been extensively described for methicillin-resistant *S. aureus* (MRSA), and is regarded as one of the markers for community acquired MRSA isolates<sup>9,10)</sup>. However, infections with PVL-positive MSSA have not been widely reported, although it has been documented to be as high as 37% to 67% among MSSA isolates<sup>11,12)</sup>.

Animal models of virulence associated with PVL-positive *S. aureus* is controversial and the clinical utility of routine PVL testing in MSSA infections is unclear. Nevertheless, this report stresses the fact that invasive infections due to MSSA could start off with innocuous symptoms and should not be treated lightly as such infections may have potentially serious outcomes, and that PVL expression in MSSA isolates may be associated



**Fig. 2.** Ultrasound Doppler at transverse section over right common femoral vein (RCFV) and right popliteal vein (R POP V) showed an echogenic thrombus within with no Doppler signal for patient 2. Abbreviation: WC, with compression.

with life-threatening consequences.

The management of these thrombotic complications due to *S. aureus* would include antibiotics, anticoagulation and supportive care. The anticoagulant of choice and duration of therapy are highly variable from numerous reports in literature. A case series of pediatric cavernous sinus thrombosis by Smith et al.<sup>4)</sup> showed the median duration of anticoagulation was 3 months and 80% of those were treated with LMWH. Gonzalez et al.<sup>13)</sup> documented a mean duration of 4.9 months of anticoagulation (range, 2.5 to 10 months) in his case series of pediatric DVT associated with staphylococcal osteomyelitis. There were no bleeding complications due to LMWH therapy in our patients as well as in literature review, suggesting that LMWH therapy is safe. Clinicians should be aware that serious and life threatening complications may be associated with PVL-positive MSSA infections.

## References

1. Chalmers EA. Epidemiology of venous thromboembolism in neonates and children. *Thromb Res* 2006;118:3-12.
2. Kuhle S, Massicotte P, Chan A, Adams M, Abdolell M, de Veber G, et al. Systemic thromboembolism in children. Data from the 1-800-NO-CLOTS Consultation Service. *Thromb Haemost* 2004;92:722-8.
3. Mantadakis E, Plessa E, Vouloumanou EK, Michailidis L, Chatzimichael A, Falagas ME. Deep venous thrombosis in children with musculoskeletal infections: the clinical evidence. *Int J Infect Dis* 2012;16:e236-43.
4. Smith DM, Vossough A, Vorona GA, Beslow LA, Ichord RN, Licht DJ. Pediatric cavernous sinus thrombosis: a case series and review of the literature. *Neurology* 2015; 85:763-9.
5. Martin E, Cevik C, Nugent K. The role of hypervirulent *Staphylococcus aureus* infections in the development of deep vein thrombosis. *Thromb Res* 2012;130:302-8.
6. Loffler B, Hussain M, Grundmeier M, Bruck M, Holzinger D, Varga G, et al. *Staphylococcus aureus* panton-valentine leukocidin is a very potent cytotoxic factor for human neutrophils. *PLoS Pathog* 2010;6:e1000715.
7. Changchien CH, Chen YY, Chen SW, Chen WL, Tsay JG, Chu C. Retrospective study of necrotizing fasciitis and characterization of its associated methicillin-resistant *Staphylococcus aureus* in Taiwan. *BMC Infect Dis* 2011; 11:297.
8. Hussain A, Robinson G, Malkin J, Duthie M, Kearns A, Perera N. Purpura fulminans in a child secondary to Panton-Valentine leukocidin-producing *Staphylococcus aureus*. *J Med Microbiol* 2007;56(Pt 10):1407-9.
9. Bhatta DR, Cavaco LM, Nath G, Kumar K, Gaur A, Gokhale S, et al. Association of Panton Valentine leukocidin (PVL) genes with methicillin resistant *Staphylococcus aureus* (MRSA) in Western Nepal: a matter of concern for community infections (a hospital based prospective study). *BMC Infect Dis* 2016;16:199.
10. Rahimi F, Katouli M, Pourshafie MR. Characteristics of hospital- and community-acquired methicillin-resistant *Staphylococcus aureus* in Tehran, Iran. *J Med Microbiol* 2014;63(Pt 6):796-804.
11. Muttaiyah S, Coombs G, Pandey S, Reed P, Ritchie S, Lennon D, et al. Incidence, risk factors, and outcomes of Panton-Valentine leukocidin-positive methicillin-susceptible *Staphylococcus aureus* infections in Auckland, New Zealand. *J Clin Microbiol* 2010;48:3470-4.
12. Correa-Jimenez O, Pinzon-Redondo H, Reyes N. High frequency of Panton-Valentine leukocidin in *Staphylococcus aureus* causing pediatric infections in the city of Cartagena-Colombia. *J Infect Public Health* 2016;9:415-20.
13. Gonzalez BE, Teruya J, Mahoney DH Jr, Hulten KG, Edwards R, Lamberth LB, et al. Venous thrombosis associated with staphylococcal osteomyelitis in children. *Pediatrics* 2006;117:1673-9.