

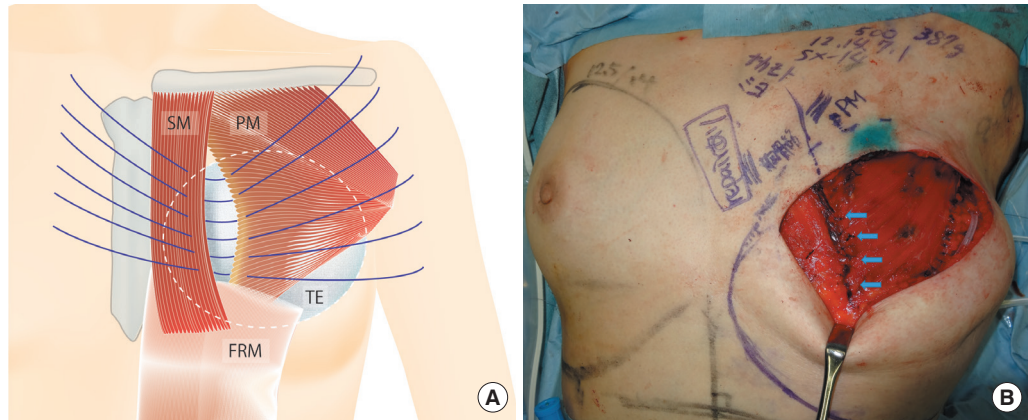Fig. 3.

(A) Repair of the loose adipose connection. The textured surface of the tissue expander filled with saline caused the collapse of the loose adipose connection between the sternalis muscle and pectoralis major muscle, resulting in a caudal lesion that was 5.0 cm long. The tissue expander was subsequently removed and 6 untied sutures were inserted in these muscles. The SV-14 tissue expander (volume, 500 mL; height, 12 cm; width, 14 cm; projection, 7.1 cm) was made by Allergan Inc. (Santa Barbara, CA, USA). (B) Insertion of the tissue expander in the musculofascial pocket. Untied sutures were ligated carefully and both the pectoralis major muscle and the fascia of the serratus anterior muscle were sutured. The tissue expander was subsequently inserted into the musculofascial pocket. The blue arrows indicates the ligated untied sutures. SM, sternalis muscle; PM, pectoralis major muscle; FRM, fascia of rectus abdominis muscle; TE, tissue expander.

which is often thin, and the pectoralis major muscle without damaging the tissue expander, preventing the recurrence of collapse in this area of connective tissue when inserting it after the ligation of sutures during repair. This technique may be improved by combining it with horizontal mattress sutures.

Conflict of Interest

No potential conflict of interest relevant to this article was reported.

Patient Consent

The patient provided written informed consent for the publication and the use of their images.

References

- Schulman MR, Chun JK. The conjoined sternalis-pectoralis muscle flap in immediate tissue expander reconstruction after mastectomy. *Ann Plast Surg* 2005;55:672-5.
- Barlow RN. The sternalis muscle in American whites and Negroes. *Anat Rec* 1934;61:416-26.
- Alani HA, Balalaa N. Complete tissue expander coverage by musculo-fascial flaps in immediate breast mound reconstruction after mastectomy. *J Plast Surg Hand Surg* 2013;47:399-404.

Double-sided folded internal pudendal artery perforator flap for the repair of a recurrent rectovaginal fistula

Sang Keon Lee, Yong Seok Lee, Seung Yong Song, Won Jai Lee, Dong Won Lee

Institute for Human Tissue Restoration, Department of Plastic and Reconstructive Surgery, Severance Hospital, Yonsei University College of Medicine, Seoul, Korea

Correspondence: Dong Won Lee
Department of Plastic and Reconstructive Surgery, Yonsei University College of Medicine, 50-1 Yonsei-ro, Seodaemun-gu, Seoul 03722, Korea
Tel: +82-2-2228-2215, Fax: +82-2-393-6947
E-mail: xyphoss@yuhs.ac

The authors would like to thank Dong-Su Jang, a medical illustrator in the Medical Research Support section of Yonsei University College of Medicine, Seoul, Korea, for assistance with the illustration.

Received: 7 Feb 2017 • Revised: 14 Sep 2017 • Accepted: 19 Sep 2017
pISSN: 2234-6163 • eISSN: 2234-6171
<https://doi.org/10.5999/aps.2017.00269>
Arch Plast Surg 2018;45:90-92



Copyright © 2018 The Korean Society of Plastic and Reconstructive Surgeons
This is an Open Access article distributed under the terms of the Creative Commons Attribution Non-Commercial License (<http://creativecommons.org/licenses/by-nc/4.0/>) which permits unrestricted non-commercial use, distribution, and reproduction in any medium, provided the original work is properly cited.

A 53-year-old woman underwent 3 fistulectomies performed by a colorectal surgeon due to a recurrent rectovaginal fistula (RVF), which developed 2 years after complicated labor dystocia with an episiotomy.

Nonetheless, the fistula recurred, and the patient was referred to the Department of Plastic and Reconstructive Surgery, where a plan was made to use a double-sided folded internal pudendal artery perforator (IPAP) flap to repair the recurrent RVF (Fig. 1A). Prior to this operation, a laparoscopic diverting loop ileostomy was performed by a colorectal surgeon.

After complete debridement of the fistula and the surrounding unhealthy tissue, the exact localization of the flap to be elevated was determined via tracing of the IPAP using Doppler ultrasound (Fig. 1B). The flap was partitioned into 2 compartments in a distal to proximal direction from the perforator, and each flap was designated as "R" and "V," respectively. The "R" and "V" areas were determined considering the size of the rectal opening and the distance between the vulva and the vaginal opening. The proximal part of the "R" flap was de-epithelialized and folded with the subcutaneous fat sides facing each other, and was then transposed between the vagina and rectum to replace the damaged rectovaginal septum (Fig. 2). As a result, both the vaginal and rectal openings of the fistula were covered with a well-vascularized skin paddle (Fig. 1C).

At a 3-month postoperative visit, the fistula was confirmed to be completely closed by a Gastrografin contrast enema (Fig. 3), and transrectal ultrasonography performed 1 year postoperatively also showed no evidence of RVF recurrence (Fig. 4).

RVF is not a common complication of pelvic procedures. However, RVF repair is usually challenging for both patients and surgeons because of its high recurrence rate after primary repair [1]. The inflamed state of the tissue, poor vascular perfusion of the bed, and fibrotic adhesions from prior surgery are thought to be the most important factors contributing to recurrence. Therefore, treatment of recurrent RVF necessitates coverage of both the vaginal and rectal sides of the fistula with healthy, well-vascularized, perfused flaps [2]. Various surgical techniques, such as random pattern flaps, muscle transposition, and even artificial mesh grafts, have been tried for repairing recurrent RVF. However, none of these methods have been accepted as a procedure of choice because of an unsatisfactory recurrence rate and poor cosmetic and functional outcomes [1]. In this case, a technique covering the entire fistula region with a well-vascularized IPAP flap was utilized. The IPAP flap is considered an excellent choice for reconstruction of the pelvic region because

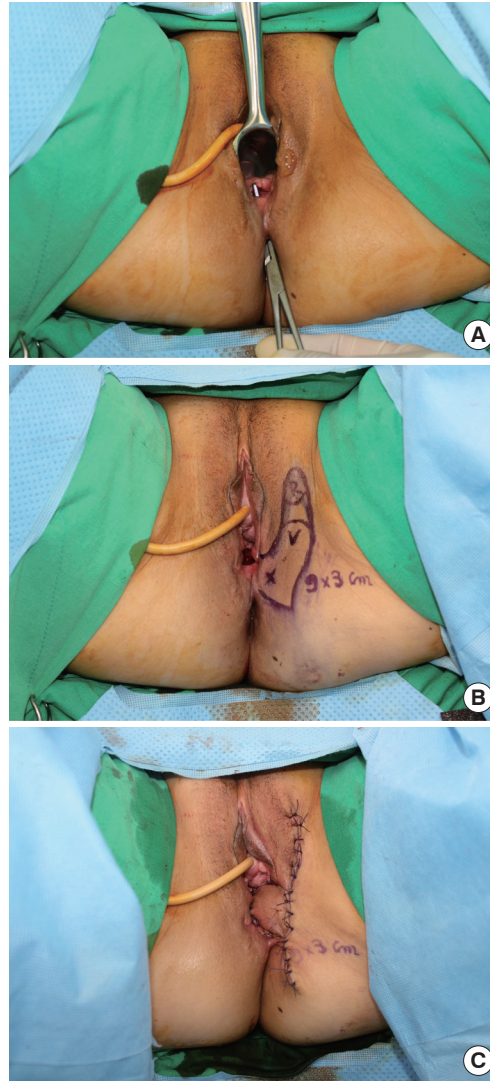


Fig. 1. Double-sided folded internal pudendal artery perforator flap operation. A recurrent RVF with a diameter of about 40 mm, located approximately 7 cm upward from the anus, was present (A). A folded IPAP flap was designed in an area 3 cm from the perineum and 9 cm cranially. "X" indicates the location of the perforator vessel, as confirmed by Doppler ultrasonography. A de-epithelialized area was located between "R" and "V," and was folded (B). Immediate postoperative photograph shows that both the vaginal and rectal opening of the fistula were covered with a well-vascularized skin paddle (C). RVF, rectovaginal fistula; IPAP, internal pudendal artery perforator.

it can be used without causing any notable functional deformities. Furthermore, it has a dominant vascular pedicle that can be used for perineal transposition with adequate length. All these factors contribute to the use of the IPAP flap in pelvic reconstructive surgery [3]. However, adaptation of the folded IPAP flap to cover both the vaginal and rectal sides at the same time in the treatment of a recurrent RVF has not been previously reported, and the outcome was satisfactory. In conclusion, the use of a double-sided folded IPAP flap can be considered a reliable and feasible procedure to cover both the vaginal and rectal sides of an RVF with a well-vascularized, perfused skin paddle.

Conflict of Interest

No potential conflict of interest relevant to this article

Fig. 2.

A schematic illustration of the double-sided folded IPAP flap. Preoperative state of the RVF, which connected the posterior vagina and anterior rectum (A). Flap design and elevation; "R" and "V" indicate the distal and proximal parts of the flap, respectively, and the proximal part of "R" was de-epithelialized (B). The flap was folded and fistula debridement was performed; the arrow indicates the direction in which the flap rotated (C). Both the vaginal and rectal openings were covered with the skin paddle of the IPAP flap (D). IPAP, internal pudendal artery perforator; RVF, rectovaginal fistula.

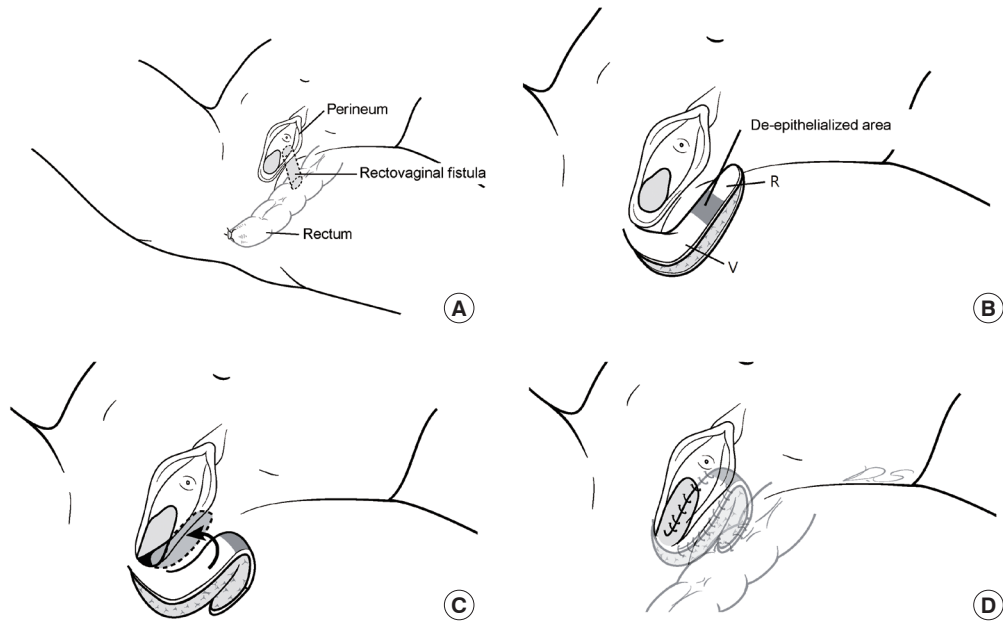
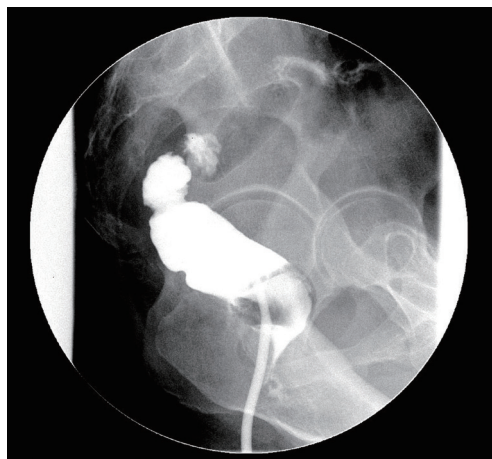


Fig. 3.

Three-month postoperative fistulography. No visible contrast leakage or abnormal fistulous tract was observed in the lateral view.



was reported.

Patient Consent

The patient provided written informed consent for the publication and the use of their images.

References

1. Kaoutzanis C, Pannucci CJ, Sherick D. Use of gracilis muscle as a "walking" flap for repair of a rectovaginal fistula. *J Plast Reconstr Aesthet Surg* 2013;66:e197-200.
2. Corte H, Maggiori L, Treton X, et al. Rectovaginal fistula: what is the optimal strategy?: an analysis of 79 patients undergoing 286 procedures. *Ann Surg* 2015;262:855-60.
3. Hashimoto I, Abe Y, Nakanishi H. The internal pudendal

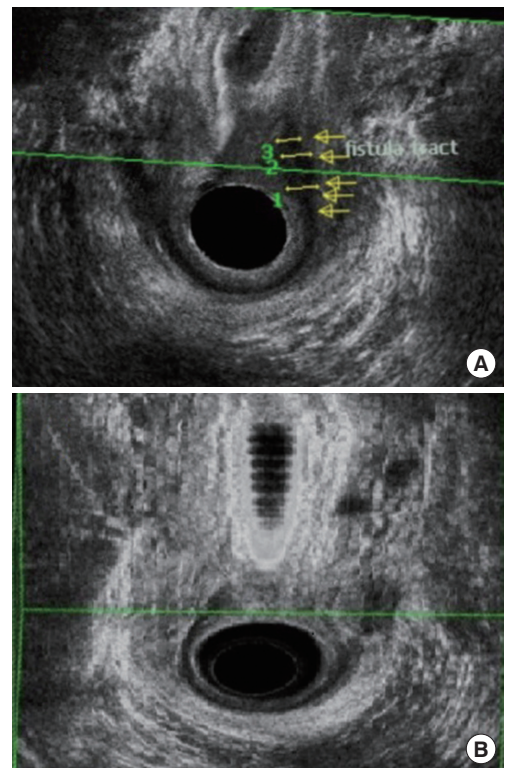


Fig. 4

Transrectal ultrasonography. Preoperative TRUS; yellow arrows indicate the RVF (A), and there was no evidence of RVF recurrence on 1-year postoperative TRUS (B). TRUS, transrectal ultrasonography; RVF, rectovaginal fistula.

artery perforator flap: free-style pedicle perforator flaps for vulva, vagina, and buttock reconstruction. *Plast Reconstr Surg* 2014;133:924-33.