

< Case Report >

Diagnosis and treatment of a calf with patent urachus

Seungmin Ha*, Sooyoung Kim, Seongmin Kim, Sookyoung Park, Soochan Lee,
Kihwa Jung, Euntae Kim, Seokjin Gang, Taeseok Han

Department of Animal Resources Development, National Institute of Animal Science, Cheonan 31000, Korea

(Received 18 January 2018; revised 19 March 2018; accepted 19 March 2018)

Abstract

A 2-month-old female Holstein Friesian calf was noted to leak urine from the umbilicus during urination. She urinated through both the umbilicus and the urethra. A conduit from the umbilicus to the bladder was identified with ultrasonography. Uroperitoneum was ruled out because blood urea nitrogen and creatinine were within reference ranges. Surgery was performed to resect the patent urachus. Urachitis was identified during surgery. Dexamethasone and an antibiotic were used for the inflammation and postoperative cares. Meloxicam was substituted for dexamethasone since the calf showed side effects to dexamethasone. The calf recovered completely and there was no urine leakage from the umbilicus.

Key words : Patent urachus, Calf, Urachitis, Dexamethasone

INTRODUCTION

The umbilical cord is composed of the amniotic membrane, the umbilical vessels and the urachus. The umbilical cord ruptures at birth and the umbilical vessels retract to form ligaments. The urachus, a channel between the fetal bladder and the umbilicus, normally closes at birth (Laverty and Salisbury, 2002). Inborn or acquired factors such as failure of urachal involution, neonatal omphalitis, umbilical abscess and congenital urethral obstruction may result in failure of urachal closure, known as patent urachus (McGavin et al, 2001). Ascending infection may result in urachitis, omphalophlebitis and cystitis, predisposing the calf to septicemia (Hunt and Allen, 1989; Divers and Peek, 2008). Calves with patent urachus show signs of urine dripping from the urachus and have a wet umbilical region (Divers and Peek, 2008; Anderson and Rings, 2009). This paper describes the diagnosis and perioperative care of a calf with patent urachus raised in the National Institute of

Animal Science in Cheonan City, South Chungcheong Province, Republic of Korea, 2017.

CASE

A 2-month-old female Holstein Friesian calf was noted to dribble urine from the umbilicus while urinating through the urethra (Fig. 1). The calf urinated through both the umbilicus and the urethra and urinated more often and for shorter duration than other calves. Ultrasonography with a 3 MHz convex probe (BCF Easi-Scan Curve ultrasound scanner) identified a conduit from the umbilicus to the bladder, identified as a patent urachus. Small particles were identified in the bladder and the urachus via ultrasonography (Fig. 2). With the exception of monocytosis (4.34 K/ μ L), preoperative hematological analysis yielded normal results. Normal blood urea nitrogen (BUN) and creatinine levels ruled out uroperitoneum.

After the administration of intravenous xylazine, the calf was placed in dorsal recumbency for a ventral mid-line laparotomy. The forelimbs were extended with ties.

*Corresponding author: Seungmin Ha, Tel. +82-41-580-3407,
Fax. +82-41-580-3429, E-mail. justusha@korea.kr

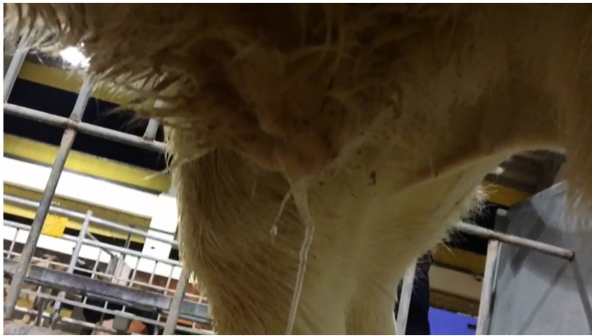

Fig. 1. Calf dribbling urine through the patent urachus while urinating.

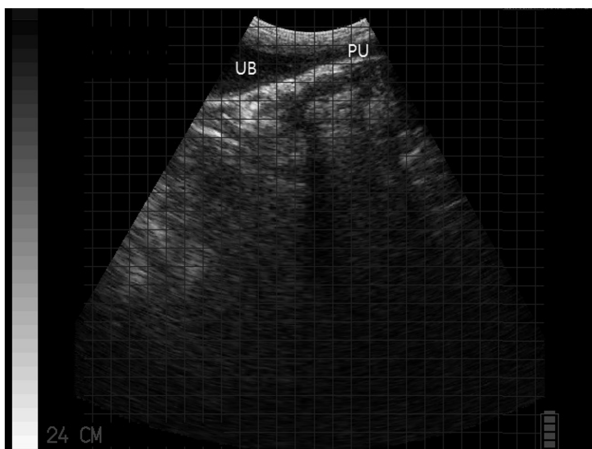


Fig. 2. Sagittal ultrasonographic image showing the urinary bladder (UB) connected with the patent urachus (PU). Small particles in the urinary bladder and the patent urachus.

Lidocaine hydrochloride (2%) was used for local anesthesia. A skin incision was made elliptically around the umbilicus. To avoid damage to abdominal organs while dissecting the umbilical cord, the linea alba was incised about 5 cm cranial to the umbilicus. The patent urachus was separated from the internal abdominal wall and the greater omentum to the bladder (Fig. 3). No umbilical vessels were identified around the patent urachus. Before separating the umbilical cord from the bladder, stay sutures were placed on the bladder to prevent urine leakage into the abdomen and to identify cystitis. There was no inflammation of the bladder, but urachitis was noted. The bladder was closed with a simple continuous suture and sewn with a lambert suture over the continuous suture. Horizontal mattress suturing was used on the abdominal muscles for high tension.

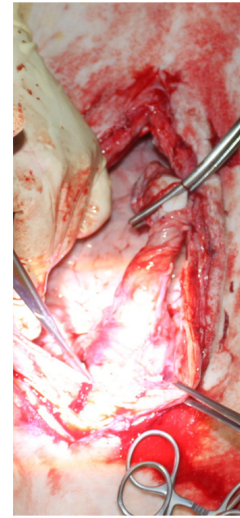


Fig. 3. Dissected patent urachus during the surgery.

Dexamethasone and an antibiotic that consisted of Procain penicillin G and dihydrostreptomycin sulfate were used for urachitis and postoperative cares. Dexamethasone was replaced by meloxicam because the calf was unable to focus her eyes or stand and was seen to stagger for several steps and fall down. The neurologic signs resolved after treatment. Postoperative BUN and creatinine levels were within reference range, indicating that there was no urine leakage into the abdomen.

DISCUSSION

Patent urachus is usually treated by surgical removal of the entire urachus or cauterization of the urachus. However cauterization may lead to urachal abscess by confining bacteria in the urachus (Anderson and Rings, 2009). Preoperatively, we confirmed that urine flowed out of both the umbilicus and the urethra, which meant the urethra was normal. The cause of pollakiuria in this calf was identified during surgery, the urachal remnant did not allow the bladder to fully decompress, resulting in the frequent urge to urinate (Anderson et al, 2008). The smaller orifice at the umbilicus than the urachal fistula inhibited the urachus and the bladder from emptying and urine remaining in the urachus returned to the bladder. The liquid pressure during urination made the diameter of the urachal fistula wider than the urachal

opening at the bladder, resulting in an inability to fully empty the bladder.

There are different surgical options. One is to place intestinal clamps on the apex of the bladder and the urachus and transect between the clamps (Kersjes et al, 1985). Another is to place stay sutures on each side of the bladder near the apex while removing the urine from the bladder by using suction or a syringe (Anderson-Miesner, 2008). The third surgical option is to place stay sutures on either side of the apex of the bladder and clamp the bladder apex cranial to stay sutures with intestinal clamps (Langan et al, 2001). Considering impairment caused by the clamp, the leakage of the urine and the contamination of the inflammatory materials into the abdomen, the second method was selected. It is necessary to examine the inside of the patent urachus for evidence of inflammation and purulent material. In other words, it is better to examine the inside of the urachal lumen by resecting the urachus near the navel after placing stay sutures on either side of the urachus and suctioning the urine before performing surgical procedures previously mentioned.

Dexamethasone is a corticosteroid used to relieve the inflammation. It has few adverse effects if given short-term administration. It was doubtful that dexamethasone resulted in the neurologic signs seen in this calf. Nystagmus or ataxia has not been reported after dexamethasone in cows or calves. The neurological signs increased after the second dose of dexamethasone. Side effects of dexamethasone in human medicine include fluid retention, insomnia, headache, dizziness, nausea, stomach pain, and muscle weakness. In 'Plumb's Veterinary Drug Handbook', it is stated that dexamethasone can cause weight gain, diarrhea, and depression in dogs and cats, and dexamethasone may lead to the development of laminitis in horses (Plumb, 2008). Ataxia and nystagmus in cattle after treatment with dexamethasone has not been described.

ACKNOWLEDGEMENTS

This work was conducted with the support of "Development of genetic selection on immune response for improving the robust of dairy cattle (Project No. PJ01270404)" project of the National Institute of Animal Science, Rural Development Administration, Republic of Korea.

REFERENCES

- Anderson DE, Miesner MD, Abrahamsen EJ, Allen AJ, Anderson DE, Baird AN, Barrington GM, Dawson LJ, Desrochers A, Ewoldt JM, Jones ML, Meylan M, Miesner MD, Morgan GL, Parish SM, Schulz K, Jean GS. 2008. Umbilical Surgery in Calves. p. 473. Veterinary Clinics of North America Food Animal Practice Field Surgery of Cattle Part II. Saunders.
- Anderson DE, Rings DM. 2009. Neonatal Urinary Disorders. pp. 327. Food Animal Practice. 5th ed. W.B. Saunders.
- Divers TJ, Peek S. 2008. Diseases of Body Systems. p. 464. Rebhun's Diseases of Dairy Cattle. 2nd ed. Saunders Elsevier.
- Hunt R, Allen JD. 1989. Treatment of patent urachus associated with a congenital imperforate urethra in a calf. The Cornell veterinarian 79: 157-160.
- Kersjes AW, Németh F, Rutgers LJE. 1985. THE ABDOMEN. pp. 32-33. Atlas of large animal surgery. Williams & Wilkins.
- Langan J, Ramsay E, Schumacher J, Chism T, Adair S. 2001. Diagnosis and management of a patent urachus in a white rhinoceros calf (*Ceratotherium simum simum*). Journal of Zoo and Wildlife Medicine 32: 118-122.
- Lavery P, Salisbury S. 2002. Surgical management of true patent urachus in a cat. Journal of small animal practice 43: 227-229.
- McGavin MD, Carlton WW, Zachary JF. 2001. The urinary system. pp. 271-272. Thomson's special veterinary pathology. 3rd ed.
- Plumb DC. 2008. DEXAMETHASONE. pp. 265-269. Plumb's veterinary drug handbook. PharmaVet Inc, Stockholm, Wisconsin.