



# Intraosseous anesthesia using a computer-controlled system during non-surgical periodontal therapy (root planing): Two case reports

Keumah Han<sup>1</sup>, Jongbin Kim<sup>2</sup>

<sup>1</sup>Department of Periodontology, Sejong Dental Hospital, School of Dentistry, Dankook University, Sejong, Korea

<sup>2</sup>Department of Pediatric Dentistry, School of Dentistry, Dankook University, Cheonan, Korea

Local anesthesia is administered to control pain, but it may induce fear and anxiety. Root planing is a non-surgical periodontal therapy; however, when it is performed in an extensive manner, some tissue removal is inevitable. Notably, this removal may be so painful that local anesthesia is required to be administered to the area scheduled for the treatment. Although patients tend to accept root planing easily, they frequently express a fear of local anesthesia. Intraosseous anesthesia (IA) is an intraosseous injection technique, whereby local anesthetic is injected into the cancellous bone supporting the teeth. A computer-controlled IA system (CIAS) exhibits multiple benefits, such as less painful anesthesia, reduced soft tissue numbness, and the provision of palatal or lingual, as well as buccal, anesthesia via single needle penetration. In this report, we present two cases of root planing that were performed under local anesthesia, using a CIAS.

**Keywords:** Anesthesia, Local; Computer-Assisted; Intraosseous; Root Planing.



This is an Open Access article distributed under the terms of the Creative Commons Attribution Non-Commercial License (<http://creativecommons.org/licenses/by-nc/4.0/>) which permits unrestricted non-commercial use, distribution, and reproduction in any medium, provided the original work is properly cited.



Local anesthesia is administered to control pain, but it may induce fear and anxiety [1,2]. Root planing is a procedure by which residual, embedded subgingival calculus and cementum are removed from tooth roots, thereby producing smooth, hard, and clean root surfaces [3]. When extensive root planing is performed, some pain associated with tissue removal is inevitable. To control the pain, presurgical local anesthesia is administered. Conventional local infiltration anesthesia (CLIA) is typically performed, involving multiple needle penetrations that burden both patients and dentists. Additionally, the duration of anesthesia after treatment is long, which requires patients to endure extended soft tissue numbness. To reduce the pain associated with local anesthesia, many

painless anesthetic devices have been developed that are considered alternatives to conventional anesthesia [4-6]. The administration of intraosseous anesthesia (IA) involves intraosseous injection, whereby local anesthetic is injected into the cancellous bone supporting the teeth. One method for administering intraosseous injections, a computer-controlled IA system (CIAS) (Fig. 1), exhibits some advantages, including less painful anesthesia, reduced soft tissue numbness, and the provision of palatal or lingual, as well as buccal, anesthesia with single needle penetration. However, its disadvantages include additional application time, compared with conventional anesthetic techniques, and shortened duration of the anesthetic effect [7]. Thus, it may be ideal in non-surgical

Received: January 31, 2018 • Revised: February 17, 2018 • Accepted: February 18, 2018

Corresponding Author: Jongbin Kim, Department of Pediatric Dentistry, School of Dentistry, Dankook University, 119 Dandaero, Dongnam-gu, Cheonan, 31116, Korea

Tel: +82-41-550-1921 Fax: +82-44-410-5009 E-mail: jbkim0222@dankook.ac.kr

Copyright© 2018 Journal of Dental Anesthesia and Pain Medicine

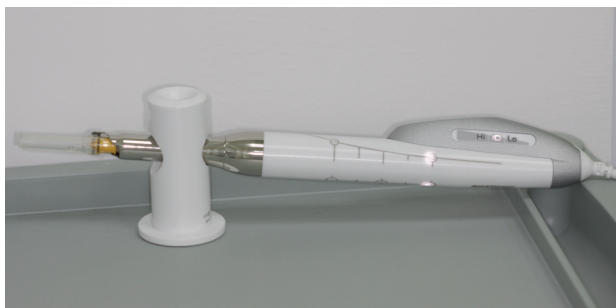

Fig. 1. Computer-controlled anesthetic system (Quicksleeper5®).

procedures, rather than in surgical therapies with long operating times. We report two cases of root planing under local anesthesia, using a CIAS, followed by literature review.

## CASE REPORT

### 1. Case 1

A 60-year-old female patient with moderate chronic periodontitis presented to our department for periodontal therapy (Fig. 2A). Root planing under IA was planned to reduce the pain during local anesthesia because she complained of discomfort during CLIA for periodontal treatment previously. IA using Quicksleeper5® (DHT, Cholet, France) (Fig. 1) was performed within the left mandibular area; a 2% lidocaine solution with 1:100,000 epinephrine was injected using a 27-gauge (0.4-mm diameter) 16-mm Aiguilles® (DHT, Cholet, France) needle. Anesthesia was performed in two stages. First, infiltration anesthesia was administered in the buccal section between the left mandibular lateral incisor and mandibular canine, between the first and second premolars, and between the first and second molars (Fig. 2B). No anesthetic agents were injected into the corresponding lingual section. Next, an intraosseous injection was performed on the anesthetized area. The injection needle was positioned toward the areas between the teeth at approximately 30 degrees to the axis of each tooth (Fig. 2C). When the needle touched the bone, the rotation pedal was pressed to penetrate the cortical bone,

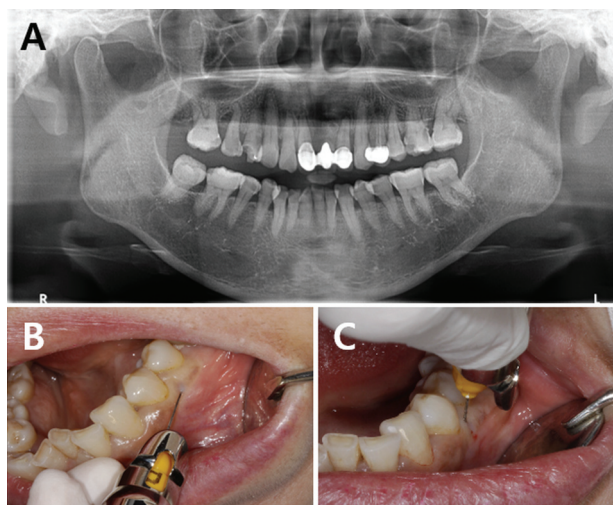


Fig. 2. Intraosseous anesthesia administration in the left mandibular area: (A) panoramic view, (B) infiltration, and (C) intraosseous injection.

and to insert the needle into the cancellous bone. Next, the injection pedal was pressed to inject anesthetic agents in a low-speed mode. The injection dose was monitored on the LED screen of the device; approximately 2.7 ml (1.5 cartridge) of lidocaine was injected. The patient reported pain during infiltration anesthesia (numeric rating scale [NRS]: 3). After the IA, the probing pocket depth was measured using a periodontal probe, and root planing was performed. During root planing, the patient did not complain of any pain. After surgery, the patient did not exhibit paralysis at the surgical sites, and returned home without discomfort.

### 2. Case 2

A 40-year-old male patient visited the Department of Periodontology to undergo root planing for moderate chronic periodontitis (Fig. 3A). The patient had previously complained of severe pain during palatal anesthesia for periodontal treatment of the maxilla. Therefore, root planing of the left maxillary region was planned under local anesthesia, induced by the CIAS. IA was induced in all regions, from the central incisor to the second molar in the left maxilla, using the CIAS Quicksleeper5®. First, 2% lidocaine with 1:100,000 epinephrine and 27-gauge (0.4-mm diameter) was injected between the maxillary lateral incisor and

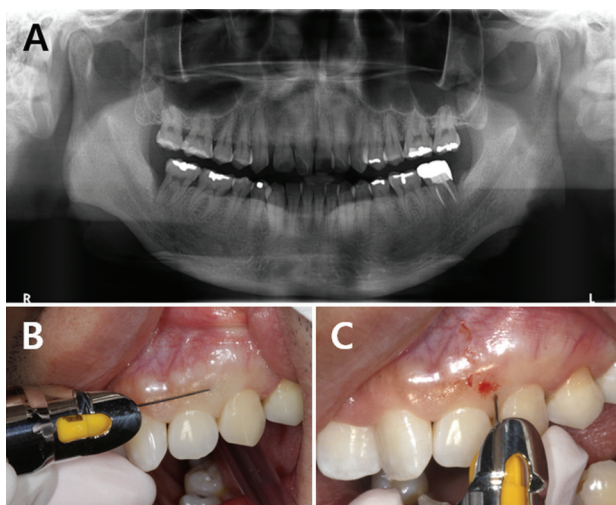


Fig. 3. Intraosseous anesthesia administration in the left maxillary area: (A) panoramic view, (B) infiltration, and (C) intraosseous injection.

maxillary canine, the second premolar and first molar, and on the distobuccal part of the second molar, to induce infiltration anesthesia (Fig. 3B). No anesthetic agents were injected into the palatal region. Next, an injection needle was inserted for intraosseous injection (Fig. 3C). A total of 2.7 ml (1.5 cartridge) lidocaine was used in this procedure. The patient reported pain during infiltration (NRS: 5). After the anesthesia, the probing pocket depth was measured using a periodontal probe, and root planing was performed. The patient did not report significant discomfort during the anesthesia or surgical procedures. After surgery, the patient did not exhibit paralysis at the anesthetized areas and returned home without discomfort.

## DISCUSSION

CIAS-based induction of local anesthesia during non-surgical periodontal therapy was more comfortable, relative to CLIA, for both patients, who had previously undergone CLIA. Pain during the CIAS significantly decreased for both patients, and they were satisfied with the treatment. These results are consistent with those of Rosenberg, who reported that a computer-controlled anesthetic delivery system during periodontal treatment

reduced anxiety associated with local anesthesia, thereby increasing treatment acceptance [8]. Injection needles were inserted into the buccal part in maxilla and mandible. A significant difference in the level of patient pain was observed, compared with CLIA. While the second patient previously experienced extreme pain during the insertion of an injection needle in the palatal region for CLIA induction in the maxilla, the patient reported almost no pain this time. CIAS-based injection of anesthetic agents from the buccal side can anesthetize all regions up to and including the palatal region. In patients exhibiting a deep lingual-vestibular region within the mandible or exhibiting a severe gagging reflex, both operator and patient experience difficulty during the anesthetic procedure [9]; thus, solely anesthetizing the buccal side may be an important advantage.

For both patients, pain was measured using the NRS [10]; neither patient experienced severe pain following anesthesia. Only the first patient reported mild pain between the left mandibular lateral incisor and canine during infiltration. The second patient experienced moderate pain between the left maxillary lateral incisor and canine. Neither patient experienced pain when the intraosseous injections were performed, consistent with previous findings [11]; Coggins et al. investigated the ratios of discomfort ratings during infiltration before intraosseous injection, reporting that 75% of all patients experienced no or mild pain in all regions except the maxillary lateral incisor. Moreover, 85% of all patients experienced no or mild pain during intraosseous injection. Approximately 32% of patients reported moderate pain during the induction of infiltration on the maxillary lateral incisor, consistent with the experience of the second patient in the present study.

Generally, when CLIA is induced, soft tissues of the lips and cheeks, on which the anesthesia is induced, become paralyzed for an extended period, which persists even after surgery completion [12]. However, the patients in this report did not experience soft tissue paralysis beyond the surgically-necessary paralysis of the teeth and gums. Local anesthesia, designed to reduce pain during

a dental procedure, can itself cause stress and complicate dental procedures [8]. Root planing is a non-surgical periodontal treatment that is quickly completed and does not cause significant postoperative pain; therefore, patients do not fear this technique. However, they complain of pain during local anesthesia administered before the treatment, thus causing difficulty for both patients and operators [8]. The CIAS causes less pain than does CLIA during infiltration before intraosseous injections, which is largely because the injection speed is maintained at 1 ml/min by a computer-controlled device. Malamed reported that because anesthetic agents can be injected at a constant rate by an electronic device, electronic injection causes less pain than does conventional, manual methods of injection [2].

The patients experienced almost no pain during treatment, immediately after the induction of anesthesia. The first patient reported slight pain during the root planing of the distobuccal area of the second molar in the left mandible. The second patient reported mild pain during the root planing of the interdental region of the central incisor, but did not require additional anesthetic injections. Coggins et al. [11] emphasized the periodontal bone structure in successful intraosseous injections, as insufficient induction of anesthesia, rather than an insufficient dose of anesthetic agents, is related to bone density. Therefore, they recommended CLIA, rather than increased doses of anesthetic agents, when insufficient anesthesia is induced (following an intraosseous injection) because of high bone density. The areas of mild pain during the treatment for both patients showed high bone densities on X-rays, which may have caused insufficient anesthesia.

In the presently reported cases, the strengths of the intraosseous injection were less painful anesthesia, reduced soft tissue numbness, and small numbers of needle penetration. Pain was significantly reduced when anesthesia was induced using the CIAS. Moreover, because no unnecessary paralysis of the soft tissues occurred, the patients recovered rapidly after IA, compared with CLIA. In this study, induction of local anesthesia using the CIAS

during a non-surgical periodontal therapy significantly reduced anxiety and pain. More detailed studies involving larger sample sizes are warranted to establish the use of the CIAS in actual clinical settings for various purposes.

#### AUTHOR ORCIDs

Keumah Han: <https://orcid.org/0000-0002-6564-6051>

Jongbin Kim: <https://orcid.org/0000-0001-8744-9553>

**DECLARATION OF INTERESTS:** The authors declare that they have no conflicts of interest.

**FUNDING:** This research did not receive any specific grant from funding agencies in the public, commercial, or not-for-profit sectors.

#### REFERENCES

1. Kleinknecht RA, Klepac RK, Alexander LD. Origins and characteristics of fear of dentistry. *J Am Dent Assoc* 1973; 86: 842-8.
2. Malamed SF. *Handbook of local anesthesia-e-book*. 6th ed. Amsterdam, Edited by Elsevier Health Sciences. 2014, pp131.
3. Newman MG, Takei H, Klokkevold PR, Carranza FA. *Carranza's clinical periodontology*. 11th ed. Amsterdam, Edited by Elsevier health sciences. 2011, pp473.
4. Saloum FS, Baumgartner JC, Marshall G, Tinkle J. A clinical comparison of pain perception to the wand and a traditional syringe. *Oral Surg Oral Med Oral Pathol Oral Radiol Endod* 2000; 89: 691-5.
5. Feda M, Al Amoudi N, Sharaf A, Hanno A, Farsi N, Masoud I, et al. A comparative study of children's pain reactions and perceptions to amsa injection using CCLAD versus traditional injections. *J Clin Pediatr Dent* 2010; 34: 217-22.
6. Özer S, Yaltirik M, Kirli I, Yargic I. A comparative evaluation of pain and anxiety levels in 2 different anesthesia techniques: Locoregional anesthesia using conventional syringe versus intraosseous anesthesia using

- a computer-controlled system (quicksleeper). *Oral Surg Oral Med Oral Pathol Oral Radiol* 2012; 114: S132-9.
7. Beneito-Brotons R, Peñarrocha-Oltra D, Ata-Ali J, Peñarrocha M. Intraosseous anesthesia with solution injection controlled by a computerized system versus conventional oral anesthesia: A preliminary study. *Med Oral Patol Oral Cir Bucal* 2012; 17: e426-9.
  8. Rosenberg ES. A computer-controlled anesthetic delivery system in a periodontal practice: Patient satisfaction and acceptance. *J Esthet Restor Dent* 2002; 14: 39-46.
  9. Dickinson C, Fiske J. A review of gagging problems in dentistry: 1. Aetiology and classification. *Dent Update* 2005; 32: 26-8, 31-2.
  10. Hawker GA, Mian S, Kendzerska T, French M. Measures of adult pain: Visual analog scale for pain (VAS pain), numeric rating scale for pain (NRS pain), McGill pain questionnaire (MPQ), short-form McGill pain questionnaire (SF-MPQ), chronic pain grade scale (CPGS), short form-36 bodily pain scale (SF-36 BPS), and measure of intermittent and constant osteoarthritis pain (ICOAP). *Arthritis Care Res (Hoboken)* 2011; 63: S240-52.
  11. Coggins R, Reader A, Nist R, Beck M, Meyers WJ. Anesthetic efficacy of the intraosseous injection in maxillary and mandibular teeth. *Oral Surg Oral Med Oral Pathol Oral Radiol Endod* 1996; 81: 634-41.
  12. Chi D, Kanellis M, Himadi E, Asselin ME. Lip biting in a pediatric dental patient after dental local anesthesia: a case report. *J Pediatr Nurs* 2008; 23: 490-3.