

# Posttraumatic Delayed Vertebral Collapse : Kummell's Disease

Jeongwook Lim, M.D., Seung-Won Choi M.D., Ph.D., Jin-Young Youm, M.D., Ph.D., Hyon-Jo Kwon, M.D., Ph.D.,  
Seon-Hwan Kim, M.D., Ph.D., Hyeon-Song Koh, M.D., Ph.D.

*Department of Neurosurgery, Chungnam National University Hospital, Chungnam National University School of Medicine, Daejeon, Korea*

Posttraumatic delayed vertebral collapse, known as Kummell's disease, is increasing in number of patients. This disease is already progressive kyphosis due to vertebral collapse at the time of diagnosis and it causes intractable pain or neurologic deficit due to intravertebral instability. Treatment is very difficult after progression of the disease, and the range of treatment, in hospital day, and cost of treatment are both increased. Clinical features, pathogenesis and radiologic findings of these disease groups were reviewed to determine risk factors for delayed vertebral collapse. The purpose of this article is to suggest appropriate treatment before vertebral collapse for patients with osteoporotic vertebral compression fracture who have risk factors for posttraumatic delayed vertebral collapse.

**Key Words :** Osteoporosis · Vertebral fracture · Osteonecrosis · Intravertebral cleft · Kummell's disease.

## INTRODUCTION

With the advent of aging society and development of radiological techniques, osteoporotic vertebral compression fracture (OVCF) has become more commonly diagnosed. Among which an increasing number of patients show progressive kyphosis or delayed neurologic compromise without responding to conservative treatments or minimal invasive treatments, including vertebroplasty or kyphoplasty. It is known that the incidence of nonunion is approximately 13.5% and that of intravertebral cleft (IVC) sign is about 7–13% in patients with OVCF<sup>18,33)</sup>.

Also known as Kummell's disease (KD) was defined by avascular necrosis of a vertebral body occurring in a delayed

fashion after minor trauma, this disease requires a more aggressive treatment as opposed to OVCF, because when the disease is diagnosed, vertebral kyphosis and intravertebral instability have already been present with a high degree of vertebral collapse<sup>6,18,22,27,31)</sup>. In 1895, Kummell et al. reported delayed posttraumatic vertebral collapse after asymptomatic minimal spine trauma, which was referred to as KD, and later KD was called by various names such as intravertebral pseudoarthrosis, delayed posttraumatic vertebral osteonecrosis, avascular necrosis of vertebral body, fracture nonunion, IVC, ischemic vertebral collapse, etc.<sup>18)</sup>. As indicated by these confusing names, there is no known guideline for the accurate pathogenesis, radiological diagnosis methods and the best treatments for this disease until now<sup>3,7,18,25,37)</sup>.

• Received : May 19, 2017 • Revised : August 17, 2017 • Accepted : October 19, 2017

• Address for reprints : **Seung-Won Choi, M.D., Ph.D.**

Department of Neurosurgery, Chungnam National University Hospital, Chungnam National University School of Medicine, 282 Munhwa-ro, Jung-gu, Daejeon 35015, Korea  
Tel : +82-42-280-7361, Fax : +82-42-280-7360, E-mail : swchoi@cnu.ac.kr

This is an Open Access article distributed under the terms of the Creative Commons Attribution Non-Commercial License (<http://creativecommons.org/licenses/by-nc/4.0>) which permits unrestricted non-commercial use, distribution, and reproduction in any medium, provided the original work is properly cited.

By referring to various articles, this paper aims to present recently recognized pathogeneses for this disease and help reduce its morbidity by performing reasonable treatments before the development of spinal deformity or instability from KD through early radiological diagnosis.

## CLINICAL FEATURES

The most important clinical feature of KD is delayed vertebral collapse occurring after the history of minimal trauma<sup>5,29</sup>. In most cases, however, the early examination of trauma is not performed due to the lack of symptoms, and vertebral collapse is only confirmed with X-ray performed after symptoms appear<sup>22,35</sup>. When symptoms become gradually serious after the occurrence of asymptomatic trauma, conservative treatment is not that effective, and afterwards, delayed vertebral collapse or intravertebral vacuum cleft occurs<sup>6,22,29,35</sup>. The intervals from the occurrence of asymptomatic trauma, the onset of symptoms, and vertebral collapse vary widely<sup>35</sup>. The most common clinical stages of KD are the three stages of Steel and the five stages of Benedek, although many authors have reported the stages in a varied manner. Among these stages, it is common that there appears an asymptomatic period after initial minor trauma, and then symptoms become gradually serious, and finally intractable pain, vertebral collapse or neurologic compromise occurs in the last phase<sup>5,29</sup>. Neurological deficits rarely appear in the beginning, and vertebral collapse or vertebral pseudoarthrosis occurs only when symptoms become worse, in most cases<sup>5,21,28,35</sup>.

It is considered that KD is more commonly observed in women, given that our clinical experience suggests that OVCF occurs significantly higher in women, although some studies reported that OVCF takes place slightly higher in men among middle-aged adults<sup>35</sup>. The most common site of fracture is the thoracolumbar junction, which is similar to that of OVCF<sup>23,27,35</sup>. A certain authors argued that KD and OVCF are two different diseases based on the ground that both have different injury mechanisms (hyperflexion and lifting, respectively) and show different signals from magnetic resonance image (MRI), and that OVCF rarely presents neurological deficits and is common in men<sup>23,35</sup>. However, this study suggests that KD is a type of complication as well as the end stage of OVCF, because fractures easily occur due to hyperflexion in OVCF as well. The

difference in signals from MRI between the two diseases is due to the discrepancy in the time of fracture, let alone many common aspects between the two diseases.

## PATHOGENESIS

The representative hypothesis for the pathogenesis of KD is delayed healing or nonhealing by osteonecrosis of the fractured vertebrae<sup>16,21</sup>. The pathogenesis for osteonecrosis can be largely divided into two. First, it is caused by anatomical or mechanical damage to the blood vessels supplying the blood to the vertebral body. Normally, the blood supply to the thoracolumbar spine is through the paired segmental arteries, including anterior and posterior central arteries<sup>16</sup>. The former supplies the blood to the anterior 1/3 of the vertebral body, while the latter provides the blood to the lamina and posterior vertebral body. Osteonecrosis easily occurs in the anterior 1/3 of the vertebral body as the site is vulnerable to ischemic injuries because the anterior central artery is short with less collateral vessels formed<sup>16</sup>. Kim et al.<sup>16</sup> estimated that when the midportion of the vertebral body is fractured, the stretching injury of the segmental artery occurs as the cross-sectional area of the fractured spine widens, resulting in vascular insult. This result was not statistically significant but was thought to be due to the small number of subjects in the study. Sugita et al.<sup>30</sup> also reported that the fracture of a midportion type leads to vascular injury as opposed to that of an endplate type. Second, osteonecrosis can occur due to the pathology of the blood vessels supplying the blood to the vertebral body. Table 1 shows the risk factors and possible pathogenesis of osteonecrosis<sup>23</sup>. Chronic alcoholism, chronic steroid therapy and hemoglobinopathy become the risk factors that develop such pathology, and such risk factors cause fat accumulation of the medullary arteriole and develop arteriosclerosis, aggravating the blood supply to the vertebral body<sup>16</sup>. In particular, the fat microembolism that occurs during the fracture blocks the medullary arteriole, worsening the blood supply to the vertebral body. These hypotheses delay neovascularization of the fractured vertebral body, and eventually resulting in non-union or delayed healing of osteonecrosis. It was also reported that the accompanying poor blood supply, Schmorl's node and normal stress prevent bone healing<sup>5</sup>. There is a report that patients with serious osteoporosis show delayed healing

**Table 1.** Clinical risk factors for avascular vertebral necrosis

Risk factors	Possible pathogenesis
Steroid therapy	Fatty tissue accumulation/crushing of the intramedullary vessels/microscopic fat emboli in the end-arteries/secondary osteoporosis
Osteoporosis	Structural failure/ increased intraosseous pressure/vascular compromise
Hemoglobinopathies	Vascular occlusion/ischemia
Vasculitides	Vascular occlusion/ischemia
Post-radiation changes	Direct cytotoxic effect with damage to vascularity
Alcoholism	Microscopic fat emboli in the end-arteries
Cushing's disorder	Microscopic fat emboli in the end-arteries
Pancreatitis	Pancreatic lipase in systemic circulation/Fat necrosis of bone marrow/vascular compression/microscopic fat emboli
Gaucher type 1	Accumulation of glycosyl ceramide in Gaucher cells/marrow infiltration/vascular compromise
Cirrhosis	Unknown
Diabetes	Unknown
Malignancy	Unknown
Infection	Unknown
Sarcoidosis	Unknown

due to the lack of absolute number in osteoblast, and that IVC sign occurs more often when bone mineral density is low<sup>9)</sup>.

However, some authors argued that osteonecrosis can be seen in histopathological examination of the unfractured vertebral body, and it is very rare that it is accompanied by femoral head avascular necrosis<sup>2)</sup>. They emphasized that biomechanical properties are important because intravertebral clefts occur more frequently in thoraco-lumbar junctions and compressed vertebral body itself is related to intravertebral instability<sup>14)</sup>.

We suggest that the fractured vertebral body worsens the watershed zone blood supply of the vertebral body and especially the axial loading at the thoracolumbar junction increases the intravertebral instability due to the progression of the vertebral kyphosis. If the clinical risk factor is accompanied, osteonecrosis can be accelerated. However, it is not known yet which major risk factor accelerates osteonecrosis.

## RADIOLOGIC FEATURES

The most important radiological finding of KD is IVC sign. Since an IVC sign is the poor prognostic factor for delayed vertebral collapse, many radiologic examinations have been conducted for the early detection of this factor. Maldague,

**Table 2.** Radiologic risk factors for progressive vertebral collapse

X-ray	IVC sign Swollen-front type fracture or dented type fracture T-L junction Kyphotic angulation >10 degree Height loss >15% initial value
MRI	IVC sign Midportion type fracture of vertebral body Posterior wall combined fracture Midcolumn injury Confined or diffuse low SI on T2WI

IVC : intravertebral cleft, T-L : thoracolumbar

who first mentioned IVC, suggested that such phenomenon is not commonly observed in neoplasm or infection, while other researchers reported that it can be seen in infection or tumor as well<sup>19,21,28,31)</sup>. However, it was reported that malignancy and infection can be detected with the difference in signals from MRI<sup>34)</sup>. There are also reports that IVC is sometimes observed in OVCF as well, but it is not seen in acute period<sup>19,25)</sup>. The association between IVC sign and KD in osteonecrosis is not clearly known despite a number of previous studies, but IVC sign is an eventual finding that strongly suggests the presence of osteonecrosis, though it is not the pathognomic sign of KD<sup>21)</sup>. Libicher et al.<sup>19)</sup> claimed that IVC was a specific sign of osteonecrosis in vertebral compression fractures, with 85%

sensitivity, 99% specificity, and 91% positive predictive value. There is a theory that the IVC sign from osteonecrosis is caused when it is filled with vacuum gas or when intradiscal vacuum gas enters the intravertebral space. It was suggested that if the content is gas it is mostly nitrogen, while if it is fluid, it is a similar substance with synovial fluid, and that gas and fluid can change depending on body posture<sup>31</sup>). The finding of each radiographic risk factors are summarized in Table 2.

### Simple radiography

Early diagnosis of KD in simple radiography is difficult. However, serial follow images are very useful diagnostic tool (Fig. 1). Serial simple radiography could show deformed vertebral body, progressive compression fracture and kyphosis.

Another feature of KD shown in simple radiography is IVC sign. The IVC sign appears as a transverse, linear or semi-lunar radiopaque shadow of collapsed vertebrae and is more obvious in anteroposterior view, and it is most useful to check IVC sign by inducing intravertebral instability<sup>31</sup>). Since the presence of IVC sign implies intravertebral instability, the IVC sign could be well observed from images such as flexion-extension dynamic simple radiography which induces intravertebral instability (Fig. 2)<sup>8,24</sup>). The standing flexion and extension lateral radiographs, which are most commonly performed, can worsen vertebral fracture because the symp-

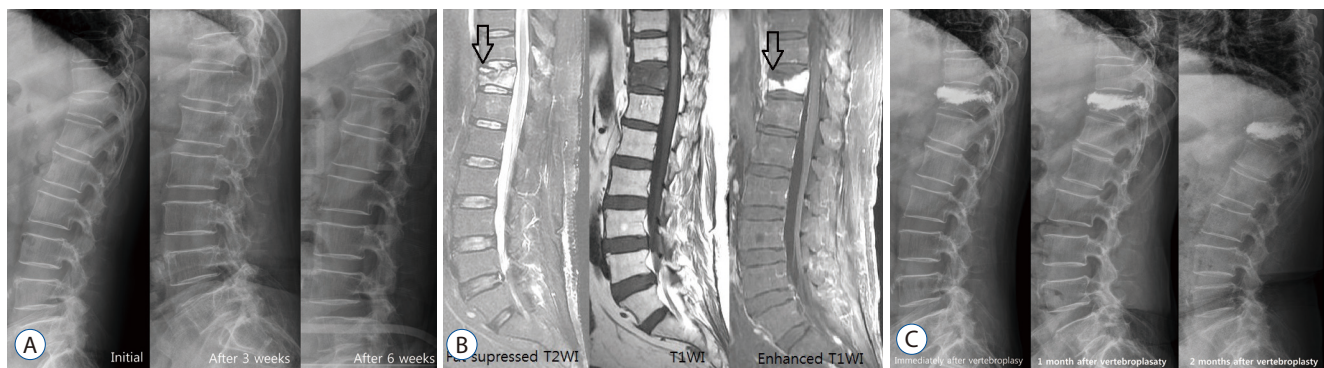
toms can be aggravated in flexion and thus it is hard to get patients' cooperation. McKiernan et al.<sup>24</sup>) suggested the usefulness of supine cross-table lateral radiographs and recommended examination for evaluating dynamic mobility. Cho et al.<sup>8</sup>) suggested the cross lateral radiography was useful in identifying IVC, predicting the degree of restoration of postoperative vertebral heights and wedge angles, and provoked less pain during.

### Computerized tomography (CT)

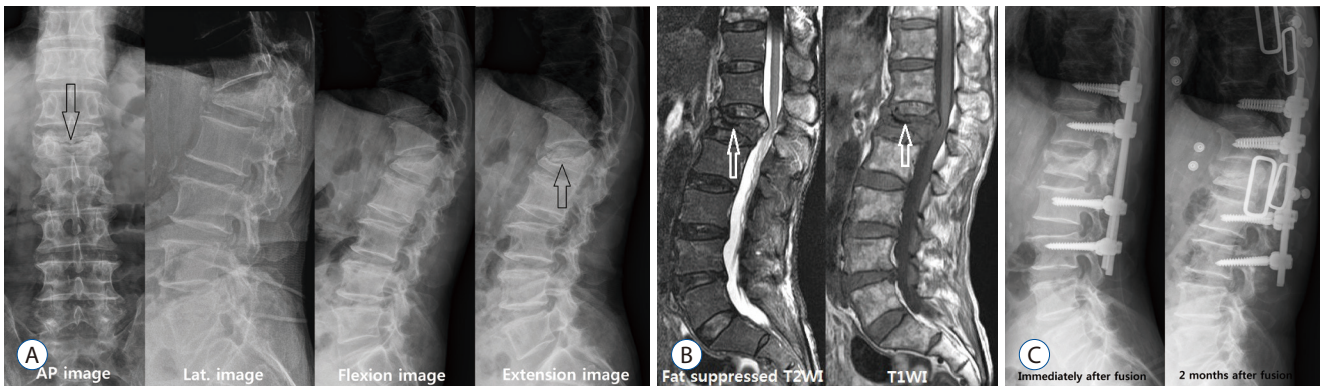
CT can show a clearer finding of bone fracture than X-ray, identify a heterogeneous and irregular shape of bone fragment, and accurately display the involved area of fracture<sup>19,31</sup>). In our experience, dynamic flexion-extension CT is a very useful tool for diagnosing IVC and spinal instability (Fig. 3).

### MRI

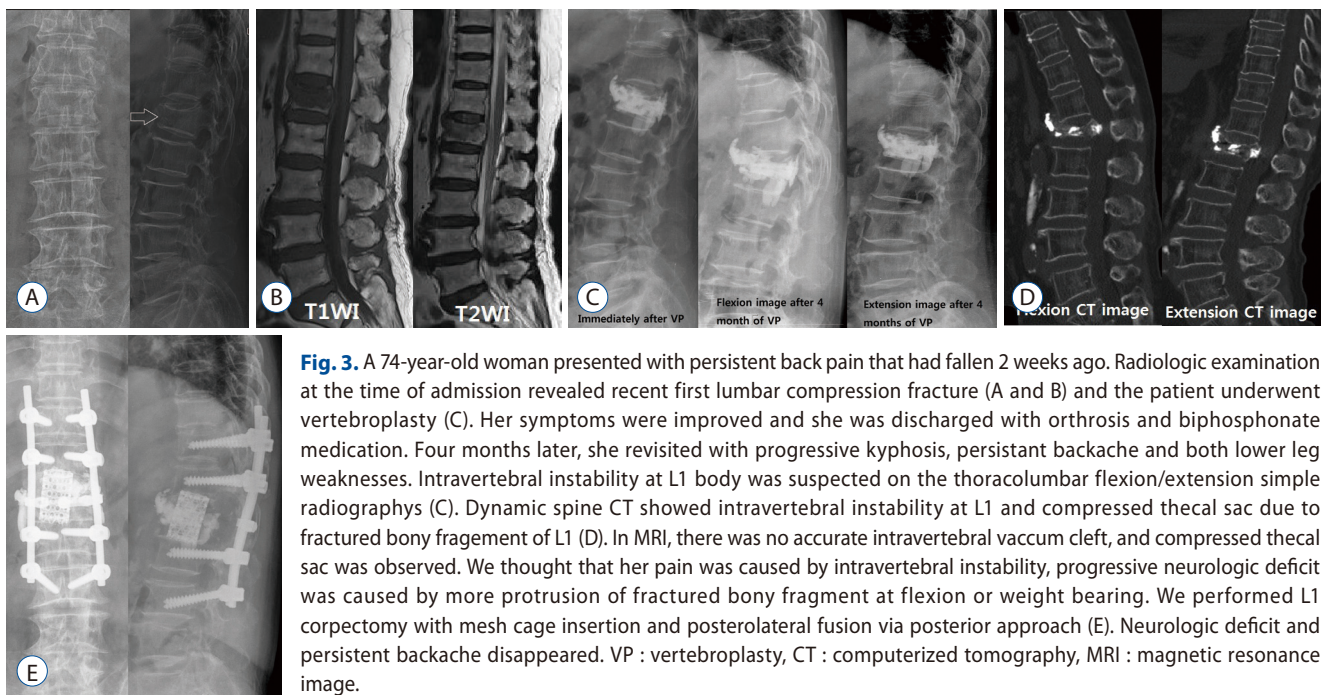
MRI is the most useful diagnostic tool for the diagnosis of vertebral compression fracture and IVC, especially T1 weighted image and fat-suppressed T2 weight image<sup>1,4,13,19,36</sup>). The affected area shows low SI on T1WI and high SI on T2WI in the acute period, and then changes into iso-signal intensity as the bone marrow edema gradually decreases<sup>1</sup>). However, the signals of MRI differ depending on the diagnosis time, and the reported difference in MRI signals significantly vary by authors. Young et al.<sup>35</sup>) reported that osteonecrotic vertebral col-



**Fig. 1.** Case 1. A 62-year-old woman was admitted with severe backache who was suffering from rheumatoid arthritis relying on prednisolone for many years. She was diagnosed with compression fracture of T12. Her had appearance resembling that of the Cushing's, bone mineral density examination showed severe osteoporosis, T score of -3.7. She was followed for 3 weeks with conservative treatment and osteoanabolic agent. However, T12 vertebral compression aggravated in follow up X-ray images and vertebroplasty was performed. However simple radiography, 1 month after the vertebroplasty, showed gradual progression of compression fracture and kyphosis of the T12 vertebrae but the clinical symptoms subsided, so progressive kyphosis was followed up without additional treatment. A : Serial simple spine lateral radiography showed compression fracture of T12 and progressive kyphosis. B : MRI showed high SI in fat suppressed T2WI and diffuse low SI in T1WI of T12. As well as, MRI revealed that the fluid content of the superior endplate of T12 high SI in T2WI and the low SI area of necrotic content (black arrows : IVC sign) and enhancing vertebral body in T1WI enhanced image. C : Postoperative serial simple radiographys showed progressive kyphosis. MRI : magnetic resonance image, IVC : intravertebral cleft.



**Fig. 2.** A 77-year-old man presented with persistent lumbago, progressive kyphosis and radiating pain on both lower extremities lasting about 3 months after minor trauma. He underwent conservative treatment with diagnosis of L1 compression fracture 2 months ago. A : A transverse radiolucent line of IVC sign (black arrow) was observed in anteroposterior view. And the intravertebral pseudoarthrosis and IVC sign (black arrows) were observed in the flexion-extension view. B : Spine MRI showed that typical IVC sign (white arrows) and ventral portion of spinal cord was compressed due to kyphosis. At first, vertebral body replacement was considered, but long level posterolateral fusion was performed due to elder and dementia. C : The restoration of the L1 body was observed in the postoperative image. However, recollapse of the restored L1 body, L3 screw loosening and posterior pull back were observed in the image 1 month after the fusion. AP : anteroposterior view, Lat. : lateral view, IVC : intravertebral cleft, MRI : magnetic resonance image.



**Fig. 3.** A 74-year-old woman presented with persistent back pain that had fallen 2 weeks ago. Radiologic examination at the time of admission revealed recent first lumbar compression fracture (A and B) and the patient underwent vertebroplasty (C). Her symptoms were improved and she was discharged with orthosis and bisphosphonate medication. Four months later, she revisited with progressive kyphosis, persistent backache and both lower leg weaknesses. Intravertebral instability at L1 body was suspected on the thoracolumbar flexion/extension simple radiographs (C). Dynamic spine CT showed intravertebral instability at L1 and compressed thecal sac due to fractured bony fragmentation of L1 (D). In MRI, there was no accurate intravertebral vacuum cleft, and compressed thecal sac was observed. We thought that her pain was caused by intravertebral instability, progressive neurologic deficit was caused by more protrusion of fractured bony fragment at flexion or weight bearing. We performed L1 corpectomy with mesh cage insertion and posterolateral fusion via posterior approach (E). Neurologic deficit and persistent backache disappeared. VP : vertebroplasty, CT : computerized tomography, MRI : magnetic resonance image.

collapse shows increased signal intensity in T1 weight image, while decreased signal intensity in T2 weight image. However, most of studies revealed that osteonecrotic vertebral collapse shows decreased signal intensity in T1 weight image, while in T2 weight image, it displays variable signals, such as high in fluid and low in gas, depending on the contents of IVC<sup>1,4,13,19,31,36</sup>. It was reported that a ‘double line sign’, in which a high signal zone is shown in the center and a low sig-

nal zone in the periphery in T2WI at the fractured vertebral body, is associated with IVC (Fig. 1)<sup>36</sup>. There is also a report that this sign is very similar with the ‘crescent sign’, which is avascular necrosis of the femur<sup>16</sup>. While the early IVC detectability of noncontrast MRI is approximately 60.9%, that of contrast enhancing MRI increases up to 91.3% as the low SI area of necrotic content and enhancing vertebral body can be clearly distinguished, making an early diagnosis possible (Fig. 1)<sup>13</sup>.

In addition to IVC, there is another predictive factor in MRI for delayed vertebral collapse. Ahn et al.<sup>1)</sup> reported that early bone marrow pattern observed on initial MRI was a poor prognostic factor of OVCF if low SI on T1WI. Tsujio et al.<sup>32)</sup> reported that thoracolumbar junction, middle-column injury, and confined or diffuse low SI on T2WI are the predictive factors of nonunion, and in particular that confined low SI on T2WI means repetitive mechanical compression due to a tensile and shearing force, and thus the confined type can be more nonunion than diffuse low SI on T2WI. Ha and Kim<sup>11)</sup> reported that the possibility of progressive vertebral collapse is higher in midportion type fracture and posterior wall combined fracture, as well as when kyphotic angle >10 degrees and height loss >15% of the initial value, and when an IVC sign is present. Sugita also divided osteoporotic spinal fracture by radiologic features and reported that delayed vertebral collapse and IVC can be present in swelled-front type and dented type fractures<sup>30)</sup>.

### Radionuclide bone image

Radionuclide bone imaging is not specific to diagnosing KD, but it is a good modality for screening for many pathologic conditions<sup>20)</sup>. When vascular insufficiency occurs in the bone, osteonecrosis occurs within 12 hours. In the acute phase (<12 hr), a radiopaque effect occurs in the nuchal part of the affected bone, and after the revascularization, there is an intense radiotracer uptake due to active osteoblastic repair<sup>20)</sup>. After bone remodeling, the radiotracer uptake decreases to baseline<sup>20)</sup>. Radionuclide bone images appear to be hot uptake in many KD cases, but rarely have been reported as cold uptake<sup>15)</sup>. Matzaroglou et al.<sup>22)</sup> reported that a single photon emission tomography/computed tomography was performed in KD patients and that the degree of uptake could determine the degree of chronicity.

## TREATMENT

The most important treatment method is a conservative treatment. However, a more aggressive treatment is needed when there is intractable pain, a degree of kyphotic deformity or neurologic compromise<sup>7,17,18,25-27,34,37,38)</sup>. In our institution, if the patient is diagnosed with KD before the vertebral collapse, first of all, conservative treatment with an osteoanabolic agent

should be performed. Considering vertebroplasty (VP) or kyphoplasty (KP) and short segment instrumental screw fixation in patients without severe kyphosis or neurologic compromise and with uncontrollable pain, vertebral replacement is considered in patients with severe kyphosis and neurologic compromise

### Conservative treatment

The most important treatment of OVCF without the presence of neurological deficits is a conservative treatment represented by bed rest, nonsteroidal anti-inflammatory drugs medication and orthosis<sup>7,17,18,25-27,34,37,38)</sup>. As for medication, bisphosphonate, Calcium formula and vitamin D are used, the same as in the treatment of osteoporosis. However, the risk factors of progressive delayed vertebral collapse from MRI do not respond well to conservative treatments in many cases, and thus require a more aggressive treatment. In conservative treatment, about 60% of OVCF patients have improved pain for about 3 months<sup>33)</sup>. In the remaining patients, pain is not controlled or controlled by analgesics<sup>33)</sup>. Although the predictors of chronic pain were unknown, other authors reported that early ambulation and prolonged bed rest also affected bone nonunion<sup>18,33)</sup>. A recent study showed that the osteoanabolic agent, known to be used for the treatment of OVCF, is effective for patients with IVC sign and instability<sup>10)</sup>.

### Minimal invasive treatment

VP and KP can be considered when pain remains or progressive vertebral collapse occurs even after conservative treatments are performed. VP and KP for OVCF are all effective, while KP is effective for reduction of vertebral body height, but there is no significant difference in pain control between VP and KP<sup>3,5)</sup>. Some reported that when an IVC sign is present, polymethyl methacrylate (PMMA) is not an appropriate scaffolding for the fractured vertebral body as PMMA cannot be interdigitated with the trabeculae of the vertebral body, because the fibrocartilaginous membrane is formed inside the IVC, resulting in vertebral compression fracture, which makes intravertebral PMMA be dislodged to the spinal canal, possibly causing neurologic compromise<sup>18)</sup>. However, another author reported that the leakage of PMMA can be reduced due to the fibrocartilaginous membrane during VP<sup>17)</sup>. Since the presence of IVC indicates intravertebral pseudoarthrosis, it can be seen as a good sign to restore collapsed vertebral height.

However, it can also be a bad sign because many authors reported that an IVC sign can imply the leakage of PMMA in the spinal canal. It was reported that PMMA leakage is determined by the presence of IVC sign, viscosity of injected cement, injection volume and velocity, and the morphology of the fractured vertebral body<sup>26)</sup>.

Heo et al.<sup>12)</sup> reported that vertebral recollapse occurs at the rate of approximately 3.2% after VP, suggesting that recollapse takes place when osteonecrosis occurs, or when osteonecrosis is aggravated as the implanted PMMA is a solid lump type. The solid type of implanted PMMA does not interlock with surround normal trabeculae because it does not have biocompatibility and remains as a simple space occupying material<sup>18)</sup>. It develops recollapse, resulting in the aggravation of kyphotic angulation, creating a vicious cycle<sup>18)</sup>. Therefore, if there is osteonecrosis or pseudoarthrosis in the fractured vertebra, VP and KP can be a contraindication<sup>12)</sup>.

It is known that the difference in the effectiveness of VP and KP is not significant, and the correction of kyphotic angle is better in KP than VP, without much significance<sup>3,5)</sup>. It was suggested that it is important to fully fill the cavity using sufficient PMMA by increasing the size of IVC and restoring vertebral body height with the inducement of hyperlordosis during surgery, and it is meaningful to use a cavitogram to check the process<sup>15)</sup>. It was also shown that the distribution of homonymous PMMA can be obtained through VP by inserting the needle in the accurate IVC location with a contrast enhanced MRI<sup>13,25)</sup>. However, it was reported that the larger the restored vertebral height is, the more recollapse occurs (Figs. 1 and 2)<sup>11)</sup>.

## Surigical treatment

Surgical treatments are provided when intractable pain, neurologic deficit or progressive kyphosis is present<sup>7,18,34,37,38)</sup>. The causes of delayed neurologic deficits include progressive kyphosis, retropulsed bony fragment and intravertebral instability, among which the most important cause is intravertebral instability (Figs. 2 and 3)<sup>7,18,34,37,38)</sup>. The surgical outcomes of anterior approach and posterior approach are similar. However, the correction of kyphosis is better in anterior approach than in posterior approach, but its operating time is longer, and has a larger damage to the internal organ and blood loss<sup>34)</sup>. Restoration of the fractured vertebral height is the most important, and the degree of correction of kyphosis is not re-

lated to the degree of pain relief<sup>7)</sup>. However, there are often limitations in deciding the scope and time of surgery because most of patients undergoing this surgery are older, have osteoporosis, and are accompanied by other internal diseases<sup>7,18,34,37,38)</sup>. Although many cases require vertebral body replacement and long level screw fixation, modified surgeries, such as VP or KP with short segmental screw fixation have been recently reported<sup>7,18,34,37)</sup>. This modified surgery is considered to be a suitable method for elderly patients with various diseases and it is reported that the surgical results are very good<sup>7,18,34,37)</sup>. The findings of osteonecrosis or intravertebral pseudoarthrosis from radiologic imaging indicate a higher possibility of delayed vertebral collapse, which is thought to require surgical treatment than conservative treatment or minimal invasive treatment. Like Fig. 3, when progressive vertebral collapse occurs after injecting PMMA in patients with osteonecrosis, vertebral replacement and long segmental screw fixation are required, and thus a more aggressive treatment is needed in the early stage when risk factors are present.

## CONCLUSION

Delayed vertebral collapse after minimal asymptomatic trauma is not a very rare condition, and so far it is thought to be caused by a vascular insult. This disease is considered to be a complication of osteoporotic vertebral compression fracture. If there is a progression to osteonecrosis in the radiological examination at the initial stage of fracture, more active treatment is needed than the treatment of general compression fracture

## PATIENT CONSENT

The patient provided written informed consent for the publication and the use of their images.

## References

1. Ahn SE, Ryu KN, Park JS, Jin W, Park SY, Kim SB : Early bone marrow edema pattern of the osteoporotic vertebral compression fracture : can be predictor of vertebral deformity types and prognosis? **J Korean Neurosurg Soc** 59 : 137-142, 2016

2. Antonacci MD, Mody DR, Rutz K, Weibaecher D, Heggenes MH : A histologic study of fractured human vertebral bodies. **J Spinal Disord Tech** **15** : 118-126, 2002
3. Ates A, Gemalmaz HC, Deveci MA, Simsek SA, Cetin E, Şenköylü A : Comparison of effectiveness of kyphoplasty and vertebroplasty in patients with osteoporotic vertebra fractures. **Acta Orthop Traumatol Turc** **50** : 619-622, 2016
4. Baur A, Stäbler A, Arbogast S, Duerr HR, Bartl R, Reiser M : Acute osteoporotic and neoplastic vertebral compression fractures: fluid sign at MR imaging. **Radiology** **225** : 730-735, 2002
5. Benedek TG, Nicholas JJ : Delayed traumatic vertebral body compression fracture; part II: pathologic features. **Semin Arthritis Rheum** **10** : 271-277, 1981
6. Carlier RY, Gordji H, Mompoint DM, Vernhet N, Feydy A, Vallée C : Osteoporotic vertebral collapse: percutaneous vertebroplasty and local kyphosis correction. **Radiology** **233** : 891-898, 2004
7. Chen L, Dong R, Gu Y, Feng Y : Comparison between balloon kyphoplasty and short segmental fixation combined with vertebroplasty in the treatment of Kümmell's disease. **Pain Physician** **18** : 373-381, 2015
8. Cho JH, Shin SI, Lee JH, Yeom JS, Chang BS, Lee CK : Usefulness of prone cross-table lateral radiographs in vertebral compression fractures. **Clin Orthop Surg** **5** : 195-201, 2013
9. D'ippolito G, Schiller PC, Ricordi C, Roos BA, Howard GA : Age-related osteogenic potential of mesenchymal stromal stem cells from human vertebral bone marrow. **J Bone Miner Res** **14** : 1115-1122, 1999
10. Fabbriani G, Pirro M, Floridi P, Callarelli L, Manfredelli MR, Scarponi AM, et al. : Osteoanabolic therapy: a non-surgical option of treatment for Kümmell's disease? **Rheumatol Int** **32** : 1371-1374, 2012
11. Ha KY, Kim YH : Risk factors affecting progressive collapse of acute osteoporotic spinal fractures. **Osteoporos Int** **24** : 1207-1213, 2013
12. Heo DH, Chin DK, Yoon YS, Kuh SU : Recollapse of previous vertebral compression fracture after percutaneous vertebroplasty. **Osteoporos Int** **20** : 473-480, 2009
13. Ishiyama M, Numaguchi Y, Makidono A, Kobayashi N, Fuwa S, Ohde S, et al. : Contrast-enhanced MRI for detecting intravertebral cleft formation: relation to the time since onset of vertebral fracture. **AJR Am J Roentgenol** **201** : W117-W123, 2013
14. Kim DY, Lee SH, Jang JS, Chung SK, Lee HY : Intravertebral vacuum phenomenon in osteoporotic compression fracture: report of 67 cases with quantitative evaluation of intravertebral instability. **J Neurosurg** **100(1 Suppl Spine)** : 24-31, 2004
15. Kim H, Jun S, Park SK, Kim GT, Park SH : Intravertebral vacuum cleft sign: a cause of vertebral cold defect on bone scan. **Skeletal Radiol** **45** : 707-712, 2016
16. Kim YC, Kim YH, Ha KY : Pathomechanism of intravertebral clefts in osteoporotic compression fractures of the spine. **Spine J** **14** : 659-666, 2014
17. Krauss M, Hirschfelder H, Tomandl B, Licht G, Bär I : Kyphosis reduction and the rate of cement leaks after vertebroplasty of intravertebral clefts. **Eur Radiol** **16** : 1015-1021, 2006
18. Lee SH, Kim ES, Eoh W : Cement augmented anterior reconstruction with short posterior instrumentation: a less invasive surgical option for Kümmell's disease with cord compression. **J Clin Neurosci** **18** : 509-514, 2011
19. Libicher M, Appelt A, Berger I, Baier M, Meeder PJ, Grafe I, et al. : The intravertebral vacuum phenomenon as specific sign of osteonecrosis in vertebral compression fractures: results from a radiological and histological study. **Eur Radiol** **17** : 2248-2252, 2007
20. Love C, Din AS, Tomas MB, Kalapparambath TP, Palestro CJ : Radionuclide bone image: an illustrative review. **Radiographics** **23** : 341-358, 2003
21. Maldague BE, Noel HM, Malghem JJ : The intravertebral vacuum cleft: a sign of ischemic vertebral collapse. **Radiology** **129** : 23-29, 1978
22. Matzaroglou C, Georgiou C, Assimakopoulos K, Giannakenas C, Karageorgos A, Saridis A : Kümmell's disease: pathophysiology, diagnosis, treatment and the role of nuclear medicine. Rationale according to our experience. **Hell J Nucl Med** **14** : 291-299, 2011
23. Matzaroglou C, Georgiou CS, Panagopoulos A, Assimakopoulos K, Wilke HJ, Habermann B, et al. : Kümmell's disease: clarifying the mechanisms and patients' inclusion criteria. **Open Orthop J** **8** : 288-297, 2014
24. McKiernan F, Jensen R, Faciszewski T : The dynamic mobility of vertebral compression fractures. **J Bone Miner Res** **18** : 24-29, 2003
25. Nakamae T, Fujimoto Y, Yamada K, Takata H, Shimbo T, Tsuchida Y : Percutaneous vertebroplasty for osteoporotic vertebral compression fracture with intravertebral cleft associated with delayed neurologic deficit. **Eur Spine J** **22** : 1624-1632, 2013
26. Nieuwenhuijse MJ, Van Erkel AR, Dijkstra PS : Cement leakage in percutaneous vertebroplasty for osteoporotic vertebral compression fractures: identification of risk factors. **Spine J** **11** : 839-848, 2011
27. Niu J, Song D, Zhou H, Meng Q, Meng B, Yang H : Percutaneous Kyphoplasty for the treatment of osteoporotic vertebral fractures with intravertebral fluid or air: a comparative study. **Clin Spine Surg** **30** : 367-373, 2016
28. Sarli M, Pérez Manghi FC, Gallo R, Zanchetta JR : The vacuum cleft sign: an uncommon radiological sign. **Osteoporos Int** **16** : 1210-1214, 2005
29. Steel HH : Kümmell's disease. **Am J Surg** **81** : 161-167, 1951
30. Sugita M, Watanabe N, Mikami Y, Hase H, Kubo T : Classification of vertebral compression fractures in the osteoporotic spine. **J Spinal Disord Tech** **18** : 376-381, 2005
31. Theodorou DJ : The intravertebral vacuum cleft sign. **Radiology** **221** : 787-788, 2001
32. Tsujio T, Nakamura H, Terai H, Hoshino M, Namikawa T, Matsumura A, et al. : Characteristic radiographic or magnetic resonance images of fresh osteoporotic vertebral fractures predicting potential risk for non-union: a prospective multicenter study. **Spine (Phila Pa 1976)** **36** : 1229-1235, 2011
33. Venmans A, Klazen CA, Lohle PN, Mali WP, van Rooij WJ : Natural history of pain in patients with conservatively treated osteoporotic vertebral compression fractures: results from VERTOS II. **AJNR Am J Neuroradiol** **33** : 519-521, 2012
34. Wang F, Wang D, Tan B, Dong J, Feng R, Yuan Z, et al. : Comparative study of modified posterior operation to treat Kümmell's disease. **Medi-**



- cine (Baltimore) 94** : e1595, 2015
35. Young WF, Brown D, Kendler A, Clements D : Delayed post-traumatic osteonecrosis of a vertebral body (Kummell's disease). **Acta Orthop Belg 68** : 13-19, 2002
  36. Yu CW, Hsu CY, Shih TT, Chen BB, Fu CJ : Vertebral osteonecrosis: MR imaging findings and related changes on adjacent levels. **AJNR 28** : 42-47, 2007
  37. Zhang GQ, Gao YZ, Zheng J, Luo JP, Tang C, Chen SL, et al. : Posterior decompression and short segmental pedicle screw fixation combined with vertebroplasty for Kümmell's disease with neurological deficits. **Exp Ther Med 5** : 517-522, 2013
  38. Zhang X, Hu W, Yu J, Wang Z, Wang Y : An effective treatment option for Kümmell disease with neurological deficits: modified transpedicular subtraction and disc osteotomy combined with long-segment fixation. **Spine (Phila Pa 1976) 41** : E923-E930, 2016