

Retinal Function Analysis and Histopathologic Assessment after Intravitreal Cidofovir Injection in Normal Beagle Dogs

Sungwon Park, Seonmi Kang, Sangwan Park, Jiseok Han*, Yongbum Kim* and Kangmoon Seo¹

Department of Veterinary Clinical Sciences, College of Veterinary Medicine, Seoul National University, Seoul 08826, Korea

*Pathology Research Center, Korea Institute of Toxicology, Daejeon 34114, Korea

(Received: July 25, 2017 / Accepted: September 30, 2017)

Abstract : This study was performed to evaluate the effects of an intravitreal injection of cidofovir in beagle dogs. Nine beagle dogs (18 eyes) were used and randomly assigned to the following three groups of various dosages: 100, 500 and 1000 µg. Aqueous paracentesis was followed by an intravitreal injection of cidofovir. Intraocular pressure (IOP) was measured twice a week and electroretinography (ERG) and ophthalmoscopic examination were performed every week during the study. At the end of the study, all eyes were enucleated for histopathologic evaluation after euthanasia. The IOPs in the 500 and 1000 µg groups were statistically lower than baseline with no significant IOP changes in the 100 µg group. Reduced amplitudes of ERG recordings were identified in the eyes injected with higher dose groups than the 100 µg group. Histopathologic examination revealed that there were dose-related toxicities to the ciliary body and the retina. These results suggest that intravitreal cidofovir had dose-dependent IOP lowering effects associated with ciliary body destruction, but had the potential to cause retinal toxicity in beagle dogs.

Key words : cidofovir, chemical ablation, IOP, glaucoma, dog.

Introduction

Glaucoma is defined as a group of diseases showing the intraocular hypertony accompanied by disruption of physiological retinal function. Progression of glaucoma was known as being associated with persisted elevation of intraocular pressure, leading to chronic glaucoma suffered from secondary ocular illness including intraocular inflammation, buphthalmos, and exposure keratitis (8,12). Most cases of chronic glaucoma in small animals ultimately required surgical management due to the limitation of long-term control for intraocular pressure. Surgery for chronic glaucoma was focused on the pain reduction and cosmetic appearance. Chemical cycloablations with gentamicin injected intravitreally, evisceration with intraocular prosthesis, and enucleation were reported as salvage procedures following chronic glaucoma (8,11,12). Recently, one study reported the hypotensive effects of intravitreal cidofovir injections in dogs with chronic glaucoma (11).

Cidofovir [(S)-1-(3-hydroxy-2-phosphonylmethoxypropyl) cytosine; (S)-HPMPC] has been used as an anti-viral medication for human patient with cytomegaloviral retinitis (10,11,14). Cidofovir for humans was well-tolerated by intravitreal injection for decreasing systemic absorption and renal toxicity (13,16). Though intravitreal injection of cidofovir was useful for therapy for AIDS-related cytomegalovirus retinitis, it has been found to induce the side effects of ocular hypotony compared with baseline (2,16,17).

The histopathologic studies of the eyes injected with cido-

fovir intravitreally in various animals showed dose-related intraocular toxicity (3,15). Intravitreal injections of cidofovir have been found to be toxic to the ciliary body and retina in guinea pigs and rabbits. Although several studies showed that intravitreal cidofovir decreased IOP, presumably because of its destruction of the ciliary body, its effect on the retina has not been investigated in dogs yet.

Therefore, the aim of this study was to investigate dose-related changes in retinal function and histopathology in normal beagle eyes injected with cidofovir.

Materials and Methods

Experimental animals

Both eyes of 9 healthy beagle dogs were included in the current study. Seven of the dogs were male and 2 were female. The mean age was 3.4 ± 0.2 years. Each of the 18 eyes was randomly divided into 3 groups that were given different doses of cidofovir; 100 µg (A), 500 µg (B), and 1000 µg (C). Prior to beginning the experiment, the dogs underwent complete ophthalmic examinations including slit-lamp biomicroscopy (SL-D7[®], Topcon, Japan), indirect ophthalmoscopy (Vantage Plus[®], Keeler Ltd., UK), rebound tonometry (Tonovet[®], Icare Finland, Finland), and electroretinogram (Reti-com[®], Roland Instrument, Germany) to ensure clinically normal eyes. All care and experimental procedures were confirmed to the Institutional Animal Care and Use Committee (IACUC) of Seoul National University (SNU-131213-1).

Preparation of the drug

The cidofovir (C5874, Sigma-Aldrich, USA) was dissolved

¹Corresponding author.
E-mail : kmseo@snu.ac.kr

in sterile, nonbacteriostatic, and nonpyrogenic 0.9% sodium chloride (NaCl, Daihan Pharm. Co. Ltd., South Korea). Sodium hydroxide (NaOH) was added to solubilize the drug leading to the final pH of 7. Then, 0.9% NaCl was added to the solution to reach the calculated volume (final concentrations of 1, 5, and 10 mg/ml) and filtered through a sterile syringe with a 0.22 μm nylon, sterile, and nonpyrogenic syringe filter (Minisart[®], Sartorius Stedim Biotech, Germany). The prepared solution was aliquot into 0.5 ml insulin syringes and randomly injected into the beagles' eyes. In all groups, the volume of solution injected was 0.1 ml.

Electroretinography

ERG was performed under a dim red light in a dark room. After producing mydriasis with 1% tropicamide (Mydriacyl[®], Alcon, South Korea), the animals were adapted to the dark for 20 min. All of the dogs were anesthetized with 5 $\mu\text{g}/\text{kg}$ of medetomidine (Domitor[®], Orion Pharm, Norway) and 1.25 mg/kg of a combination of zolazepam/tiletamine (Zoletil[®], Virbac, Australia) by intravenous injections prior to electroretinography (ERG). The ground electrode was positioned over the external occipital protuberance, with the reference electrode positioned at approximately 2 cm caudal to the lateral canthus. The contact lens electrode (ERG-jet[®], Fabrinol SA, Switzerland) was located on the cornea following topical anesthesia with 0.5% proparacaine (Alcaine[®], Alcon, Belgium) and lubrication with 2% hypromellose (Hycell[®], Samil, South Korea). ERG was performed on bilateral eyes at equal intensity (2.5 $\text{cd}\cdot\text{s}/\text{m}^2$). Responses were analyzed for a- and b-wave amplitudes and implicit times.

Intravitreal injection

The trial was designed as a prospective, randomized, observer-masked study. The IOP and ERG were recorded at baseline for the beagle dogs. A full ophthalmic examination was always performed at the time of injection using dilated indirect ophthalmoscopy and fundus photography.

All dogs were intravenously injected with tramadol 2 mg/kg (Tradol[®], BTO pharm, South Korea) for analgesia. Topi-

cal proparacaine was instilled before the intravitreal injection. Aseptic ocular surface was prepared for injection by cleansing with 0.5% povidone-iodine solution. Aqueous paracentesis was performed to decrease IOP for minimizing postinjection leakage and ocular pain during the intravitreal injection. The needle was inserted into the cornea just rostral to the limbus and parallel to the anterior border of the iris avoiding contacting the iris and corneal endothelium. Intravitreal injection of cidofovir was performed through the 5 mm posterior to the superior limbus and was directed posterior and toward center of globe. After the intravitreal injection, 4 mg of triamcinolone (Rheudenolone[®], Kukje Pharma, South Korea) and gentamicin (Gentapro[®], Huons, South Korea) was administered subconjunctivally. All dogs were treated with neomycin-polymyxin B-dexamethasone solution (Maxitrol[®], Alcon, Belgium) every 12 h for 2 weeks. Twice a week, IOPs were measured between 6 and 7 PM. Visual assessment was determined by the abnormality of the menace response, visual placing, dazzle reflex, and pupillary light reflex. ERG and slit-lamp examination were performed once a week with dilated pupils. At the end of 4 weeks, the beagles were euthanized and their eyes were enucleated for histopathologic evaluation.

Histopathologic evaluation

Enucleated eyes were placed in a mixture of freshly prepared Davidson's solution (2% paraformaldehyde, 10% glacial acetic acid, 35% ethanol, and 53% distilled water). After 48 h, the solution was changed to 70% ethanol. The eyes were processed through graded alcohols and xylene and embedded in paraffin. For histopathologic analysis, 5 μm vertical sections of the pupil and optic nerve were obtained every 200 μm and stained with hematoxylin and eosin.

Statistical analyses

The results were expressed as mean \pm standard deviation. The statistical analyses were performed using statistical software (SPSS[®] ver.21 for Windows, IBM, USA). If significance was achieved by repeated analysis of variance measurements,

Table 1. Intraocular pressure (IOP) of baseline and post cidofovir injections in beagle eyes

Days	A (100 $\mu\text{g}/\text{eye}$)		B (500 $\mu\text{g}/\text{eye}$)		C (1000 $\mu\text{g}/\text{eye}$)	
	IOP (mmHg)	% drop**	IOP (mmHg)	% drop	IOP (mmHg)	% drop
Baseline	16.8 \pm 2.1*		16.1 \pm 2.0		15.8 \pm 0.9	
3	14.4 \pm 1.9	14.2	14.2 \pm 2.2 [†]	11.7	12.4 \pm 1.1 [‡]	21.7
7	14.4 \pm 2.5	13.9	12.8 \pm 1.2 [‡]	20.3	9.6 \pm 2.3 [‡]	39.7
10	14.2 \pm 2.7	15.6	12.1 \pm 1.9 [‡]	25.2	7.9 \pm 2.9 [‡]	49.8
14	14.5 \pm 4.0	13.6	12.6 \pm 0.9 [‡]	21.7	8.8 \pm 2.7 [‡]	44.2
17	15.2 \pm 4.1	9.6	12.7 \pm 0.9 [‡]	21.4	9.1 \pm 2.0 [‡]	42.5
21	15.4 \pm 1.9	8.3	13.6 \pm 1.1 [‡]	15.8	10.0 \pm 2.5 [‡]	36.8
24	15.8 \pm 3.1	5.6	14.1 \pm 0.7 [†]	12.8	10.3 \pm 2.7 [‡]	35.1
28	15.9 \pm 2.6	5.3	14.2 \pm 1.3 [†]	12.1	10.3 \pm 2.4 [‡]	34.7

*mean \pm SD; ** Percentage drop in IOP from baseline; [†]Significantly lower than baseline ($P < 0.05$);

[‡]Significantly lower than baseline ($P < 0.001$).

the Bonferroni post-hoc test was applied, considering values of $P < 0.05$ statistically significant. The P values lesser than 0.001 was considered extremely statistically significant.

Results

Intraocular pressure changes

No significant IOP changes were observed compared with baseline in Group A. The IOPs in Groups B and C were statistically lower than baseline three days later (Table 1). In Groups B and C, the lowest IOP was measured on day 10 (25.2% and 49.8% of baseline, $P < 0.001$, respectively). IOP was estimated as a lowest value on day 10 and increased slightly thereafter in all groups (Table 1). There were no statistically significant differences between Groups B and C.

Ophthalmic examination findings

Intravitreal injections in Group A produced no remarkable ophthalmoscopic findings during the study period (Fig 1A). In Group B, intravitreal cidofovir caused moderate conjunctival hyperemia with mild aqueous flare until 7 days. Fundus examination showed mild tapetal hyperreflectivity at 28 days in Group B (Fig 1B and Table 2). Furthermore, at 28 days, some of the eyes showed a delayed response to visual assessments such as the menace and visual placing, but vision was present until the end of the study. In Group C, intravitreal cidofovir caused more toxic effects than were observed in the other groups. The eyes developed moderate to severe conjunctival hyperemia, aqueous flare, and hyalitis at 7 days,

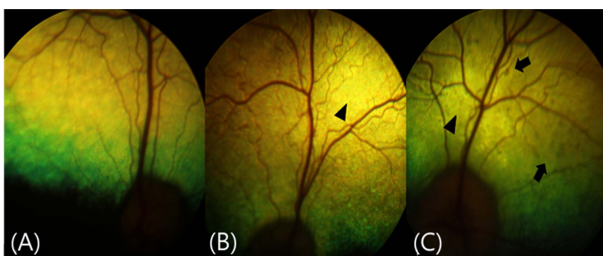


Fig 1. Fundus examination on 28 days. (A) Fundus image of Group A showed no significant abnormalities. (B) Mild tapetal hyperreflectivity (arrowhead) in Group B. (C) Light-brownish pigments (arrow) on the retina and moderate hyperreflectivity (arrowhead) of the tapetum in Group C.

Table 2. Fundus image changes on day 28 after intravitreal cidofovir injection in beagle eyes

Groups	Tapetal hyperreflectivity			Pigment deposit		
	Mild	Moderate	Severe	Mild	Moderate	Severe
A	0/6*	0/6	0/6	0/6	0/6	0/6
B	4/6	1/6	0/6	2/6	1/6	0/6
C	0/6	3/6	3/6	1/6	4/6	1/6

*Number of eyes showing fundic changes / Total number of eyes (n = 6)

followed by the moderate peripheral deposit of pigment and tapetal hyperreflectivity at 28 days (Fig 1C and Table 2). Among them, three eyes had no menace response and visual placing reaction. There were no cataractogenic findings in any of the eyes treated with cidofovir. A conjunctival hemorrhage caused by injection trauma was present in 3 eyes, but it was not dose-related, and the blood was naturally absorbed within a week.

Electroretinogram

There was no statistically significant change in Group A. Intravitreal injections of cidofovir in group B statistically reduced both a- and b-wave amplitudes at 14 days ($P < 0.001$, Fig 2). Group C showed that amplitude had been significantly decreased after 7 days compared to baseline ($P < 0.001$, Fig 2). Most of the eyes in Group C had remarkably flat amplitudes of both a- and b-waves at the end of study. There were no statistically significant differences in Groups B and C. The amplitude of waves in Group A were statistically different from other groups. There were no significant changes in the implicit time of waves during the study period in all groups.

Histopathology

The ciliary body and retina of the eyes in Group A were within normal limits until 28 days (Figs 3A and 4A). Injections of cidofovir in Group B caused mild attenuation of the pars plicata, disruption of the pigment epithelium (PE) in the ciliary process, infiltration of monocytes in the stroma of the ciliary body (Fig 3B), and mild migration of pigment cells into the photoreceptor layer (Fig 4B). In Group C, intravitreal injections of cidofovir caused moderate disruption of the

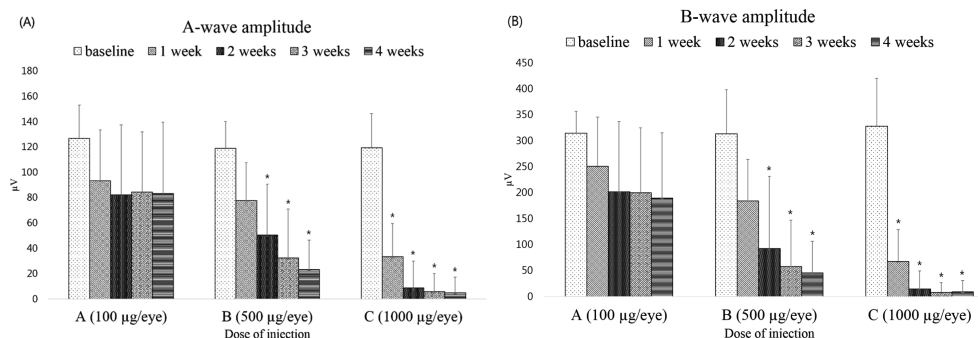


Fig 2. Changes in the amplitude of electroretinogram (ERG) in each group after intravitreal cidofovir injections in beagle eyes. (A), Amplitude of a-wave; (B), Amplitude of b-wave. *: $P < 0.001$.

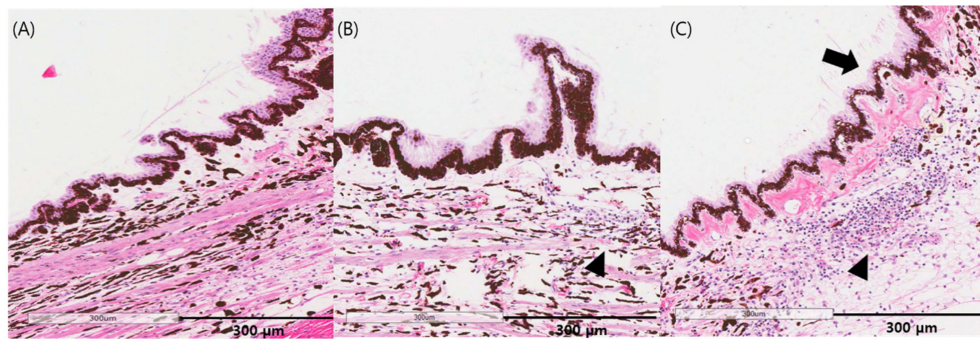


Fig 3. Histopathologic changes of the ciliary body after intravitreal cidofovir injections in beagle eyes. H&E stain. (A) No remarkable findings in Group A. (B) Mild disruption of pigment epithelium and infiltration of monocytes in the stroma of the ciliary body (arrow head) in Group B. (C) Moderate disruption of pigment epithelium in the ciliary processes (arrow head), moderate-to-severe infiltration of monocytes (arrow) and pigment-laden cells in the stroma of the ciliary body in Group C.

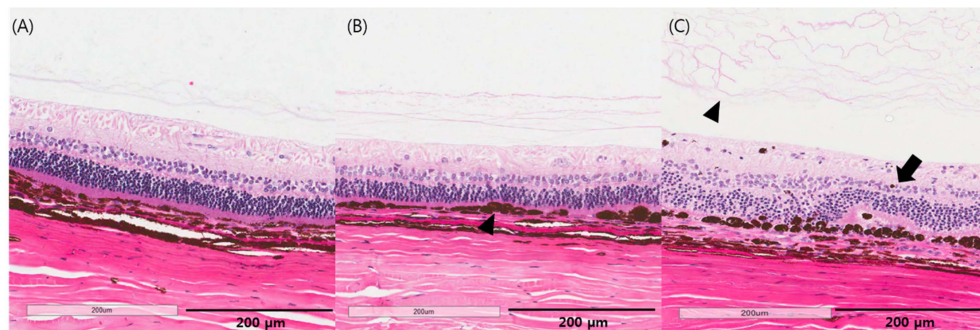


Fig 4. Histopathologic evaluation of the retina after cidofovir injection. (A) No remarkable findings in Group A. (B) Mild migration of pigment into the photoreceptor layer (black arrow head) in Group B. (C) Moderate-to-severe migration of pigment cells into the outer retina segment, photoreceptor layer degeneration with retinal fold (arrow) and fibrinous materials in the vitreous body (blacked arrow head) in Group C.

PE and the infiltration of monocytes and pigment-laden cells in the ciliary body and fibrous materials in the vitreous body (Figs 3C and 4C). Furthermore, there was moderate to severe disruption of the retinal pigment epithelium (RPE), pigmented cell migration, and degeneration of outer retinal architecture with retinal fold (Fig 4C).

Discussion

Even though cidofovir has been used in antiviral medication for viral retinitis in humans, cidofovir has an intraocular hypotensive effect (2,15). Furthermore, one study showed that intravitreal injections of 561.5 μg of cidofovir had an IOP-lowering effect (78% lower than baseline) in dogs with chronic glaucoma (11).

A study of vitreous volume in various animals suggested that the mean vitreous volume of dog eyes was 1.7 ± 0.86 ml (9). In this study, injections of 100, 500, and 1000 μg of cidofovir (final vitreous concentrations of 58.8, 294, and 588 $\mu\text{g}/\text{ml}$, respectively) were performed intravitreally. In all groups, the IOP values were lowest at day 10, although it's not significant in Group A. It was considered that post-treatment uveitis might be associated with the lowered IOP. Doses of 500 and 1000 μg of cidofovir (final vitreous concentrations of 294 and 588 $\mu\text{g}/\text{ml}$, respectively) resulted in the perma-

nent reduction of IOP. In guinea pigs, intravitreal injections of 50 and 156.25 μg of cidofovir (final vitreous concentrations of 200 and 625 $\mu\text{g}/\text{ml}$, respectively) statistically decreased IOP (53 and 70% lower than baseline, respectively) (15). In rabbit eyes, intravitreal injections of 875 and 2800 μg of cidofovir (final vitreous concentrations of 625 and 2000 $\mu\text{g}/\text{ml}$, respectively) lowered IOP (26 and 11% of baseline, respectively) without significant differences (15). These results suggest that cidofovir's IOP-lowering effect was stronger in guinea pigs than beagles or rabbits. Furthermore, glaucomatous eyes were more susceptible to the hypotensive effect of cidofovir than normal eyes (11).

The loss of both a- and b-wave amplitudes in all eyes suggested that cidofovir was toxic to the retinal structure. The amplitude of a- and b-waves relates to the function of photoreceptors and müller cells, respectively (6). Thus, the loss of amplitude in this study indicates that intravitreal cidofovir decreased the retinal function associated with retinal degeneration. However, one study showed that subcutaneous injections of cidofovir retained the amplitudes of ERG and improved the clinical signs because of suppression of the viral replication in a murin model of ocular cytomegalovirus disease (7). These paradoxical results might be related to differences in subjects and routes of drug administration.

Histopathologic evaluation in this study showed that intra-

ocular pathologic changes occurred in a dose-dependent manner. Disruption of pigment epithelium (PE) in ciliary processes and the infiltration of monocytes suggested that intravitreal cidofovir had destructive effects on the ciliary body. Retinal degeneration in Groups B and C was related to the loss of both a- and b-wave amplitudes in the electroretinography (6). Intravitreal injections of cidofovir in Group C (final vitreous concentration of 588 µg/ml) markedly exacerbated the degeneration of retinal architecture and the accumulation of pigment in the photoreceptor layer. Taskintuna et al. (15) showed that 156.25 µg of cidofovir (final vitreous concentration of 625 µg/ml) caused no remarkable changes in the ciliary body and retina in rabbits. Thus, rabbit retinas appeared more resistant to the toxicity of cidofovir than those of beagles or guinea pigs.

Many studies demonstrated that intravitreal saline injection did not induced remarkable intraocular changes in various animals (3,15). Therefore, ablation of the ciliary body and retinal destruction were induced by not sodium chloride but cidofovir. In addition, sodium hydroxide was added to cidofovir solution for balancing the pH of solution so as its the limit acidic damages into intraocular tissues (3,11,15).

The accumulation of irregular light-brownish pigmented spots in the tapetal fundus and hyperreflectivity have been well-documented typical fundus appearances of central progressive retinal atrophy (cPRA) in dogs (1). Retinal degeneration in the cPRA has been related to retinal pigment epithelium (RPE) disruption (4). Vitamin E deficiency might play a role in the development of cPRA (5), and the pathogenesis was quite different from pigment accumulation in this study. The RPE photoreceptor complex could be exposed to oxidative stress-associated free radical formation and lipid peroxidation (19). Pathological studies showed that the main source of vision loss was the level of photoreceptor; however, it was considered that photoreceptor loss was secondary to the damage to RPE cells which would be the primary injury site (18). Thus, dose-related degeneration of the retinal outer segment in Groups B and C might be related to the RPE disruption and lipid peroxidation caused by oxidative stress related to intravitreal cidofovir.

Limitations of the current study include using both eyes for different dose injection and dividing groups by inappropriate doses. Both eyes were injected with randomly selected doses. However, intraocular changes in the IOP, amplitudes of ERG and histopathology in Group A (100 µg/eye) were not influenced by the doses of cidofovir into contralateral eyes in spite of each dose higher than 100 µg/eye of Group A. Thus, we thought that intravitreal cidofovir did not affect to function and structure of contralateral eye. Based on data from this study, a further study using other various doses of cidofovir between 100 and 500 µg would be needed to determine whether the IOP decreases but the retinal function can be maintained.

Conclusion

This study showed that intravitreal injections of cidofovir (more than 500 µg) had not only a hypotensive effect resulting from the destruction of the ciliary body, but also caused

vision loss due to retinal toxicity in beagle eyes. Thus, intravitreal injections of cidofovir for hypotensive effects in clinical cases might require doses greater than 500 µg and should be applied irreversibly blind dogs because of the drug's retinal toxicity.

Acknowledgment

This study was supported through BK21 PLUS Program for Creative Veterinary Science Research and the Research Institute for Veterinary Science (RIVS) of Seoul National University, Korea.

References

1. Aguirre GD, Laties A. Pigment epithelial dystrophy in the dog. *Exp Eye Res* 1976; 23: 247-256.
2. Banker AS, Arevalo JF, Munguia D, Rahhal FM, Ishimoto B, Berry C, De Clercq E, Ochabski R, Taskintuna I, Freeman WR. Intraocular pressure and aqueous humor dynamics in patients with AIDS treated with intravitreal cidofovir (HPMPC) for cytomegalovirus retinitis. *Am J Ophthalmol* 1997; 124: 168-180.
3. Banker AS, De Clercq E, Taskintuna I, Keefe KS, Bergeron-Lynn G, Freeman WR. Influence of intravitreal injections of HPMPC and related nucleoside analogues on intraocular pressure in guinea pig eyes. *Invest Ophthalmol Vis Sci* 1998; 39: 1233-1242.
4. Bedford PG. Retinal pigment epithelial dystrophy in the Briard. *Vet Rec* 2009; 12: 377.
5. Davidson MG, Geoly FJ, Gilger BC, McLellan GJ, Whitley W. Retinal degeneration associated with vitamin E deficiency in hunting dogs. *J Am Vet Med Assoc* 1998; 5: 645-651.
6. Ekesten B. *Ophthalmic Examination and Diagnostics*. In: *Vet ophthalmol*, 5th ed. Ames, John Willey & Sons. 2013: 684-685.
7. Garneau M, Bolger GT, Bousquet C, Kibler P, Tremblay F, Cordingley MG. HPMPC therapy of MCMV-induced retinal disease in the SCID mouse measured by electroretinography, a non-invasive technique. *Antiviral Res* 2003; 59: 193-200.
8. Gelatt KN, Plummer CE, Regnier A. The Canine Glaucoma. In: *Vet ophthalmol*, 5th ed. Ames, John Willey & Sons. 2013: 1050-1129.
9. Gilger BC, Reeves KA, Salmon JH. Ocular parameters related to drug delivery in the canine and equine eye: aqueous and vitreous humor volume and scleral surface area and thickness. *Vet Ophthalmol* 2005; 8: 265-8269.
10. Kirsch LS, Arevalo JF, Chavez de la Paz E, Munguia D, de Clercq E, Freeman WR. Intravitreal cidofovir (HPMPC) treatment of cytomegalovirus retinitis in patients with acquired immune deficiency syndrome. *Vet ophthalmol* 1995; 102: 533-543.
11. Low MC, Landis ML, Peiffer RL. Intravitreal cidofovir injection for the management of chronic glaucoma in dogs. *Vet Ophthalmol* 2014; 17: 201-206.
12. Maggs DJ, Miller PE, Ofri R. *Slatter's fundamentals of veterinary ophthalmology*. 5th ed. Saunders, Elsevier. 2013: 251-271.
13. Masur H, Whitcup SM, Cartwright C, Polis M, Nussenblatt R. Advances in the management of AIDS-related cytomegalovirus retinitis. *Ann Intern Med* 1996; 125: 126-136.
14. Rahhal FM, Arevalo JF, Munguia D, Taskintuna I, Chavez

- de la Paz E, Azen SP, Freeman WR. Intravitreal cidofovir for the maintenance treatment of cytomegalovirus retinitis. *Vet ophthalmol* 1996; 103: 1078-1083.
15. Taskintuna I, Banker AS, Rao NA, Wiley CA, Flores-Aguilar M, Munguia D, Bergeron-Lynn G, De Clercq E, Keefe K, Freeman WR. An animal model for cidofovir (HPMPC) toxicity: Intraocular pressure and histopathologic effects. *Exp Eye Res* 1997; 64: 795-806.
 16. Taskintuna I, Rahhal FM, Arevalo JF, Munguia D, Banker AS, De Clercq E, Freeman WR. Low-dose intravitreal cidofovir (HPMPC) therapy of cytomegalovirus retinitis in patients with acquired immune deficiency syndrome. *Vet ophthalmol* 1997; 104: 1049-1057.
 17. Taskintuna I, Rahhal FM, Rao NA, Wiley CA, Mueller AJ, Banker AS, De Clercq E, Arevalo JF, Freeman WR. Adverse events and autopsy findings after intravitreal cidofovir (HPMPC) therapy in patients with acquired immune deficiency syndrome (AIDS). *Vet ophthalmol* 1997; 104: 1827-1837.
 18. Young RW. Pathophysiology of age-related macular degeneration. *Surv Ophthalmol* 1987; 31: 291-306.
 19. Zarbin MA. Pathogenesis of Age-Related Macular Degeneration. In: *Med Retina*. Karger, Basel. 2012; 1: 125-133.