

Establishment of Injection Protocol of Contrast Material in Pulmonary Angiography using Test Bolus Method and 16-Detector-Row Computed Tomography in Normal Beagle Dogs

Sooyoung Choi*, Younghang Kwon, Hyunyoung Park, Kyunghun Kwon,
Kija Lee**, Inchul Park*, Hojung Choi and Youngwon Lee¹

College of Veterinary Medicine, Chungnam National University, Daejeon 34134, Korea
**College of Veterinary Medicine, Kangwon National University, Chuncheon 24341, Korea*
***College of Veterinary Medicine, Kyungpook National University, Daegu 41566, Korea*

(Received: July 17, 2017 / Accepted: August 11, 2017)

Abstract: The aim of this study was to establish an injection protocol of a test bolus and a main bolus of contrast material for computed tomographic pulmonary angiography (CTPA) for visualizing optimal pulmonary arteries in normal beagle dogs. CTPA using a test bolus method from either protocol A or B were performed in each of four normal beagle dogs. In protocol A, CTPA was conducted with a scan duration for around 8 s, setting the contrast enhancement peak of the pulmonary trunk in the middle of the scan duration. The arrival time to the contrast enhancement peak was predicted from a previous dynamic scan using a test bolus (150 mg iodine/kg) injected with the same injection duration using for a main bolus (450 mg iodine/kg). In protocol B, CTPA was started at the predicted appearance time of contrast material in the pulmonary trunk based on a previous dynamic scan using a test bolus injected with the same injection rate as a main bolus. CTPA using protocol A showed the optimal opacification of the pulmonary artery with pulmonary venous contamination. Proper CTPA images in the absence of venous contamination were obtained in protocol B. CTPA with a scan duration for 8 s should be started at the appearance time of contrast enhancement in the pulmonary trunk, which can be identified exactly when a test bolus is injected at the same injection rate used for the main bolus.

Key words: CTPA, dog, injection duration, injection rate, test bolus.

Introduction

Pulmonary thromboembolism (PTE) has been associated with hyperadrenocorticism, dirofilariasis, immune-mediated hemolytic anemia, myocardial disease, pancreatitis, and sepsis (7,12,14,16) and is a potentially life threatening condition (5,24), and previous reports in dogs and cats suggested a prevalence of 0.9% and 0.06%, respectively (12,16,19). Thoracic computed tomography (CT) is an imaging modality in human and veterinary medicine, and computed tomographic pulmonary angiography (CTPA) identifies PTE as well as parenchymal infarction, pleural effusion, vascular remodeling, and oligemia (7,8,21). Multi-detector CT permits CTPA images of high quality with an optimal arterial opacification (24), and the timing of scans has become a critical factor because suboptimal images could be obtained through inappropriate scan timing (23).

Test bolus and bolus-tracking are methods used to determine CT scan timing with regards to individual variation. A test bolus of a small volume of contrast material has been injected during CTPA to predict the contrast enhancement timing for various patient conditions in human and veteri-

nary medicine (4,10,18,22). Contrast enhancement timing is influenced significantly by cardiac output as a patient-related factor and injection duration as an injection-related factor (2). Therefore, the challenge in establishing a reasonable injection protocol of contrast material is important to obtain optimal CTPA images. However, an injection protocol of a test bolus to identify precise contrast enhancement timing for a main bolus of CTPA has not been previously studied in dogs.

The aim of this study was to establish the injection protocol of a test bolus and a main bolus of contrast material for CTPA with a test bolus method visualizing the optimal pulmonary arteries in normal beagle dogs.

Materials and Methods

Experimental animals

This study was performed under the guidance of the Chungnam National University Animal Care and Use Committee. Eight normal beagle dogs (eight intact males) with an age of 2 to 5 years and body weights ranging from 7.2 to 13.2 kg were used for the study. Routine screening tests such as physical examination including blood pressure, complete blood cell counts, serum chemistry analyses, thoracic and abdominal radiography, and echocardiography were performed to determine that the dogs were clinically healthy. The eight dogs

¹Corresponding author.
E-mail : lywon@cnu.ac.kr

were randomly classified into protocol A (four dogs, body weight with a range of 7.2 to 10.2 kg) or B (four dogs, 9.4 to 13.2 kg).

Anesthesia and survey CT scan

All dogs were fasted for 12 h. Anesthesia was induced with 3.0 mg/kg of alfaxalone (Alfaxan[®] inj.; Jurox Pharm. Co. Ltd.) intravenously. After endotracheal intubation, anesthesia was maintained with isoflurane (Ifran[®]; Hana Pharm. Co. Ltd.). The anesthetized dogs were placed in sternal recumbency on the CT table, and a 20-gauge over-the-needle catheter in the cephalic vein was connected to a Salient[™] CT injector (Imaxeon Pty. Ltd.; Sydney, Australia). To prevent motion artifacts due to respiration, breath-holding was performed using manual hyperventilation and positive pressure ventilation (10 cm H₂O) during the scan.

A survey scan of the entire abdomen extending from the thoracic inlet to the caudal endplate of the 13th thoracic vertebra with craniocaudal scan direction was performed using a 16-detector-row CT scanner Alexion[™] (Toshiba; Otawara, Japan). The following parameters were used: 120 kV, 150 mA, 1 mm slice thickness, 0.75 s rotation time, and 1.438 collimation beam pitch.

CTPA

Protocol A: CTPA was conducted using the same parameters as that of a survey scan. The injection duration of contrast material was adjusted to be the same as the scan duration. To find a precise time of contrast enhancement peak of the main bolus, a test bolus, iohexol (Omnipaque[®]; GE healthcare Ireland) of 150 mg iodine/kg, was injected with the same injection duration as the main bolus. The dynamic scan was initiated at the same time with injection of the contrast material and continued for 60 s at 1 s intervals using the following parameters: 100 kV, 50 mA, 2 mm slice thickness, and a 1 s rotation time. By means of an inherent software program, a time attenuation curve (TAC) was generated through positioning of the region of interest (ROI) on the pulmonary trunk, and the time to contrast enhancement peak of the pulmonary trunk was calculated from the TAC. The diagnostic scan with a main bolus of contrast material dose of 450 mg I/kg was performed when the contrast enhancement in the vessels from the previous dynamic CT scan had returned to the precontrast level. Scan delay after starting an injection of contrast material was determined by setting the middle of scan duration to the peak time of contrast enhancement.

Protocol B: The dynamic scan was started simultaneously with the injection of a test bolus, which was injected with the same injection rate to a main bolus to identify a precise time of an appearance of contrast material in the pulmonary trunk. The appearance time of contrast material was obtained from the TAC for the pulmonary trunk, and the diagnostic scan with a main bolus was started at the appearance time.

Image analyses

The acquired CT images were evaluated using a commercial software program Rapidia[®] (Infinit Healthcare Co. LTD.; Seoul, Korea). Scan sections for the total lung were divided into three sections: the right cranial and cranial part of the

left cranial lobes in the cranial scan section, the right middle and caudal part of the left cranial lobes in the middle scan section, and the bilateral caudal lobes in the caudal scan section. The cranial scan sections were evaluated at the third intercostal space level, the middle scan section at the fifth intercostal space level, and the caudal scan section at the seventh intercostal space level. ROIs with a circle were placed at the pulmonary artery (PA) and pulmonary vein (PV) of the three scan sections, and for each, attenuation values were measured from the maximal ROI within vessels on the transverse images with a soft tissue window (window width, 400; window level, 40). Differences between PA and PV were calculated from the measured attenuation values.

Assessment of image quality was performed using the modified method from the previous literature (24). Subjective image quality was evaluated from a maximum intensity projection using a five-point scoring scale: 1 = PA was enhanced lesser than PV; 2 = PA was enhanced well, equal to the accompanying PV; 3 = PA was enhanced mildly while PV was almost not enhanced; 4 = PA enhanced well while the accompanying PV enhanced mildly; 5 = PA enhanced well while PV was almost not enhanced.

Statistical analyses

All data are presented as the mean and standard deviation. The data were analyzed statistically using IBM SPSS Statistics 22.0 (IBM Corp.; Armonk, NY, USA). Data from protocol A and B were compared statistically using the Mann-Whitney test. Values of $p < 0.05$ were defined as statistically significant. Data among three scan sections in protocol A and B were compared using a Kruskal-Wallis test along with the Mann-Whitney test. The Bonferroni correction was used as an adjustment for multiple comparisons.

Results

The parameters for contrast material injection and CT scans in both protocols are shown in Table 1. The mean injection rate and duration of a test bolus in protocol A were significantly slower and longer than in protocol B. These differences resulted in a significantly longer time elapsed to the appearance and peak of contrast material at the pulmonary trunk in protocol A than in protocol B. Diagnostic scans of CTPA after injection of contrast material were started significantly later in protocol A than in protocol B.

The attenuation values of PA in the cranial scan section had higher significance in protocol A than protocol B, and there were no significant differences between the middle and caudal scan sections. The values of PV in all scan sections except the caudal part of the left cranial lobe were significantly lower in protocol B than in protocol A (Table 2). The difference of attenuation values between PA and PV was not significantly different among the three scan sections as well as between protocol A and B. The subjective image quality score of the caudal scan section was significantly higher in protocol B than protocol A, but not significantly different between the cranial and middle scan sections. In protocol B, the subjective image quality score in the cranial scan section was significantly lower than the values in the middle and caudal

Table 1. The injection parameters of contrast material and CT scan parameters in the two protocols

	Protocol A	Protocol B	p-value
Test bolus			
Injection volume (ml)	5.5 ± 0.9	4.8 ± 0.4	0.186
Injection rate (ml/s)	0.63 ± 0.11	1.58 ± 0.19	0.020
Injection duration (s)	8.65 ± 0.34	3.03 ± 0.20	0.021
Arrival times of test bolus			
Appearance in pulmonary trunk (s)	2.5 ± 0.5	1.3 ± 0.4	0.032
Peak in pulmonary trunk (s)	7.88 ± 0.54	4.00 ± 0.71	0.019
Main bolus			
Injection volume (ml)	16.3 ± 2.3	13.5 ± 1.7	0.139
Injection rate (ml/s)	1.85 ± 0.25	1.58 ± 0.19	0.144
Injection duration (s)	8.65 ± 0.34	8.55 ± 0.21	0.663
Scan parameters of CTPA			
Scan delay after injection starting (s)	3.8 ± 0.4	1.3 ± 0.4	0.018
Scan duration (s)	8.65 ± 0.34	8.55 ± 0.21	0.663

Table 2. Mean attenuation values (HU) in pulmonary vessels of six lung lobes in the two groups

	Protocol A	Protocol B	p-value
Cranial scan section			
PA of RCrL	662.8 ± 106.4	334.8 ± 71.2	0.021
PV of RCrL	324.8 ± 111.2	47.5 ± 9.7	0.021
PA of CrLCrL	623.5 ± 61.9	339.0 ± 52.4	0.020
PV of CrLCrL	298.8 ± 133.0	73.0 ± 12.5	0.021
Middle scan section			
PA of RML	613.3 ± 131.7	498.5 ± 43.2	0.149
PV of RML	370.5 ± 50.6	185.3 ± 80.2	0.021
PA of CaLCrL	580.5 ± 130.5	477.0 ± 122.5	0.248
PV of CaLCrL	416.0 ± 135.1	204.0 ± 35.9	0.149
Caudal scan section			
PA of RCaL	613.0 ± 145.0	514.0 ± 49.1	0.386
PV of RCaL	438.8 ± 84.9	180.5 ± 53.1	0.021
PA of LCaL	662.0 ± 168.1	561.5 ± 39.2	0.772
PV of LCaL	461.8 ± 90.7	216.3 ± 55.9	0.020

PA, pulmonary artery; PV, pulmonary vein; RCrL, right cranial lobe; CrLCrL, cranial part of left cranial lobe; RML, right middle lobe; CaLCrL, caudal part of left cranial lobe; RCaL, right caudal lobe; LCaL, left caudal lobe

scan sections (Fig 1 and Table 3).

Discussion

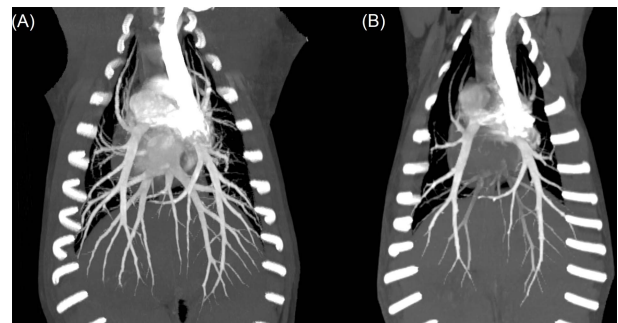
Injection parameters are an important factor affecting the

Table 3. Differences of attenuation values (HU) between PA and PV and subjective image quality score in the two groups

	Protocol A	Protocol B	p-value
Cranial scan section			
RCrL	338.0 ± 182.7	287.3 ± 76.3	0.564
CrLCrL	324.8 ± 151.1	266.0 ± 61.3	0.564
Image quality score	3.3 ± 1.3	3.0 ± 0.0	1.000
Middle scan section			
RML	242.8 ± 171.9	313.3 ± 103.2	0.773
CaLCrL	164.5 ± 240.0	273.0 ± 131.9	0.386
Image quality score	2.8 ± 1.3	4.3 ± 0.4 [†]	0.169
Caudal scan section			
RCaL	174.3 ± 205.1	333.5 ± 76.9	0.248
LCaL	200.3 ± 179.6	345.3 ± 84.6	0.248
Image quality score	2.5 ± 0.9	4.0 ± 0.0 [†]	0.040

RCrL, right cranial lobe; CrLCrL, cranial part of left cranial lobe; RML, right middle lobe; CaLCrL, caudal part of left cranial lobe; RCaL, right caudal lobe; LCaL, left caudal lobe

[†]The values were significantly different from that of the cranial scan section.

**Fig 1.** Dorsoventral views of maximum intensity projection of CTPA using protocol A (A) and B (B) in beagle dogs. Venous contamination of contrast enhancement is remarkably visible in protocol A compared with protocol B.

contrast enhancement timing of CT scans (2). Theoretically, the injection rate influences the delivery rate of contrast material, and the same injection duration may reflect a similar peak timing of contrast enhancement (1,2,15). When the injection duration increases, the time for the maximum deposit of contrast material is prolonged and subsequently the time to peak contrast enhancement increases (3). Consequently, the results of this study showed that the timing of a CTPA scan is different depending on the injection parameter of a test bolus.

In protocol A, the time to peak contrast enhancement of the PA was predicted from the TAC of a test bolus that was injected using the injection duration of a main bolus for CTPA. PA was enhanced to well over 600 HU, and we believe that a proper scan duration and delay were applied for PA enhancement. One advantage of a fixed injection duration protocol is that the scan timing for good contrast enhancement can be

more easily standardized in human and veterinary medicine (1,2,15). However, PV contamination was also observed in protocol A. PV contamination is a major limitation for CTPA and it suggests PA opacification in the absence of significant PV filling (24). In humans, the time for the peak PA contrast concentration without PV contamination is ultrashort (2), and a short scan duration has been used to obtain CTPA without PV contamination (24). CTPA using protocol A showed PV contamination even in the cranial scan section. Peak contrast enhancement without PV contamination in dogs may be not long enough, or the scan duration in this study may be too long to complete the CT scan. When CTPA was conducted using a scan duration of around 8 s in this study and the scan delay was determined by protocol A, PV contamination could not be excluded despite good PA enhancement.

In protocol B, the time to contrast material appearance at the pulmonary trunk was predicted from the TAC of the test bolus. In the results of protocol B, the PA enhancement tended to increase when the scan section was performed later. It is possible the scan duration was set up at the time of contrast material deposit and increased rapidly after the appearance point to the peak point. An optimal enhancement level of 300 HU has been assumed as the value for an adequate CTPA in human and veterinary medicine (9,15,17,20). The lowest magnitude of PA contrast enhancement in a cranial scan section is sufficient to evaluate it as a proper CTPA. The PV enhancement also increased when the scan section was late. However, the opacification of PV was not over 300 HU. Therefore, we thought that CTPA with a negligible venous contamination was obtained when a scan with a duration for 8 s was started at the appearance time of contrast enhancement in the pulmonary trunk.

The contrast enhancement differences of over 300 HU between PA and PV were shown at the cranial scan section of protocol A and the middle and caudal scan section of protocol B. The image quality score of the cranial scan section in protocol A was lower than that of the middle and caudal scan section in protocol B due to PV contamination, although there was good PA contrast enhancement. On the contrary, although PV contamination of the cranial scan section of protocol B was absent, the image quality was evaluated lower than in the middle and caudal scan section due to the relatively low PA opacification. Considering the scan duration and scan delay of protocol A and B, the scan timing of the cranial scan section in protocol A may be similar to the caudal scan section in protocol B that could include some risk for PV contamination. Optimal CTPA without PV contamination could be reproducible for a middle scan section of protocol B.

The injection duration of contrast material for CTPA has been adjusted based on the scan duration in the previous veterinary literature (15). This injection method was concluded to be particularly suitable for CTPA for a population with great weight variability. Injection duration was adjusted to be the same as the scan duration in this study, allowing contrast material to be injected continuously during CT scanning. A scan duration of approximate 2 s has been used at the acquisition of CTPA without PV contamination using a bolus-tracking technique in a human study (24). Pulmonary transit

time (PTT) is typically about 3 s in humans (11,13), and canine PTT has been reported to about 2 s (6). Based on the previous literatures, the scan duration of approximate 8 s in this study may be too long to obtain an entire optimal CTPA, and the proper scan duration for optimal CTPA could be speculated to be under 5 s in order to provide coverage for the middle scan section in this study.

The cranial scan section of protocol B can provide an optimal CTPA without PV contamination, but a stronger contrast enhancement of PA is required. With a fixed injection duration and volume of contrast material such as was used in this study, a highly concentrated contrast material or a faster injection rate can be used to achieve a higher magnitude of contrast enhancement. However, the injected volume or dose of contrast material will also increase in consequence. An iodine dose of 400 to 700 mg iodine/kg has been applied for CTPA in dogs (8,9,15). A further investigation for an injection rate and dose of contrast material is required to improve PA opacification while avoiding PV contamination.

This study has some limitations. Attenuation of PA and PV in protocol B tended to increase among the three scan sections. Also, the mean attenuation of PV in the caudal part of the left cranial lobe in protocol A was higher than in protocol B but not significantly different. These uncertain results at these tendencies in this study may be due to the small study population. Although contrast enhancement patterns of PV can provide important information about preventing venous contamination, contrast enhancement patterns of PV as well as PTT were not evaluated in this study.

Based on the results of this study, we recommend that CT scanning be started at the appearance time of contrast material in the pulmonary trunk if a scan duration of 8 s is allowed due to the performance of the CT equipment. In this situation, a test bolus should be injected using the same injection rate used for a main bolus during CTPA.

Acknowledgement

This work was supported by research fund of Chungnam National University.

References

1. Awai K, Hori S. Effect of contrast injection protocol with dose tailored to patient weight and fixed injection duration on aortic and hepatic enhancement at multidetector-row helical CT. *Eur Radiol* 2003; 13: 2155-2160.
2. Bae KT. Intravenous contrast medium administration and scan timing at CT: considerations and approaches. *radiol* 2010; 256: 32-61.
3. Bae KT, Heiken JP, Brink JA. Aortic and hepatic peak enhancement at CT: effect of contrast medium injection rate—pharmacokinetic analysis and experimental porcine model. *radiol* 1998; 206: 455-464.
4. Cassel N, Carstens A, Becker P. The comparison of bolus tracking and test bolus techniques for computed tomography thoracic angiography in healthy beagles. *J S Afr Vet Assoc* 2013; 84: 00-00.
5. Chan H-P, Hadjiiski L, Zhou C, Sahiner B. Computer-aided diagnosis of lung cancer and pulmonary embolism in com-

- puted tomography—A review. *Acad Radiol* 2008; 15: 535-555.
6. Crosara S, Ljungvall I, Margiocco ML, Häggström J, Tarducci A, Borgarelli M. Use of contrast echocardiography for quantitative and qualitative evaluation of myocardial perfusion and pulmonary transit time in healthy dogs. *Am J Vet Res* 2012; 73: 194-201.
 7. Goggs R, Benigni L, Fuentes VL, Chan DL. Pulmonary thromboembolism. *J Vet Emerg Crit Care* 2009; 19: 30-52.
 8. Goggs R, Chan D, Benigni L, Hirst C, Kellett-Gregory L, Fuentes V. Comparison of computed tomography pulmonary angiography and point-of-care tests for pulmonary thromboembolism diagnosis in dogs. *J Small Anim Pract* 2014; 55: 190-197.
 9. Habing A, Coelho JC, Nelson N, Brown A, Beal M, Kinns J. Pulmonary angiography using 16 slice multidetector computed tomography in normal dogs. *Vet Radiol Ultra* 2011; 52: 173-178.
 10. Henzler T, Meyer M, Reichert M, Krissak R, Nance JW, Haneder S, et al. Dual-energy CT angiography of the lungs: comparison of test bolus and bolus tracking techniques for the determination of scan delay. *Eur J Radiol* 2012; 81: 132-138.
 11. Jeong HJ, Vakil P, Sheehan JJ, Shah SJ, Cuttica M, Carr JC, et al. Time-resolved magnetic resonance angiography: Evaluation of intrapulmonary circulation parameters in pulmonary arterial hypertension. *J Magn Reson Imaging* 2011; 33: 225-231.
 12. Johnson LR, Lappin MR, Baker DC. Pulmonary thromboembolism in 29 dogs: 1985-1995. *J Vet Intern Med* 1999; 13: 338-345.
 13. Kilic K, Erbas G, Ucar M, Akkan K, Tokgoz N, Arac M, et al. Determination of lowest possible contrast volume in computed tomography pulmonary angiography by using pulmonary transit time. *Jpn J Radiol* 2014; 32: 90-97.
 14. LaRue M, Murtaugh R. Pulmonary thromboembolism in dogs: 47 cases (1986-1987). *J Am Vet Med Assoc* 1990; 197: 1368.
 15. Makara M, Dennler M, Kuehn K, Kalchofner K, Kircher P. Effect of contrast medium injection duration on peak enhancement and time to peak enhancement of canine pulmonary arteries. *Vet Radiol Ultra* 2011; 52: 605-610.
 16. Norris C, Griffey S, Samii V. Pulmonary thromboembolism in cats: 29 cases (1987-1997). *J Am Vet Med Assoc* 1999; 215: 1650-1654.
 17. Ramadan SU, Kosar P, Sonmez I, Karahan S, Kosar U. Optimisation of contrast medium volume and injection-related factors in CT pulmonary angiography: 64-slice CT study. *Eur Radiol* 2010; 20: 2100-2107.
 18. Rodrigues J, Mathias H, Negus I, Manghat N, Hamilton M. Intravenous contrast medium administration at 128 multi-detector row CT pulmonary angiography: bolus tracking versus test bolus and the implications for diagnostic quality and effective dose. *Clin Radiol* 2012; 67: 1053-1060.
 19. Schermerhorn T, Pembleton-Corbett JR, Kornreich B. Pulmonary thromboembolism in cats. *J Vet Intern Med* 2004; 18: 533-535.
 20. Schoellnast H, Deutschmann HA, Berghold A, Fritz GA, Schaffler GJ, Tillich M. MDCT angiography of the pulmonary arteries: influence of body weight, body mass index, and scan length on arterial enhancement at different iodine flow rates. *Am J Roentgenol* 2006; 187: 1074-1078.
 21. Schoepf UJ, Goldhaber SZ, Costello P. Spiral computed tomography for acute pulmonary embolism. *Circulation* 2004; 109: 2160-2167.
 22. Suckling T, Smith T, Reed W. A retrospective comparison of smart prep and test bolus multi-detector CT pulmonary angiography protocols. *J Med Radiat Sci* 2013; 60: 53-57.
 23. U-King-Im JM, Freeman SJ, Boylan T, Cheow HK. Quality of CT pulmonary angiography for suspected pulmonary embolus in pregnancy. *Eur Radiol* 2008; 18: 2709.
 24. Wang M, Li W, Lun-Hou D, Li J, Zhai R. Optimizing computed tomography pulmonary angiography using right atrium bolus monitoring combined with spontaneous respiration. *Eur Radiol* 2015; 25: 2541-2546.