

Effectiveness of Cyclosporine in a 10-year-old Girl with C3 Glomerulopathy

Kyung Mi Jang, M.D.
Yong Hoon Park, M.D., Ph.D.

Department of Pediatrics, Yeungnam
University College of Medicine, Daegu,
Korea

Corresponding author:

Yong Hoon Park, M.D., Ph.D.
Department of Pediatrics, Yeungnam
University College of Medicine, Daegu,
170 Hyeonchung-ro, Nam-gu, Daegu
42415, Korea

Tel: +82-53-620-3536

Fax: +82-53-629-2252

E-mail: yhpark@ynu.ac.kr

Received: 7 August 2017

Revised: 8 September 2017

Accepted: 18 September 2017

C3 glomerulopathy (C3G) is a recently defined pathological entity characterized by C3 accumulation with absent or scant immunoglobulin deposition, leading to variable glomerular inflammation. The clinical presentation of patients with C3G is highly variable, as they may present with symptoms ranging from microscopic or mild proteinuria to full-blown nephrotic syndrome, with or without renal impairment. However, there is no consensus recommendation for specific treatment in children with C3G. Recently, new therapies have been suggested to target complement pathways, owing to an improvement in the understanding of the pathogenesis of C3G. C3G complement blockade with eculizumab, a monoclonal antibody targeted against complement C5, inhibits activation of the alternative complement pathway. We could not use eculizumab owing to its high price; thus, we administered oral prednisolone and mycophenolate mofetil (MMF). MMF was replaced with cyclosporine because proteinuria persisted, with a consistently low serum C3 level; we tapered off the prednisolone because of a Cushingoid appearance and amenorrhea. Thereafter, proteinuria improved, and the serum C3 level returned to normal. Thus, we report the effectiveness of cyclosporine in a patient with C3G and an inadequate response to prednisolone and MMF, who was detected via school urinary screening.

Key words: C3 glomerulopathy, Eculizumab, MMF, Cyclosporine

Introduction

C3 glomerulopathy (C3G) is a recently defined pathological entity characterized by C3 accumulation with absent or scant immunoglobulin deposition leading to variable glomerular inflammations^{1,2}. C3G was often diagnosed previously as membranoproliferative glomerulonephritis (MPGN) because of similarities in the light microscopy (LM) and electron microscopy (EM) findings. MPGN can be classified into either immunoglobulin (IgG)-associated MPGN (caused by classical complement pathway activation); MPGN with dominant C3 (C3G and C3GN); or idiopathic MPGN. Both C3GN and idiopathic MPGN are caused by alternative complement pathway activations³.

C3G includes C3 glomerulonephritis (C3GN) and dense deposit disease (DDD)^{4,5}. The difference between C3GN and DDD is that DDD is characterized by the presence of extremely electron-dense deposits in the basement

This is an open-access article distributed under the terms of the Creative Commons Attribution Non-Commercial License (<http://creativecommons.org/licenses/by-nc/4.0/>) which permits unrestricted non-commercial use, distribution, and reproduction in any medium, provided the original work is properly cited.

membrane, while the changes observed in patients with C3GN are more heterogenous. C3GN also includes disease entities associated with complement mutation, which is causally associated with the underlying renal pathology, such as familial DDD with C3 mutation and familial C3GN with mutations in the CFHR genes. The incidence of C3GN is reported to be one to two per 1,000,000 children, with its onset occurring between 5 and 15 years of age. The clinical manifestations of C3GN comprise a wide spectrum, including mild urinary abnormalities, nephrotic syndrome, and nephritic syndrome with or without renal impairment^{1,3,6,7}. The condition often progresses to chronic kidney disease or end-stage kidney disease and can recur after renal transplantation.

In affected patients, the alternative pathway produces C3 convertase, which amplifies C3 activation, resulting in the creation of C3b particles, and finally, the formation of C5 convertase to assemble MAC C5b-9. This damages the cells via the development of a lytic pore and leads to cellular death via apoptosis or necrosis. Factor H and other complement proteins regulate the amplification of C3 activation⁸.

The current treatment includes supportive measures and use of immunosuppressants, including prednisone, mycophenolate mofetil (MMF), and calcineurin inhibitors. Recently, plasma exchange/plasma infusion and provision of eculizumab, a monoclonal antibody against C5, can be used in cases of nephritic syndrome and/or decreased renal function in patients with C3GN.

Case report

Proteinuria and microscopic hematuria were first detected via a school urinary screening in a 10-year-old girl. The patient was referred to our hospital for evaluation by a local hospital. Her physical examination findings were normal, there was also no edema. The patient had a normal blood pressure of 100/60 mmHg. The laboratory investigation results upon admission were as follows: leukocyte count, 9,170/ μ L; platelet count, 460 K/ μ L; hemoglobin level, 12.8 g/dL; BUN level, 11.9 mg/dL; and serum creatinine level, 0.7 mg/dL (eGFR, 94.7 mL/min/1.73 m², Schwarz formula). Urinalysis showed only microscopic hematuria (RBC count, 20-30/HPF) by dipstick, and the level of pro-

tein identified in the 24-hour urine study was 47 mg/m²/day.

A markedly decreased C3 level of 15 mg/dL (reference range: 77-195 mg/dL) and normal C4 level of 15.9 mg/dL (reference range: 7-40 mg/dL) were noted on immunological evaluation. The infectious serology tests conducted for hepatitis B and hepatitis C revealed negative findings. Renal imaging showed that the patient had normal-sized kidneys, with ureteral duplication. Renal biopsy was performed owing to persistently decreased C3 level. LM showed diffuse exudative proliferative glomerulonephritis. On immunofluorescence staining, a markedly increased granular deposit of C3 in the mesangium was noted without any other immunoglobulin deposition. EM revealed an electron-dense deposit along the glomerular basement membrane. We initiated the administration of angiotensin-converting enzyme (ACE) inhibitors for supportive care. The patient showed only microscopic hematuria and decreased serum C3 level without proteinuria for -3 years. However, we subsequently failed to follow up with the patient, and after -2 years, the patient revisited our hospital with nephrotic-range proteinuria (53.37 mg/m²/h) and microscopic hematuria with normal renal function at the age of 15 years. She reported no symptoms during the entire period. A second biopsy was performed, which showed an MPGN pattern with predominant C3 deposits on immunofluorescence staining, similar to those observed on the first biopsy (Fig. 1).

At this time, the patient's levels of complement factor H, factor B, and anti-CFH autoantibody were within normal ranges. However, the level of complement factor I (CFI) decreased to 0.47 mg/dL, as compared with the reference value (3.8-5.8 mg/dL). There was no mutation of CFI by Sanger sequencing noted. During the genetic study for the alternative pathway of the complement system, a heterozygous mutation was detected in a C8A gene mutation known to be associated with atypical hemolytic uremic syndrome (aHUS) or DDD. However, the C8 α plasma level and hemolytic activity were needed to confirm the presence of a meaningful mutation of the C8A gene.

We started to administer ACE inhibitors and angiotensin receptor blockers (ARBs) to reduce the proteinuria. Thereafter, the amount of proteinuria was decreased with these treatments; however, after -8 months, proteinuria was inc-

reased to 95 mg/m²/h. At that time, it was decided that we could not use eculizumab because it was expensive; thus, we added oral prednisolone (40 mg/day) and MMF (1 g/day). Following prescription, proteinuria was decreased to UPr/cr of 0.4; however, proteinuria was sustained with a consistently low serum C3 level (10.8 mg/dL, reference range: 77-195 mg/dL). MMF was replaced with cyclosporine. It was also determined that we could not use prednisolone for long-term maintenance because the patient demonstrated a cushingoid appearance and amenorrhea. Thus, we tapered

off the dosage of prednisolone and decided only to use cyclosporine and an ACE inhibitor for maintenance. After 6 months, the patient’s proteinuria had improved, and her serum C3 level recovered back to normal (106 mg/dL, reference range: 77-195 mg/dL). We continued to administer cyclosporine and ACE inhibitor; thereafter, we attempted to taper off the dosage of cyclosporine. However, when we reduced the dosage of cyclosporine, her proteinuria worsened; hence, we continued to administer cyclosporine (150 mg/day) and ACE inhibitor (Fig. 2).

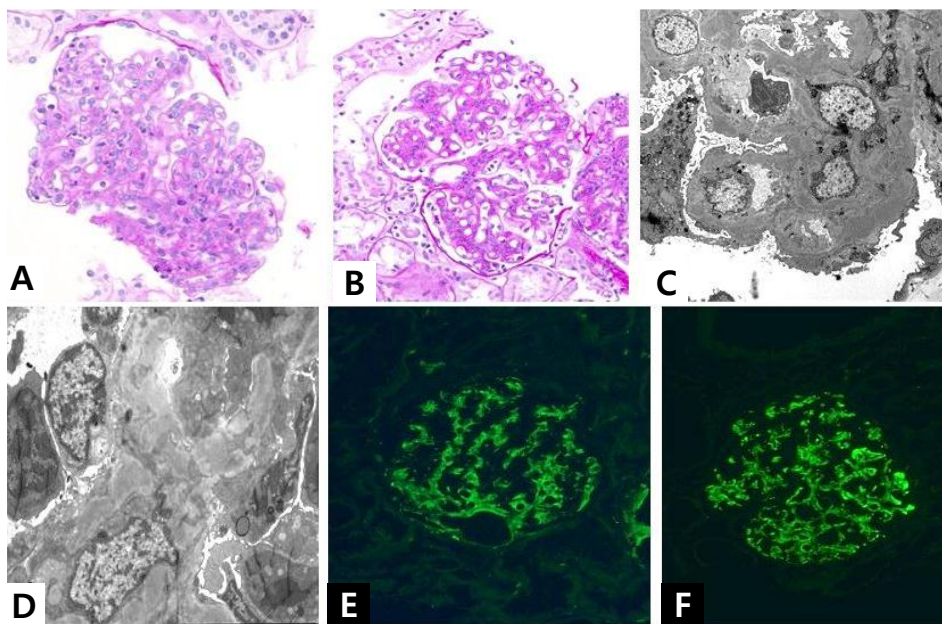


Fig. 1. Renal biopsy at 2nd hospitalization (A-F). (A,B) Light microscopy of hematoxylin and eosin (H&E) stain reveals endocapillary proliferation and mesangial cell proliferation (x200). (C-D) Electron microscopy (x1,500, (C); x3,000, (D)) shows subendothelial deposits and mesangial deposits. Diffuse foot process effacement is also shown. (E-F) Immunofluorescence microscopy showing C3 staining along the glomerular capillary wall. Staining for all immunoglobulins (IgG, IgM and IgA) was negative.

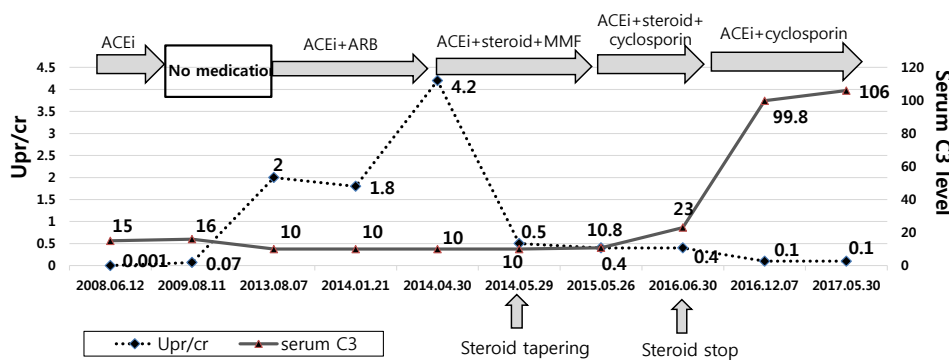


Fig. 2. Changes of Upr/cr and serum C3 level during treatment of a patient with C3GN. Upr/cr is shown on the left y-axis, and serum C3 level (mg/dL) is shown on the right y-axis. The patient was less responsive to prednisolone and MMF. With cyclosporin, proteinuria had improved and serum C3 level had recovered to normal.

Discussion

We reported a case of C3GN detected via school urine examination in a 10-year-old girl, which was confirmed via renal biopsy and showed a membranoproliferative pattern with electron-dense deposits on the subendothelium and interstitial fibrosis. A low serum C3 level is commonly observed in patients with this disease, but does not correlate with the severity of the condition⁹. The prognosis of these patients may be determined by a decrease in the eGFR and the severity of proteinuria at the time of diagnosis and during follow-up as in most renal diseases¹⁰. The degree of tubulointerstitial fibrosis is another poor prognostic factor, more so than the severity of glomerular changes¹¹. There is no consensus regarding recommendation of a specific treatment in children with C3GN. There is also no evidence for the treatment with ACE inhibitors or ARBs. However, these medications should only be considered for use because of the existing ability to extrapolate information from other proteinuric renal diseases. The limited data on the use of ACE inhibitors or ARBs in patients with C3GN had been reported in a French C3G cohort, where it was stated that treatment with ACE inhibitors or ARBs might improve renal survival ($P < 0.0001$)¹².

Some studies have reported that anticellular immune suppression is considered less effective in children with C3GN. Servais et al. reported that immunosuppressants were not associated with renal survival¹². Another previous study reported the failure of treatment with glucocorticoids in helping patients achieve remission after 5 years¹³.

However, recent case series suggested that the administration of MMF is effective^{14,15}. Furthermore, a recent KDIGO (Kidney Disease: Improving Global Outcomes) controversies conference recommended that C3G patients with moderate disease (defined as urine protein of more than 500 mg/24 hours or recent rise in creatinine or moderate inflammation on renal biopsy) despite supportive therapy receive prednisone or MMF¹⁶. There are also reports for the effectiveness of cyclosporin in patients with C3G. Bagheri et al. noted that 18 patients with MPGN who were treated with cyclosporine showed an excellent response to the medication¹⁷.

Recently, new therapies have been suggested to target complement pathways owing to an improvement in the

understanding of the pathogenesis of C3GN. An anti-complement effect for C3G has been predicted via the use of an animal model¹⁸. C3G complement blockade eculizumab is a monoclonal antibody targeted against complement C5 that inhibits the activation of the alternative complement pathway. Although reported results to date are conflicting, many studies have reported an efficacy of eculizumab in patients with C3G, even in children^{18,19}. Eculizumab is approved by the United States Food and Drug Administration for the treatment of aHUS, thrombotic microangiopathy, and paroxysmal nocturnal hemoglobinuria. Therefore, it is used as an off-label medication for C3G.

As mentioned above, recently conducted studies explain the effectiveness of eculizumab because of the understanding of the pathogenesis of C3G. However, eculizumab cannot be used in some instances, and in these instances, it has been reported that cyclosporine is effective for managing steroid-resistant nephrotic syndrome caused by MPGN II²⁰⁻²². Our patient was partially responsive to MMF treatment but had persistent proteinuria and a low serum C3 level. When we switched MMF to cyclosporine, her proteinuria resolved, and the serum C3 level also normalized. Therefore, we reported a case of C3GN successfully treated with cyclosporine. We suggest that cyclosporine be considered as a therapeutic agent for C3GN in cases in which eculizumab cannot be used and/or if the patient does not respond to other immunosuppressants, such as steroids and MMF.

Conflicts of interest

No potential conflict of interest relevant to this article was reported.

References

1. Sethi S, Fervenza FC, Zhang Y, Zand L, Vrana JA, Nasr SH, et al. C3 glomerulonephritis: clinicopathological findings, complement abnormalities, glomerular proteomic profile, treatment, and follow-up. *Kidney Int* 2012;82:465-73.
2. Pickering MC, D'Agati VD, Nester CM, Smith RJ, Haas M, Appel GB, et al. C3 glomerulopathy: consensus report. *Kidney Int* 2013; 84:1079-89.

3. Bomback AS, Appel GB. Pathogenesis of the C3 glomerulopathies and reclassification of MPGN. *Nat Rev Nephrol* 2012;8:634-42.
4. Smith RJ, Alexander J, Barlow PN, Botto M, Cassavant TL, Cook HT, et al. New approaches to the treatment of dense deposit disease. *J Am Soc Nephrol* 2007;18:2447-56.
5. Nester CM, Smith RJ. Diagnosis and treatment of C3 glomerulopathy. *Clin Nephrol* 2013;80:395-403.
6. Medjeral-Thomas NR, O'Shaughnessy MM, O'Regan JA, Traynor C, Flanagan M, Wong L, et al. C3 glomerulopathy: clinicopathologic features and predictors of outcome. *Clin J Am Soc Nephrol* 2014;9:46-53.
7. Fakhouri F, Frémeaux-Bacchi V, Noel LH, Cook HT, Pickering MC. C3 glomerulopathy: a new classification. *Nat Rev Nephrol* 2010;6:494-9.
8. Master Sankar Raj V, Gordillo R, Chand DH. Overview of C3 Glomerulopathy. *Front Pediatr* 2016;4.
9. Barbour TD, Pickering MC, Cook HT. Recent insights into C3 glomerulopathy. *Nephrol Dial Transplant* 2013;28:1685-93.
10. Cameron JS, Turner DR, Heaton J, Williams DG, Ogg CS, Chantler C, et al. Idiopathic mesangiocapillary glomerulonephritis. Comparison of types I and II in children and adults and long-term prognosis. *Am J Med* 1983;74:175-92.
11. Little MA, Dupont P, Campbell E, Dorman A, Walshe JJ. Severity of primary MPGN, rather than MPGN type, determines renal survival and post-transplantation recurrence risk. *Kidney Int* 2006;69:504-11.
12. Servais A, Noel LH, Roumenina LT, Le Quintrec M, Ngo S, Dragon-Durey MA, et al. Acquired and genetic complement abnormalities play a critical role in dense deposit disease and other C3 glomerulopathies. *Kidney Int* 2012;82:454-64.
13. Daina E, Noris M, Remuzzi G. Eculizumab in a Patient with Dense-Deposit Disease. *N Engl J Med* 2012;366:1161-3.
14. Rabasco C, Caverio T, Roman E, Rojas-Rivera J, Olea T, Espinosa M, et al. Effectiveness of mycophenolate mofetil in C3 glomerulonephritis. *Kidney Int* 2015;88:1153-60.
15. Lioufas N, Finlay M, Barbour T. Durable remission of C3 glomerulonephritis with mycophenolate mofetil. *Nephrology (Carlton)* 2017;22 Suppl 1:36-9.
16. Goodship THJ, Cook HT, Fakhouri F, Fervenza FC, Frémeaux-Bacchi V, Kavanagh D, et al. Atypical hemolytic uremic syndrome and C3 glomerulopathy: conclusions from a "Kidney Disease: Improving Global Outcomes" (KDIGO) Controversies Conference. *Kidney Int* 2017;91:539-51.
17. Bagheri N, Nemati E, Rahbar K, Nobakht A, Einollahi B, Taheri S. Cyclosporine in the treatment of membranoproliferative glomerulonephritis. *Arch Iran Med* 2008;11:26-9.
18. Ruseva MM, Peng T, Lasaro MA, Bouchard K, Liu-Chen S, Sun F, et al. Efficacy of Targeted Complement Inhibition in Experimental C3 Glomerulopathy. *J Am Soc Nephrol* 2016;27:405-16.
19. Lebreton C, Bacchetta J, Dijoud F, Bessenay L, Frémeaux-Bacchi V, Sellier-Leclerc AL. C3 glomerulopathy and eculizumab: a report on four paediatric cases. *Pediatr Nephrol* 2017;32:1023-8.
20. Kiyomasu T, Shibata M, Kurosu H, Shiraishi K, Hashimoto H, Haya-shidera T, et al. Cyclosporin A Treatment for Membranoproliferative Glomerulonephritis Type II. *Nephron* 2002;91:509-11.
21. Lee S-J, Moon J-H, Kang M-S, Song M-S, Chung W-Y. A Case of Membranoproliferative Glomerulonephritis Type II (Dense-Deposit Disease). *Child Kidney Dis* 2003;7:204-10.
22. Singh A, Tejani C, Tejani A. One-center experience with cyclosporine in refractory nephrotic syndrome in children. *Pediatr Nephrol* 1999;13:26-32.