



Removal of a fractured needle during inferior alveolar nerve block: two case reports

Jae-seek You¹, Su-Gwan Kim¹, Ji-Su Oh¹, Hae-In Choi¹, and Myeong-Kwan Jih²

¹Department of Oral and Maxillofacial Surgery, School of Dentistry, Chosun University, Gwang-ju, Korea

²Department of Pediatric Dentistry, School of Dentistry, Chosun University, Gwang-ju, Korea

The inferior alveolar nerve block is the most common method of local anesthesia for intraoral surgery at the posterior mandibular region. However, unexpected complications may occur when administering the local anesthesia. One of these uncommon complications is the fracture of the needle. If the injection needle is broken during the surgery, it should be removed immediately. However, this is one of the most difficult procedures. In this report, we present two cases of needle fracture during the procedure, and its successful removal under general/local anesthesia administration.

Keywords: Anesthesia, Local; Inferior Alveolar Nerve; Needle Fracture; Nerve Block.



This is an Open Access article distributed under the terms of the Creative Commons Attribution Non-Commercial License (<http://creativecommons.org/licenses/by-nc/4.0/>) which permits unrestricted non-commercial use, distribution, and reproduction in any medium, provided the original work is properly cited.



The inferior alveolar nerve block is the most commonly used local anesthetic method for intraoral surgery of the mandibular molar region. However, unexpected complications may occur during local anesthesia, including the breakage of the injection needle [1]. Recently, cases of the removal of these fractured needle have been reported [1]. Various factors can cause the fracture of the needle, such as defects of the injection needle itself or its reuse after bending the tip of the needle. The needle can move to the hub-site during anesthetics administration, mainly due to the patient's unexpected movement or sudden mouth closure. Thus, needle fractures may occur more commonly in pediatric patients; hence, more attention is needed in this patient population.

When a needle fracture occurs and the needle fragment cannot be visualized in the oral cavity, the surgeon should refer the patient to a better-equipped hospital. Although,

there is a report where a broken needle was left in the body, without any adverse symptoms [2], broken needle fragments may cause pain, limit the opening of the mouth, and lead to infection, etc. Furthermore, it could migrate to other parts of the body through muscle movement, causing damage to vital structures like vessels or nerves. The purpose of the current study was to report two cases where needle fractures occurred during the administration of an inferior alveolar nerve block. The needle fragments were successfully removed under local/general anesthesia in each case.

Moreover, we presented precautions for using local anesthesia as preventive measures from needle fracture.

Received: August 30, 2017 • Revised: September 7, 2017 • Accepted: September 7, 2017

Corresponding Author: Su-Gwan Kim, Professor, Department of Oral and Maxillofacial Surgery, School of Dentistry, Chosun University, 309 Pilmun-daero, Gwang-ju 61452, Republic of Korea

Tel: +82-62-220-3815 Fax: +82-62-228-7316 E-mail: sgckim@chosun.ac.kr

Copyright© 2017 Journal of Dental Anesthesia and Pain Medicine

CASE REPORTS

1. Case 1

A 45-year-old female patient was referred to our department for oral maxillofacial surgery to remove a needle, which had fractured in the left pterygomandibular space. The patient had received local anesthesia to place an implant in the first molar region of right side of the mandible, and the needle had broken off due to the unanticipated movement of the patient during the administration of inferior alveolar nerve anesthesia with a 30-gauge needle. Although the local clinic immediately attempted to retrieve the fractured needle, their attempt failed. When the patient was sent to our department for oral maxillofacial surgery, although she had pain when she opened her mouth, there was no limitation in her

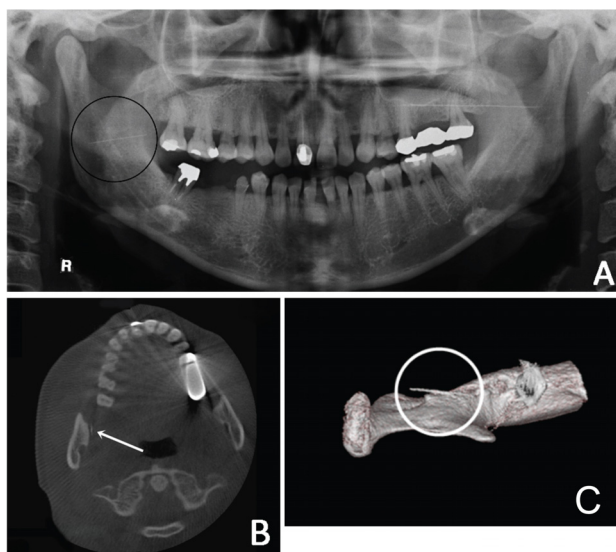


Fig. 1. Preoperative radiographic images showing the broken needle in (A) panoramic view, (B) computed tomography (CT) axial view, and (C) as a 3D-CT image.




Fig. 2. A fractured needle fragment.

ability to open her mouth. Panoramic radiographs were acquired and cone-beam computed tomography (CBCT) was performed to detect the location of the fractured needle (Fig. 1).

The panorama showed that the broken needle ran horizontally near the lingual. CBCT revealed that the fragment was close to the medial margin of the ascending mandibular ramus. Since the fractured needle fragment had not yet moved deeply into the posterior part of the tissue, we first attempted the removal of the fragment under local anesthesia. A vertical incision, which was parallel to the anterior mandibular ramus, was made under local anesthesia. The blunt dissection technique using a mosquito was performed to retrieve the needle fragment (Fig. 2A).

The needle was retrieved relatively straight, with no bending. Sutures were tied after the removal of the fractured needle, and the stitches were subsequently removed approximately 7 days later. After about 2 weeks, the pain disappeared without any specific complications, apart from the difficulty in opening the mouth.

2. Case 2

A 4-year-old female patient was referred to our department for oral maxillofacial surgery to remove a needle that was fractured in the left pterygomandibular space. The needle had broken due to the abrupt movement of the patient during administration of an inferior alveolar nerve block anesthesia with a 30-gauge needle, to treat a cavity in the mandibular posterior teeth. She was referred to the department of oral maxillofacial surgery, via the pediatric dentistry department.

Instead of a local anesthetic, the patient was administered a general anesthetic to remove the fractured needle fragment, given her age.

Radiographs were acquired (Fig. 3A). Thereafter, a gutta-percha was placed and fixed at the pterygo-mandibular raphe to detect the injured needle, and CBCT was performed (Fig. 3B-3C).

The tip of the needle had moved along the posterior interior upper part and was located at the base of the

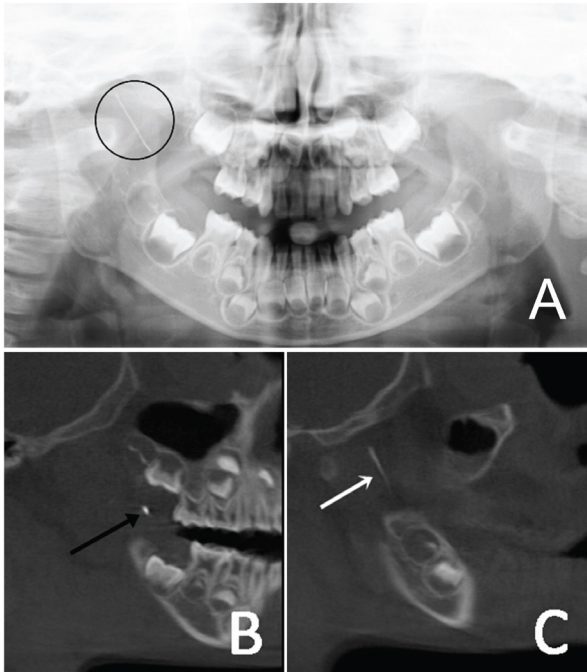


Fig. 3. Preoperative radiographic images showing the broken needle and gutta-percha. (A) Broken dental needle in panoramic view, and a computed tomography (CT) sagittal view of the (B) gutta-percha and (C) broken dental needle.

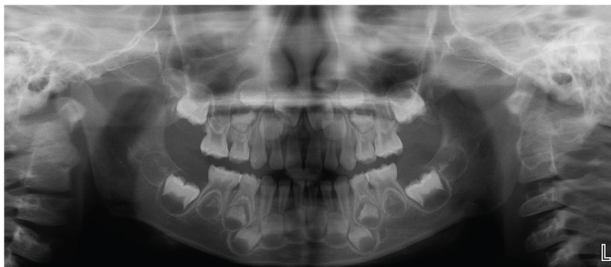

Fig. 4. Postoperative panoramic radiograph showing the removal of the fractured needle.

skull. Further, the fractured needle was in the tissue in a bent state. Under general anesthesia, a vertical incision was made in parallel to the anterior mandibular ramus; a blunt dissection was performed with a mosquito. A considerable amount of fat was discharged during the dissection, which had to be first cleaned up before the structures could be identified. A blunt dissection was then performed. We detected the needle fragment and removed the bent fractured needle fragment (Fig. 2B). After the removal of the needle fragment, the sutures were tied and stitches were removed approximately 12 days later. There were no complications (Fig. 4).

DISCUSSION

In the cases reported here, the fractured needle fragments were removed following an inferior alveolar nerve block. Since needle breakages most commonly occur in the pterygomandibular space, caution is always advised because of the existence of vital structures, including nerves and blood vessels.

Augello et al. [1] reviewed the literature over 50 years and reported that 70% of needle breakage events occur in the pterygomandibular space. This highlighted the need to pay careful attention during the administration of inferior alveolar nerve block.

In the two cases reported here, the needle breakages occurred with 30-gauge needles. Augello et al. [1] also reported that 68% of cases of needle breakages following the administration of inferior alveolar nerve block were associated with the use of a 30-gauge needle.

Augello et al. [1] reported that 76% of dentists use a 30-gauge needle, because of the perception that the use of a thinner needle is associated with less pain. However, it is generally known that pain is not associated with the diameter of needles. Fuller et al. [3] and Mollen et al. [4] reported that although there are individual differences in pain, there were no significant differences in the perception of pain with the use of 25-, 27-, and 30-gauge needles. However, most private clinics and university hospitals do not stock various sized needles. Currently, we have three needle sizes, i.e., the 27-gauge 21 mm, 27-gauge 32 mm, and 30-gauge 21 mm, thus, using a 30-gauge needle requires extreme care.

In addition, thinner needles are prone to cause more pain because the pressure applied on the syringe is much greater with a small gauge needle [5], so it is advisable to use of a 27-gauge 21 mm needle, instead of a 30-gauge 21 mm needle, for young patients who have a low pain threshold.

Blum et al. [6] reported 100 cases of needle breakage that occurred during the 14 years, from 1914–1928. Since

then, the incidence of needle breakage has decreased owing to the development of stainless and flexible alloys, and the use of disposable dental needles. However, many cases of needle fractures have been continued to be constantly reported since 2000 [1]. Recently, Kim and Moon [7] reported the removal of a needle fracture fragment using three-dimensional computed tomography (3-D CT); Lee et al. [8] reported the removal of broken needle via a microscopic approach. Lee et al. [9] also reported the removal of broken needles following the administration of inferior alveolar nerve block to a pediatric patient. Although it is a rare event, if a needle fracture occurs, every effort should be made to remove the needle fragment as soon as the breakage occurs. It is important to detect the exact location of the fracture needle to effectively retrieve it. The surgeon must be familiar with the anatomical structures to accurately locate the fragment using 3D-CT. The use of a metal detector to effectively detect and remove the fragments of a foreign body located in the oral cavity has been previously reported [2]. In 2008, Nezafati and Shahi [5] reported the retrieval of a broken needle using a mobile digital C-arm. Further, in Korea, a case where a small C-shaped dental instrument was used to remove the fractured needles during inferior alveolar nerve block anesthesia was also introduced [10]. In the second case in this report, although a C-arm was used in the orthodontic surgery, it was difficult to use at the same time as the surgery as it was large. Thompson et al. [11] located the fractured needles with an image intensifier using two 19-gauge venipuncture needles. Further, recently, Lee and Zaid [12] reported the removal of the fragment using surgical navigation after locating the needle.

However, even with the use of various methods to locate the position of the broken needle, the surgeon had to remove the tissue using surgery, while being directly guided visually. As mentioned above, first, the anatomical structures must be well-recognized. Then, a wide field of view must be illuminated using a bright luminous source, such as a headlight. Thereafter, homeostasis must

be properly established, before the fractured segment can be finally found with blunt dissection.

The causes of broken needles are the unanticipated movement of the patient, the bending of the tip of the needle before usage, or a defect in a needle. The prevention of needle breakage is, however, crucial. The use of a long needle when possible, the use of a 27-gauge needle (rather than a 30-gauge needle), and refraining from changing the direction of the needle after inserting it, is recommended for conduction anesthesia. Additionally, bending the tip of needle before usage is also recommended. A part of the needle should always be visible to the surgeon during the procedure.

It should also be noted that young patients can move abruptly and unexpectedly, so the use of a mouth gag is advisable to avoid sudden mouth closure during the administration of inferior alveolar nerve block anesthesia. If a fracture should occur, secondary complications can be prevented by promptly sending the patient to a better-equipped hospital, to avoid the movement of fragments deeper into the tissue.

AUTHOR ORCIDS

Jae-Seek You: <https://orcid.org/0000-0001-7638-9583>

Su-Gwan Kim: <https://orcid.org/0000-0002-0424-9984>

Ji-Su Oh: <https://orcid.org/0000-0002-8369-5025>

Hae-In Choi: <https://orcid.org/0000-0002-2425-9506>

Myeong-Kwan Jih: <https://orcid.org/0000-0001-9579-076X>

ACKNOWLEDGEMENTS: This study was supported by the research fund from Chosun University, 2014.

REFERENCES

1. Augello M, von Jackowski J, Grätz KW, Jacobsen C. Needle breakage during local anesthesia in the oral cavity - a retrospective of the last 50 years with guidelines for treatment and prevention. *Clin Oral Investig* 2011; 15: 3-8.
2. Moore UJ, Fanibunda K, Gross MJ. The use of a metal detector for localisation of a metallic foreign body in the

- floor of the mouth. *Br J Oral Maxillofac Surg* 1993; 31: 191-2.
3. Fuller NP, Menke RA, Meyers WJ. Perception of pain to three different intraoral penetrations of needles. *J Am Dent Assoc* 1979; 99: 822-4.
 4. Mollen AJ, Ficara AJ, Provant DR. Needles--25 gauge versus 27 gauge--can patients really tell? *Gen Dent* 1981; 29: 417.
 5. Nezafati S, Shahi S. Removal of broken dental needle using mobile digital C-arm. *J Oral Sci* 2008; 50: 351-3.
 6. Blum T. A report of 100 cases of hypodermic needles broken during the administration of oral local anaesthesia. *Dent Cosmos* 1928; 70: 865-74.
 7. Kim JH, Moon SY. Removal of a broken needle using three-dimensional computed tomography: a case report. *J Korean Assoc Oral Maxillofac Surg* 2013; 39: 251-3.
 8. Lee J, Park MW, Kim MK, Kim SM, Seo KS. The surgical retrieval of a broken dental needle: A case report. *J Dent Anesth Pain Med* 2015; 15: 97-100.
 9. Lee H, Kim M, Park H, Seo H, Lee J. Fracture of a dental needle during inferior alveolar nerve block in a young child: A case report. *J Korean Acad Pediatr Dent* 2016; 43: 320-6.
 10. Park SS, Yang HJ, Hwang SJ. Removal of broken instruments in soft tissue at mandibular area using a dental mini C-arm: case reports. *J Korean Assoc Maxillofac Plast Reconstr Surg* 2010; 32: 567-72.
 11. Thompson M, Wright S, Cheng LH, Starr D. Locating broken dental needles. *Int J Oral Maxillofac Surg* 2003; 32: 642-4.
 12. Lee TYT, Zaid WS. Broken dental needle retrieval using a surgical navigation system: a case report and literature review. *Oral Surg Oral Med Oral Pathol Oral Radiol* 2015; 119: e55-e59.