

Molar-Incisor Malformation: Three Cases of a Newly Identified Dental Anomaly

Suji Choi, Jewoo Lee, Jihyun Song

Department of Pediatric Dentistry, College of Dentistry, Wonkwang University

Abstract

Molar-incisor malformation (MIM) is a recently described dental anomaly characterized by root malformation in permanent first molars accompanied sometimes by abnormal root forms in primary second molars or enamel defects in maxillary central incisors. This report presents three cases of MIM along with a review of previous studies.

Three patients exhibited abnormal root forms in the permanent first molars, with varying degrees of deformation. Two of the patients experienced medical events at birth. One of the patients was a monozygotic twin, whose twin sister exhibited normal dentition without any significant abnormalities.

The present report also reviews recently reported cases of MIM in literature. In the management of MIM-associated clinical issues, consideration of microscopic features and accompanying characteristics might facilitate early diagnosis and comprehensive treatment planning.

Key words : Molar-incisor malformation, Permanent first molar, Monozygotic twins

I. Introduction

Tooth development involves complex processes regulated by signaling between the epithelium and neural crest-derived mesenchyme. Disruption of these tightly regulated processes results in abnormal tooth development, which may manifest as aberrations in the number, shape, or mineralized matrix of teeth[1,2].

Root formation is affected by several hereditary disorders, including dentinogenesis imperfecta and dentin dysplasia. Schimke immune-osseous dysplasia, an autosomal recessive disease, causes root malformation along with other clinical symptoms such as microdontia and spondyloepiphyseal dysplasia[3]. Certain metabolic disorders, such as regional odontodysplasia[4], vitamin-D resistant rickets[5], and hypoparathy-

roidism[6], also affect root development. In addition, dental developmental disturbances may be caused by environmental factors such as trauma, infection, and anticancer treatments, including radiotherapy and chemotherapy[7,8].

Recently, a novel dental anomaly inconsistent with the existing categories has been reported. This novel anomaly, termed molar-incisor malformation (MIM)[9] or molar root-incisor malformation (MRIM)[10], involves characteristic root malformation in the permanent first molars accompanied sometimes by abnormal root forms in primary second molars or enamel defects in maxillary central incisors.

This report presents three cases of MIM along with a review of previous studies and a discussion of the etiology and clinical influences of MIM.

Corresponding author : Jihyun Song

Department of Pediatric Dentistry, Daejeon Dental Hospital, Wonkwang University, 77, Dunsan-ro, Daejeon, 35233, Korea

Tel: +82-42-366-1197 / Fax: +82-42-366-1115 / E-mail: amistad@wonkwang.ac.kr

Received September 5, 2016 / Revised November 1, 2016 / Accepted October 24, 2016

II. Case Reports

1. Case 1

A girl was referred from a local clinic at the age of 6 years and 7 months with the chief complaint of short roots in the mandibular permanent first molars on both sides. The guardian reported that the left mandibular second primary molar of the patient had been previously exfoliated because of a short root. The patient had no history of systemic diseases or medical events at birth. On panoramic radiographs, the roots of the mandibular permanent first molars appeared to be mostly undeveloped, and the maxillary permanent first molars exhibited short, thin roots (Fig. 1). The patient visited the hospital 3 years later for treatment of an abscess in the right mandibular area. Clinically, a gingival abscess had formed at the mandibu-

lar right permanent first molar, while the antimere first molar exhibited a rotated crown toward the lingual side. Radiological examination revealed inflammatory bone resorption under the crowns of the bilateral mandibular first molars, with no evidence of deep caries. The corresponding teeth were challenging to maintain. They were extracted after 2 months because of recurrent abscess formation.

The most recent cone-beam computed tomography (CBCT; Alphard VEGA, Asahi Roentgen Ind. Co., Kyoto, Japan) findings of this patient were compared to those acquired 3.5 years ago (Fig. 1). At around 6 years of age, the maxillary left first molar exhibited short roots with open apices, while at around 10 years of age, the corresponding teeth had not only erupted toward the occlusal plane but also exhibited root development and apical closure.

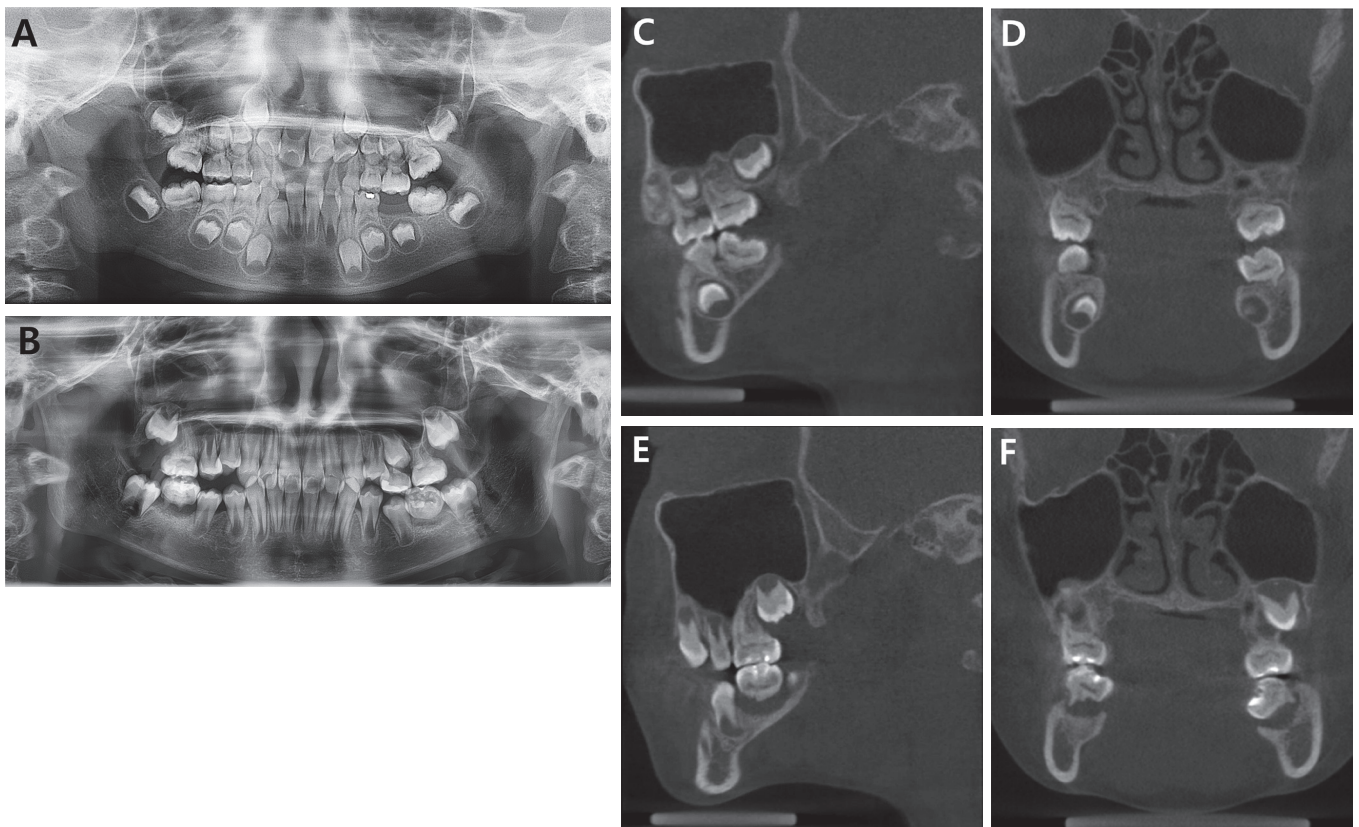


Fig. 1. Radiographs of patient 1. (A) Initial panoramic view. (B) Panoramic view at 3.5 years after first visit. (C, D) Initial cone-beam computed tomography images of the patient. The root of the left maxillary permanent first molar at around 6 years of age appeared to be short, with an open apex. (E, F) At 3.5 years after first visit, the maxillary first molar had not only erupted but also developed roots and apical closure. Inflammatory bone resorption in the mandibular permanent first molars was progressed.

2. Case 2

A 9-year-old girl was referred to our hospital for treatment of inflammation of bilateral mandibular permanent first molars. The patient had a history of preterm birth at a gestational age of 30 weeks and low birth weight (2.2 kg). Panoramic radiography revealed thin and convergent roots in all permanent first molars, with constriction of the cervical area. The upper left primary second molar and bilateral lower primary second molars had already been extracted. The remaining upper right primary second molar exhibited a slit-shaped pulp cavity and atypical roots (Fig. 2A). Because of the abscess, it was decided to induce mesial drifting of the permanent second molar after extraction of the mandibular permanent first molars. After a 2-year follow-up period, over which no adverse symptoms were observed, the patient complained of spontaneous pain in the maxillary right permanent first molar, which was treated by root canal treatment. However, the inflammation persisted, and the bilateral maxillary first molars were extracted after orth-

odontic diagnosis.

Since the patient was revealed to be a monozygotic twin, her twin sister was also subjected to clinical and radiographic examination. Despite the same medical history as the patient, i.e., preterm birth and low birth weight (2.2 kg), the twin sister exhibited normal dentition without any significant abnormalities (Fig. 2B).

3. Case 3

A dental clinic requested evaluation of mesiodens in an 8-year-old boy with a history of surgery for myelomeningocele immediately after normal birth. Upon clinical examination, the maxillary central incisors were found to exhibit wedged-shape enamel defects on the proximal area of the crown (Fig. 3). Panoramic radiographs revealed thin and divergent roots of the permanent first molars. The patient has not exhibited any clinical symptoms till date.

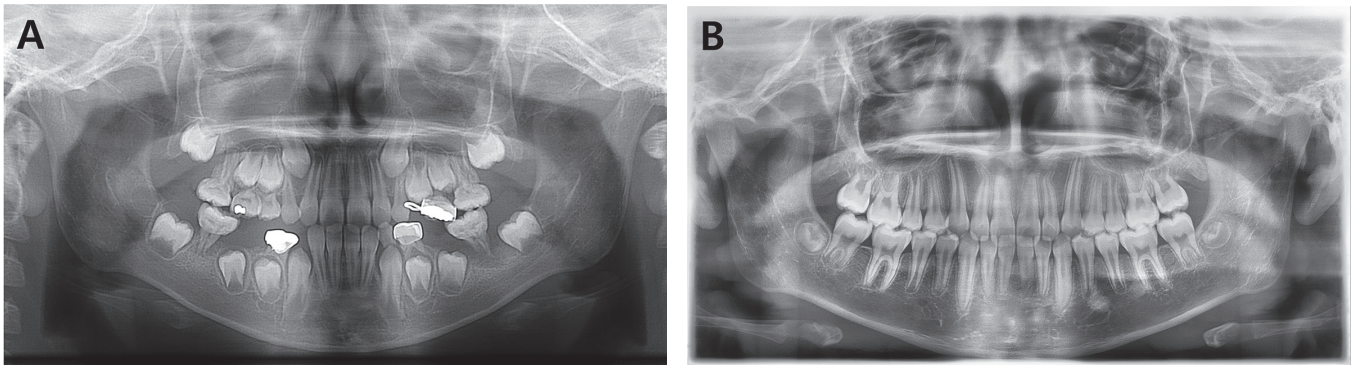


Fig. 2. Radiographs of patient 2 and her twin sister. (A) Initial panoramic view of patient 2 shows short and twined roots of permanent first molars. (B) Panoramic radiograph of her twin sister shows normal occlusion.

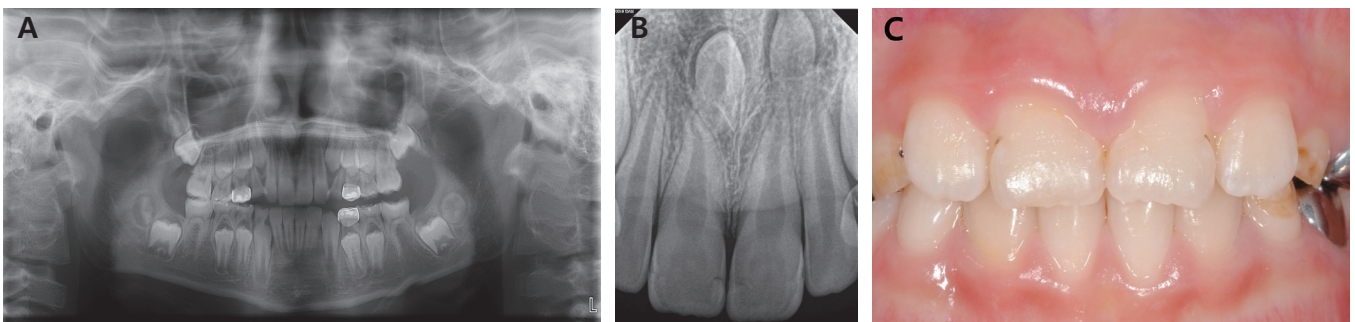


Fig. 3. Radiographs and a clinical photograph of patient 3. (A) Initial panoramic view shows divergent and thin roots of permanent first molars. (B) Intraoral radiograph of central incisors. (C) Clinical photograph of the maxillary central incisors shows wedge-shaped notches in the middle of the crown.

III. Discussion

Molar-incisor malformation (MIM)[9], also referred to as molar root-incisor malformation (MRIM)[10], has unique characteristics. Permanent first molars are typically affected; although the affected teeth exhibit clinically normal crown forms, the roots present divergent, twined, or hypoplastic morphologies, and the pulp chambers are flat-slit shaped. Additionally, MIM can affect primary second molars and permanent maxillary central incisors. Central incisors affected by MIM exhibit cervical constriction and notching of the crown[9-14]. Review of medical history of patients with MIM reveals health problems including neurological disorders, such as meningocele and meningitis, and systemic conditions, such as renal disease, preterm birth, and low birth weight, at birth or in the first 2 years of life in most patients[9-12]. However, not all patients in these reports presented with such medical history, and no particular disease has been specified as the causative factor for MIM. Of the three patients included in the present report, two presented with a medical history of the aforementioned events; preterm birth and myelomeningocele.

Tooth development is a series of reciprocal signaling interactions. Normal root development results from induction between the Hertwig epithelial root sheath and dental papilla after crown formation. Dental anomalies are caused by complex interactions between genetic, epigenetic, and environmental factors during these steps[1]. Genes regulating tooth development have been actively studied, and over 300 genes are known to be involved in cell differentiation, patterning, and morphological differentiation[15]. Animal studies have demonstrated several genes, including *Nfic* (Nuclear Factor I C) [16] and *Ptc* (Phenylthiocarbamide)[17], to be associated with root defects. Additionally, unrooted molars and aberrantly thin incisors have been reported in β -catenin-inactivated mice[18]; however, the relevance of this finding requires further investigation since the mice did not exhibit all of the typical features of MIM.

Although the etiology of MIM is unclear, previous studies have provided some insight. Witt *et al.*[11] reported that MIM results from external adverse events during tooth development rather than from genetic factors. In addition, Lee *et al.*[14] suggested the influence of epigenetic factors, such as aberrations in signaling pathways involved in tooth development, as well as medication on the development of MIM.

Interestingly, in the second case in the present report, only

one of the identical twins was affected by MIM. Although monozygotic twins with discordant phenotypes have been employed to study the effects of environmental factors in the past, the mechanism of discordance is not completely understood. A plausible explanation is the presence of epigenetic differences between monozygotic twins. Epigenetics, in its broad sense, refers to the phenomenon of change in gene expression without changes in the nucleotide sequence[19]. Although monozygotic twins are genetically identical, they generally do not exhibit the same phenotype. Examples of phenotypic discordance include disease susceptibility and a wide range of anthropomorphic features[20]. In lifelong studies of 80 pairs of monozygotic twins, Fraga *et al.*[20] demonstrated that epigenetic differences such as DNA methylation and histone acetylation affect the gene-expression portrait throughout life. Additionally, a previous study reported discordance in dental features, such as hypodontia and supernumerary teeth, between monozygotic twins and suggested that phenotypic variation in monozygotic twins is attributable to minor variations in epigenetic events during odontogenesis[19]. In case of the second patient in this report, despite the same genotype and shared systemic and environmental conditions, the monozygotic twin sister of the patient was not affected by MIM. Therefore, the etiology of MIM in this patient may be attributed to epigenetic factors, which supports the findings of previous studies.

However, in a recent study, Wright *et al.*[10] reported the absence of MIM in most individuals with shared environmental stressors or medical events and, based on the findings, proposed the possibility of unique genotypes in patients with MIM. Therefore, it is necessary to further investigate whether environmental factors actually function as trigger points in genetic predisposition to MIM.

Studies on microscopic analysis of teeth affected by MIM have identified amorphous hard tissue within the pulp cavity. Witt *et al.*[11] suggested that the mineralized plate at the cemento-enamel junction (CEJ), which they termed cervical mineralized diaphragm (CMD), forms as a calcified globule in response to damage of the vascular plexus at the dental papillar base. The CMD functions as a mechanical barrier during dentin formation and thus interferes with dental root formation. Lee *et al.*[14] categorized the thickened pulpal floors into the upper, middle, and lower layers. Microstructural findings of these regions indicated that MIM might result from their failure to differentiate appropriately because of the influence of external

stimuli on the apical pulp and dental follicle.

In case 1 in the present report, micro-CT findings (SkyScan 1174; SkyScan bvba, Aartselaar, Belgium) of an extracted mandibular permanent first molar revealed a mineralized plate in the cervical area, extending to the CEJ. Canals that penetrated the three layers of the pulp cavity appeared to have failed to differentiate into mature canals. Additionally, undeveloped roots were also observed (Fig. 4). Although the mineralized plate has been reported to be located at the level of the CEJ[11], in the second case in the present report, it was observed at mid-height of the crown of the maxillary permanent first molar. The external shape of the crown was also affected, which had resulted in a fissure in enamel at the plate region and irregular protrusions of cervical enamel at the lower region (Fig. 5A). In addition, several dysplastic roots were twined, leading to highly irregular canal morphology and presence of calcified materials in the pulp cavity, which was speculated to be a cause of persistent inflammation and also complicate the approach to the canals (Fig. 5B).

According to previous epidemiological studies, permanent first molars are always affected by MIM. Root malformations in second primary molars account for 50% of MIM cases[10,12], while enamel defects of central incisors have been reported to account for 40 - 58% of MIM cases[9,10]. In the present report, enamel defects of permanent maxillary central incisors were observed only in patient 3, who exhibited a very mild root morphological change in the permanent first molar and

maintained a clinically desirable dental state. While the extent of root deformity in teeth affected by MIM is highly diverse and has yet to be classified, the severity of root malformation appears not to be associated with the area of involvement in previous studies. Factors associated with the affected region of MIM require further investigation.

Dental anomalies can lead to clinical issues including impaction, early exfoliation, space loss, spontaneous pain, periapical abscess, and anterior esthetic problems[9]. In patient 1 in the present report, comparative evaluation of initial and final CBCT findings revealed root development, apical closure, and tooth eruption in the maxillary first molar at 3.5 years after initial presentation, which suggested that pulp vitality was maintained for a certain period following tooth eruption into the oral cavity. However, although the pulp was not affected by carious lesions, the patient exhibited disruption of alveolar bone and inflammatory resorption. Micro-CT findings of the extracted mandibular permanent first molar in patient 1 revealed accessory canals penetrating the pulpal floor, which appeared to present adequate paths for the transmission of bacteria and microorganisms between the pulp and periodontal tissue. However, it is uncertain whether the corresponding lesion was primarily caused by pulp necrosis or imperfect periodontal support. Recently, Yue and Kim[21] reported the successful maintenance of an MIM-affected first molar by conservative root canal treatment using CBCT. Therefore, root canal treatment may be considered for apical abscesses in MIM-

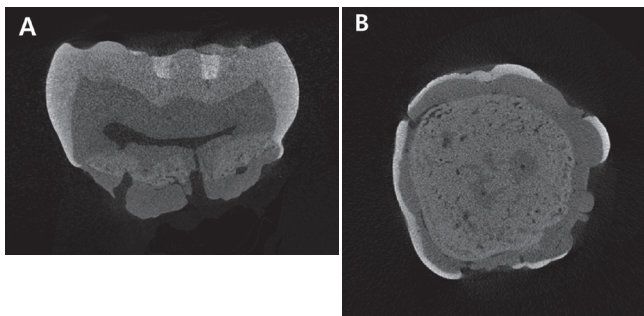


Fig. 4. Micro-computed tomographic appearance of the mandibular permanent first molar of patient 1. (A) Bucco-lingual section. Mineralized plate extending to the cemento-enamel junction was observed. Some of the canals penetrated the three layers of the pulpal floor. (B) Horizontal section through the cemento-enamel junction.

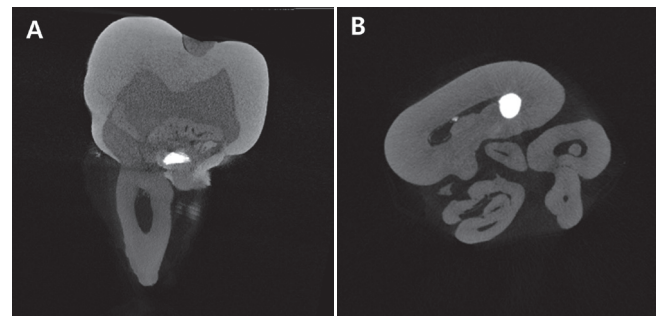


Fig. 5. Micro-computed tomographic appearance of the maxillary permanent first molar of patient 2. (A) Bucco-lingual section. Mineralized layer of the maxillary first molar was observed at mid-height of the crown. Enamel fissure at the plate region and irregular protrusions of enamel at the cervical region were observed. (B) Horizontal section. Several dysplastic roots were twined, leading to highly irregular canal morphologies.

affected teeth, and a conservative treatment approach should be preferentially chosen. However, in patient 1 in the present report, the extracted mandibular first molar exhibited nearly undeveloped roots with accessory canals on the pulpal floor, which limited the possibility of root canal treatment. Clinical trials investigating techniques for the detection and sealing of anatomical structures for preservation of affected teeth are required in the future.

IV. Summary

Molar-incisor malformation, a recently described dental anomaly, is characterized by root malformation in permanent first molars; it may also affect the primary second molars and maxillary central incisors.

This report presents three cases of MIM along with a review of relevant literature. Although our findings indicate that MIM is caused by epigenetic discrepancies associated with environmental factors, further studies are required to confirm the same.

In terms of the microstructure of MIM, a mineralized plate, reported to be typically located in the cervical area, was also observed in the mid-crown region in one of the present cases.

Teeth affected by MIM require careful attention to mitigate the risk of clinical problems; however, even teeth without caries can exhibit inflammation. Consideration of the characteristics and anatomy of MIM-affected teeth might be helpful to clinicians and could contribute to improved clinical trials.

References

1. Brook AH : Multilevel complex interactions between genetic, epigenetic and environmental factors in the aetiology of anomalies of dental development. *Arch Oral Biol*, 54:3-17, 2009.
2. Cobourne MT, Sharpe PT : Diseases of the tooth: the genetic and molecular basis of inherited anomalies affecting the dentition. *Wiley Interdiscip Rev Dev Biol*, 2:183-212, 2013.
3. Morimoto M, Kérourédan O, Boerkoel CF, *et al.* : Dental abnormalities in Schimke immuno-osseous dysplasia. *J Dent Res*, 91:29-37, 2012.
4. Spini TH, Sargenti-Neto S, Loyola AM, *et al.* : Progressive dental development in regional odontodysplasia. *Oral Surg Oral Med Oral Pathol Oral Radiol Endod*, 104:40-45, 2007.
5. Goodman JR, Gelbier MJ, Bennett JH, Winter GB : Dental problems associated with hypophosphataemic vitamin D resistant rickets. *Int J Paediatr Dent*, 8:19-28, 1998.
6. Kelly A, Pomarico L, de Souza IPR : Cessation of dental development in a child with idiopathic hypoparathyroidism: a 5-year follow-up. *Oral Surg Oral Med Oral Pathol Oral Radiol Endod*, 107:673-677, 2009.
7. Zilberman Y, Fuks A, Lustmann J, *et al.* : Effect of trauma to primary incisors on root development of their permanent successors. *Pediatr Dent*, 8:289-293, 1986.
8. Pedersen LB, Clausen N, Poulsen S, *et al.* : Microdontia and hypodontia of premolars and permanent molars in childhood cancer survivors after chemotherapy. *Int J Paediatr Dent*, 22:239-243, 2012.
9. Lee HS, Kim SH, Song JS, *et al.* : A new type of dental anomaly: molar-incisor malformation (MIM). *Oral Surg Oral Med Oral Pathol Oral Radiol*, 118:101-109, 2014.
10. Wright JT, Curran A, Kim JW, *et al.* : Molar root-incisor malformation: considerations of diverse developmental and etiologic factors. *Oral Surg Oral Med Oral Pathol Oral Radiol*, 121:164-172, 2016.
11. Witt CVA, Hirt T, Rutz G, Luder HU : Root malformation associated with a cervical mineralized diaphragm - a distinct form of tooth abnormality? *Oral Surg Oral Med Oral Pathol Oral Radiol*, 117:311-319, 2014.
12. Lee EK, Kim YJ, Kim HJ, Nam SH : Abberant root morphology in the permanent first molars: case reports. *J Korean Acad Pediatric Dent*, 42:172-179, 2015.
13. McCreehy C, Robbins H, Newell A, Mallya SM : Molar-incisor malformation: two cases of a newly described dental anomaly. *J Dent Child*, 83:33-37, 2016.
14. Lee HS, Kim SH, Song JS, *et al.* : Microscopic analysis of molar-incisor malformation. *Oral Surg Oral Med Oral Pathol Oral Radiol*, 119:544-552, 2015.
15. Thesleff I : The genetic basis of tooth development and dental defects. *Am J Med Genet A*, 140:2530-2535, 2006.
16. Park JC, Herr Y, Cho MI, *et al.* : Nfic gene disruption inhibits differentiation of odontoblasts responsible for root formation and results in formation of short and abnormal roots in mice. *J Periodontol*, 78:1795-1802, 2007.
17. Nakatomi M, Morita I, Eto K, Ota MS : Sonic hedgehog signaling is important in tooth root development. *J Dent Res*, 85:427-431, 2006.
18. Kim TH, Bae CH, Cho ES, *et al.* : β -catenin is required in odontoblasts for tooth root formation. *J Dent Res*, 92:215-

221, 2013.

19. Townsend GC, Richards L, Schwerdt W, *et al.* : Epigenetic influences may explain dental differences in monozygotic twin pairs. *Aust Dent J*, 50:95-100, 2005.
20. Fraga MF, Ballestar E, Esteller M, *et al.* : Epigenetic differences arise during the lifetime of monozygotic twins. *Proc Natl Acad Sci U S A*, 102:10604-10609, 2005.
21. Yue W, Kim E : Nonsurgical endodontic management of a molar-incisor malformation-affected mandibular first molar: A case report. *J Endod*, 42:664-668, 2016.

국문초록

Molar-Incisor Malformation: 최근 확인된 치아 이상의 증례 보고

최수지 · 이제우 · 송지현

원광대학교 치과대학 소아치과학교실

Molar-incisor malformation (MIM)은 최근에 알려진 치아 이상으로 제1대구치의 치근 형태 이상이 특징적이며, 제2유구치의 비정상적 치근 형태 및 중절치의 법랑질 결함을 동반하기도 한다. 본 연구는 MIM으로 진단한 3명의 환아에 대하여 보고하고, 이에 관한 문헌 고찰을 하고자 한다.

3명의 환아 모두 제1대구치의 치근 형태 이상을 보였으며, 그 정도는 다양했다. 2명의 환아는 출생 시 의학적 병력을 가지고 있었으며, 한 명의 환아는 일란성 쌍둥이였다. 그러나 쌍둥이 동생의 임상 및 방사선학적 검사 결과 특별한 이상이 없는 정상 치열이었다.

본 연구는 최근에 보고되고 있는 MIM 증례에 관한 기술 및 방사선학적 관찰로, 해당 환아의 임상적 관리 시 이환 치아의 방사선학적 특성 및 미세해부학적 구조 및 수반하는 특성에 관한 고려는 조기 진단 및 포괄적 치료계획 수립에 도움이 될 것으로 생각된다.

주요어: Molar-incisor malformation, 제1대구치, 일란성 쌍둥이