

# The Effects of Miniscalpel Acupuncture on Cervicogenic Headache: A report of three cases<sup>※</sup>

Seungah Jun<sup>1</sup>, Jung Hee Lee<sup>1</sup>, Han Mi Gong<sup>1</sup>, Yeon Joong Chung<sup>1</sup>, Ju Ran Kim<sup>1</sup>,  
Chung A Park<sup>2</sup>, Seong Hun Choi<sup>3</sup>, Geon Mok Lee<sup>4</sup>, Hyun Jong Lee<sup>1</sup>, Jae Soo Kim<sup>1\*</sup>

<sup>1</sup>Department of Acupuncture & Moxibustion medicine, College of Korean medicine, Daegu Haany University

<sup>2</sup>Department of Diagnostics, College of Korean medicine, Daegu Haany University

<sup>3</sup>Department of Anatomy and Histology, College of Korean medicine, Daegu Haany University Daegu

<sup>4</sup>Department of Acupotomy, LeeGeonmok Wonli Korean Medicine Hospital



## [Abstract]

**Objectives** : This study examined the effects of miniscalpel acupuncture (MA) in three patients with cervicogenic headache.

**Methods** : Patients were treated with MA, which was performed once per week for three weeks. A headache score, visual analogue scale (VAS), and neck disability index (NDI) were used for the evaluation of treatment effects.

**Results** : In cases 1, 2, and 3, the headache score decreased from 4 to 1, 3 to 0, and 3 to 1, respectively. The VAS score decreased from 8.5 to 1.9, 5 to 0.4, and 5.3 to 2 in cases 1, 2, and 3, respectively. The NDI score decreased from 28 to 4, 50 to 4, and 38 to 16 in cases 1, 2, and 3, respectively.

**Conclusion** : MA appears to be effective for the treatment of cervicogenic headache. Further data should be collected and a comparative study using other treatment methods should be performed.

### Key words :

Miniscalpel acupuncture;  
Cervicogenic headache;  
Neck pain;  
Herniated intervertebral  
disc of cervical spine;  
Acupotomy

Received : 2017. 07. 07.

Revised : 2017. 07. 20.

Accepted : 2017. 07. 22.

On-line : 2017. 08. 20.

※ This study was supported by a grant of Comprehensive and Integrative Medicine R&D project through Comprehensive and Integrative Medicine Institute (CIMI), funded by the Ministry of Health & Welfare, Republic of Korea (Grant Number: 090-091-3000-3038-301-320-01).

\* Corresponding author : Department of Acupuncture & Moxibustion medicine, College of Korean medicine, Daegu Haany University, 136, Sincheondong-ro, Suseong-gu, Daegu, 706-828, Republic of Korea

Tel : +82-53-770-2108 E-mail : Jaice@daum.net

## I. Introduction

Neck pain is a common musculoskeletal disease<sup>1)</sup>. As the dependence on computer and smart phone technology increases, so does the prevalence of neck pain. The prevalence rate of neck pain also increases with age<sup>2)</sup>. As the pain progresses, neck pain can cause other serious problems such as temporomandibular joint pain, headache, dizziness, and nausea.

Headache sourced from the cervical spine or soft tissues in the neck is called cervicogenic headache<sup>3)</sup>. Theoretically, cervicogenic headache is a unilateral headache with symptoms and signs, such as a reduced range of motion and neck stiffness<sup>4)</sup>.

There are many treatments for neck pain and cervicogenic headache, such as pharmacological treatment, physical and manual therapy, psychological and behavioral treatment, anesthetic blockade and neurolysis, and surgical treatment<sup>5)</sup>. Medications such as antidepressants, antiepileptic drugs, analgesics, and muscle relaxants are used for pain control<sup>6)</sup>. Recent studies have reported that physical and manual therapies are effective at reducing headache frequency and intensity<sup>7)</sup>. However, pharmacologic treatment or manual therapy alone usually provides only modest improvement for this condition. Other studies suggest that no drugs effectively treat cervicogenic headache<sup>3)</sup>. The effects of the conventional therapies are limited, and the validity of many of the treatment guidelines is unclear<sup>5)</sup>. Because of the limited benefits of conventional therapy, many patients seek alternative and complementary medical treatments, such as acupuncture.

Acupuncture is one of the most popular and effective alternative and complementary medical treatments. Miniscalpel acupuncture (MA) tends to obtain better therapeutic effects on musculoskeletal pain compared with regular acupuncture treatment<sup>8)</sup>. The goal of MA is to recover the kinetic state of soft tissue through the peeling of adhesions and the removal of attached tissues,

with the advantage of quicker recovery and pain reduction compared with regular acupuncture<sup>9)</sup>.

In the present study, we observed significant therapeutic effects of MA in 3 patients who visited the Acupuncture and Moxibustion department at the Daegu Oriental Hospital of Daegu Haany University, Republic of Korea for cervicogenic headache. Because the patients' symptoms were severe and chronic, MA was used rather than acupuncture.

## II. Methods

Three patients received MA four times over 4 weeks at Daegu Oriental Hospital of Daegu Haany University, Daegu, Republic of Korea. Before the procedure, the patients were provided with sufficient information and explanation regarding the treatment. Informed consent to participate in the study was obtained.

### 1. Miniscalpel acupuncture (MA)

A total of 3 treatment sessions were conducted. Following the first treatment, subsequent MA sessions were conducted at intervals of 4 to 10 days. Because all three patients had similar symptoms, such as neck pain and headache, the same MA points were used for all patients. Sterilized, disposable miniscalpels (0.5 mm × 50 mm; DongBang Acupuncture Inc., Korea) were used. The MA points were as follows<sup>10)</sup>: the upper site of GV16, GB20, GB12, GV15, BL10, GV14, and the C4, C5, and C6 spinous processes. A total of 12 sites related to pain were selected for treatment. Except for MA, no other interventions, such as moxibustion, herbal drugs, or physical therapy, were used.

## 2. Assessment

All assessments were performed prior to each treatment session.

### 1) Headache scale

The fifth question of the Neck Pain-Related Disability Score relates to headaches<sup>11</sup>. The question is assessed using a 6-point scale from 0 to 5, where 0 denotes the absence of the pain, 1 denotes infrequent slight headache, 2 denotes infrequent moderate headache, 3 denotes frequent moderate headache, 4 denotes frequent severe headache, and 5 denotes almost constant headache.

### 2) Visual Analogue Scale (VAS)

The VAS is a 10-cm measurement instrument to determine the severity of pain. Patients rate their pain on a scale of 0 to 10, where 0 indicates the absence of pain and 10 indicates the worst pain imaginable<sup>12,13</sup>. The VAS score was used to indicate pain at the time.

### 3) Neck Disability Index (NDI)

Neck pain-related disability was evaluated using the validated Korean version of the NDI. The NDI is used to measure self-perceived disability caused by neck pain. It consists of 10 items that cover pain intensity, concentration, functional activities, and headache<sup>10</sup>. Each question is assessed using a 6-point scale from 0 to 5, where 0 indicates the absence of a problem and 5 indicates severe disability caused by neck pain.

## III. Case studies

### 1. Case 1

#### 1) Patient

Kim ○○, F/31

#### 2) Chief complaints

Chronic neck pain and frequent headache.

#### 3) Medical history

No relevant history.

#### 4) Present medication

None.

#### 5) Present complaints

The patient had suffered from neck pain and headache for more than 2 years. The specific onset was vague. The patient visited the local hospital and was treated with physical therapy and medicine whenever the pain became severe. A computed tomography (CT) scan performed on February 17<sup>th</sup>, 2017 showed kyphosis. Mild central disc protrusion at C4-5 and C5-6, and mild left central disc protrusion at C6-7 were diagnosed. The patient frequently took medication for headache. Although the patient received these conventional treatments, the symptoms persisted. For this reason, she visited Daegu Oriental Hospital of Daegu Haany University on February 25, 2017.

#### 6) Treatment progress

Before treatment, the patient's NDI headache score was 4 (frequent severe headache). However, after the first treatment session, the score decreased to 3 (frequent moderate headache). After the third session (fourth visit), the score decreased to 2 (infrequent moderate headache).

The VAS score showed improvement at almost every visit. At the first visit, the score was 8.5. The score decreased to 6.4 at the second visit, but increased slightly, to 7.1, at the third visit. At three treatment sessions, the score was 3.5.

The NDI score also decreased as the treatment progressed. At the first visit, the NDI was 28. It decreased to 10 by the fourth visit (Fig. 1).

#### 7) Follow up progress

After four weeks later (on April 15, 2017), the pa-

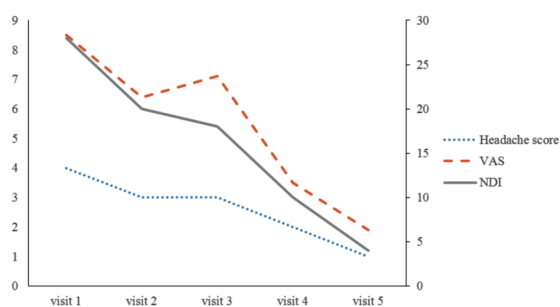


Fig. 1. Changes in the headache score, VAS, and NDI score in case 1

tient visited the hospital for follow up. The NDI headache score was 1 (infrequent slight headache). The VAS was 1.9 and the total NDI score had decreased to 4 (Fig. 1). The patient no longer took medication for headaches.

## 2. Case 2

### 1) Patient

Kwon O O, F/27

### 2) Chief complaints

Headache, neck stiffness, and neck heaviness.

### 3) Medical history

The patient underwent surgery for right carpal tunnel syndrome in 2009, for a right cruciate ligament tear in 2010, and for a right meniscus tear in 2015.

### 4) Present medication

None.

### 5) Present complaints

The patient had headaches from time to time. She had been experiencing pain for one year. The pain had become progressively worse in recent months. She had been treated with physical therapy and medication at the local hospital but the symptoms gradually worsened over time. Right central subarticular minimal protrusion at the C5–6 disc and cervical straightening were diagnosed

from a computed tomography (CT) scan March 15<sup>th</sup>, 2017, right central subarticular minimal protrusion at C5–6 disc and cervical straightening were diagnosed. She first visited Daegu Oriental Hospital of Daegu Haany University on March 21, 2017.

## 6) Treatment progress

Before treatment, the patient's NDI headache score was 3 (frequent moderate headache). After the first MA treatment, the score decreased to 2 (infrequent moderate headache). After the third and fourth visits, the score had decreased to 1 (infrequent slight headache).

The VAS score at the first and second visits was 5.0. The patient said that the even though the headaches had decreased, the neck pain persisted. At the third visit, the VAS score had decreased to 3.5, indicating that MA treatment resulted in improvement in both neck pain and headache. After the third treatment (fourth visit), the score had decreased to 2.1.

The NDI score also decreased as treatment progressed. At the first visit, the NDI was 50. It had decreased to 4 by the fourth visit (Fig. 2).

## 7) Follow up progress

On May 15, 2017 (five weeks after the final treatment), the patient visited the hospital for follow up. The NDI headache score in NDI was 0, which means absence of pain. The VAS was 0.4 and the total NDI score remained 4 (Fig. 2). The patient no longer had neck pain when lifting heavy objects,

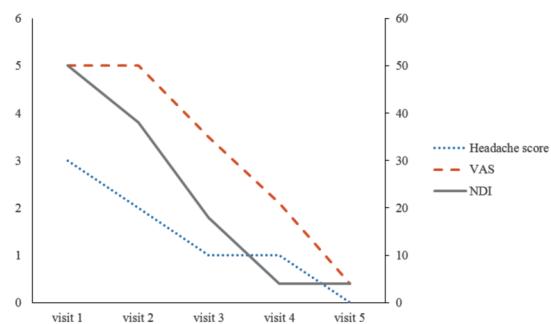


Fig. 2. Changes in the headache score, VAS, and NDI in case 2

reading, driving, or working. In the NDI test, she only complained of slight neck pain in the recreation section.

### 3. Case 3

#### 1) Patient

Chu O O, M/26

#### 2) Chief complaints

Frequent headache and neck pain.

#### 3) Medical history

None.

#### 4) Present medication

None.

#### 5) Present complaints

The patient had experienced frequent headache and neck pain for several years. The initial onset occurred 5 years prior. The patient went for a massage whenever the pain increased. He complained that the pain increased after studying or working. Neck stiffness, neck pain, and headache increased simultaneously with stress. A bulging contour of the disc at C6–7 and straightening of the C spine curvatures were diagnosed following a CT on March 13, 2017. The patient first visited Daegu Oriental Hospital of Daegu Haany University hospital on March 21, 2017.

#### 6) Treatment progress

At the first visit, the NDI headache score was 3, (frequent moderate headache). At the third visit, the pain started to improve. The headache score decreased to 1 (infrequent slight headache). At the fourth visit, the score increased to 2 (infrequent moderate headache).

The VAS was 5.3 at the first visit and decreased to 4.5 and 2.7 at the second and third visits, respectively. The VAS score increased to 4.2 at the fourth visit. The patient complained that the

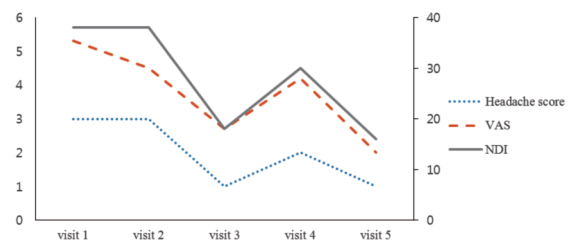


Fig. 3. Changes in the headache score, VAS, and NDI in case 3

headache and neck pain increased after studying for long durations.

The total NDI score was 38 at the first visit and showed no change until the second visit. After the second treatment at the third visit, the score decreased to 18. At the fourth visit the score increased to 30, but then decreased after time (Fig. 3).

#### 7) Follow up progress

On May 10, 2017 (four weeks after the final visit), the patient visited the hospital for follow up. The NDI headache score was 1, which (infrequent slight headache). The VAS decreased to 2 and the total NDI score decreased to 16 (Fig. 3). The patient no longer had pain when working or driving. He still complained of slight headache and neck pain when reading.

## IV. Discussion

Cervicogenic headache is a common clinical disorder. There are some controversial issues regarding cervicogenic headache. One chapter in a leading headache textbook indicates that this concept of cervicogenic headache is not fully acknowledged<sup>14</sup>. Although the notion that headaches can be generated from structures in the neck has long been established, only in the past two decades has the topic gained attention in mainstream headache and pain literature<sup>5</sup>.

Headache and neck pain are closely related clinically. People with chronic neck pain or acute traumatic neck pain often complain of headache. Some patients with severe headache also complain of nausea and vomiting.

Cervicogenic headache is a unilateral headache with symptoms and signs, such as reduced range of motion and stiffness of the neck<sup>4</sup>. Cervicogenic headache is not an independent disease but a myriad of symptoms. Nerves, nerve roots, ganglia, uncovertebral joints, facet joints, ligaments, and muscles may be involved in the induction of symptoms.

One study reported that approximately 70% of people with frequent headaches experience neck pain<sup>15</sup>. Approximately 80% of patients with whiplash injuries report headaches within 2 months of injury<sup>16</sup>. Approximately 25% of patients with whiplash continue to have neck pain for 2 years or longer, with the majority also complaining of headaches<sup>17</sup>. The pathophysiology and cause of cervicogenic headache is controversial<sup>18</sup> but the pain is thought to be caused by muscular, neurologic, osseous, articular, or vascular structures in the neck<sup>3</sup>.

Even though cervicogenic headache is commonly encountered in clinical practice, there is a lack of effective treatment. Cervicogenic headache is often treated using pharmacologic, non-pharmacologic, manipulative, anesthetic, or in some cases, surgical treatments. Medications used include analgesics, antidepressants, muscle relaxants, and antiepileptic drugs<sup>6</sup>. Most patients become dependent on simple analgesics because they are desperate to find pain relief. However, medication alone is often ineffective or provides only limited benefit<sup>18</sup>. Manual therapy and exercises are also used in treatment but it is often difficult to achieve a satisfying outcome with either<sup>7</sup>.

Headache from neck disability can be explained from several diverse aspects. The mechanism of headache that occurs in the frontal and temporal areas tends to relate to the convergence between cervical nociceptive and trigeminal afferents in the trigeminocervical complex in the upper cervical

spine<sup>3</sup>. This may be the basis for the well-known patterns of referred pain from the trapezius and sternocleidomastoid muscles to the face and head<sup>6</sup>.

In addition, many patients with migraine and tension-type headaches can find trigger points in the muscles of the head and neck region<sup>19</sup>. Furthermore, secondary headache associated with neck injury or with various dysfunctions of the craniocervical structures are likely to have trigger points in the neck and head muscles. For example, occipital headache might be referred from the trapezius, sternocleidomastoid, semispinalis capitis, semispinalis cervicis, splenius cervicis, suboccipitals, occipital, digastric, or temporalis muscles. Vertex pain can be caused by the sternocleidomastoid and splenius capitis muscles. Temporal headaches can be referred from the trapezius, sternocleidomastoid, splenius cervicis, suboccipital, or semispinalis capitis muscles. The sternocleidomastoid, semispinalis capitis, frontalis, and zygomaticus major muscles can cause frontal headaches. It is recognized that trigger points are not simply a co-occurrence in head pain but may be activating factors for certain types of headaches<sup>20</sup>. These facts can be used as the theoretical basis for treating the neck in patients with headache.

In the present study, MA treatment was performed to peel adhesions and remove attached tissues to recover the kinetic state of the soft tissues. GV16 is below the external occipital protuberance and has an insertion at the nuchal ligament and an origin at the trapezius muscle. GB20, which is 2–2.5 cm below the external occipital protuberance, is related to the rectus capitis posterior major and oblique capitis superior muscles. GB12 is 4–4.5 cm below the external occipital protuberance. GV12, at the C2 spinous process, has origins at the semispinalis capitis, obliquus capitis inferior, and the rectus capitis posterior major. BL10 is located on the side of the C2 spinous process. BL10 targets the facet joint. Apart from these MA points, the C4, C5, and C6 spinous processes are used as acupoints. The C4, C5, and C6 spinous processes have origins at the semispinalis capitis. GV14 is located at the

C7 spinous process.

In the present study, all three patients complained of headache and neck pain. In cases 1 and 2, an instant decrease in pain occurred following the first treatment. In case 3, the headache score decreased after the second treatment. In cases 1, 2 and 3, the headache score decreased from 4 to 1, 3 to 0, and 3 to 1, respectively.

In all 3 cases, the VAS score started decreasing after the first treatment. The VAS score includes not only head pain, but also neck pain. Therefore, there were some differences in the VAS and headache scores. In case 3, after the first treatment, the headache score remained the same but the VAS score decreased from 5.3 to 4.5. The VAS score decreased from 8.5 to 1.9 in case 1, from 5 to 0.4 in case 2, and from 5.3 to 2 in case 3. In all three cases, the VAS score decreased gradually during treatment. Furthermore, all cases showed a decrease in the NDI score. Therefore, it is meaningful that the pain was significantly reduced following MA treatments. In addition, the improved symptoms persisted for more than four weeks. All three cases showed decreased scores in the VAS and headache scores at follow up. Further, all cases except case 2 showed a decrease in the NDI score at follow up. No adverse events occurred in any of the cases. From these results, we speculate that MA is effective and safe for the treatment of headache with neck pain. It can be assumed that these cases can be used as a reference for MA treatment for cervicogenic headache.

In the future, a comparative study with other treatment methods should be performed. Moreover, additional cases should be obtained to compare the therapeutic effects with those of Western medicine treatments.

## V. Acknowledgments

This study was supported by a grant of Compre-

hensive and Integrative Medicine R&D project through Comprehensive and Integrative Medicine Institute (CIMI), funded by the Ministry of Health & Welfare, Republic of Korea (Grant Number: 090-091-3000-3038-301-320-01).

## VI. References

1. Côté P, Cassidy JD, Carroll L. The saskatchewan health and back pain survey: The prevalence of neck pain and related disability in saskatchewan adults. *Spine*. 1998;23(15):1689-98.
2. White AR, Ernst E. A systematic review of randomized controlled trials of acupuncture for neck pain. *Rheumatology (Oxford)*. 1999;38(2):143-7.
3. Bogduk N, Govind J. Cervicogenic headache: An assessment of the evidence on clinical diagnosis, invasive tests, and treatment. *Lancet Neurol*. 2009;8(10):959-68.
4. Sjaastad O, Fredriksen T, Pfaffenrath V. Cervicogenic headache: Diagnostic criteria. *Headache*. 1998;38(6):442-5.
5. Haldeman S, Dagenais S. Cervicogenic headaches: A critical review. *The Spine Journal*. 2001;1(1):31-46.
6. Biondi DM. Cervicogenic headache: A review of diagnostic and treatment strategies. *J Am Osteopath Assoc*. 2005;105(4):16-22.
7. Jull G, Trott P, Potter H et al. A randomized controlled trial of exercise and manipulative therapy for cervicogenic headache. *Spine (Phila Pa 1976)*. 2002;27(17):1835-43.
8. Ma C, Wu S, Li G, Xiao X, Mai M, Yan T. Comparison of miniscalpel-needle release, acupuncture needling, and stretching exercise to trigger point in myofascial pain syndrome. *Clin J Pain*. 2010;26(3):251-7.
9. Kim S. Clinical characteristics of poor responders to acupotomy and safety pretreatment management. *The Acupunct*. 2008;25(4):117-25.

10. Pang J. *Acupotomology basis and clinic*. 1st ed. Futian District Caitian Road Haitian Publishing Building; Shenzhen Haitian Publishing House. 2006:153–8.
11. Vernon H, Mior S. The neck disability index: A study of reliability and validity. *J Manipulative Physiol Ther*. 1991;14(7):409–15.
12. Carlsson AM. Assessment of chronic pain. I. aspects of the reliability and validity of the visual analogue scale. *Pain*. 1983;16(1):87–101.
13. Revall S, Robinson J, Rosen M, Hogg M. The reliability of a linear analogue for evaluating pain. *Anaesthesia*. 1976;31(9):1191–8.
14. Gobel H, Edmeads J. Disorders of the skull and cervical spine. *The Headaches*, 2nd Ed. Philadelphia: Lippincott Williams & Wilkins. 2000:891–8.
15. Henry P, Dartigues J, Puymirat E, Peytour P, Lucas J. The association cervicalgia–headaches: An epidemiologic study. *Cephalalgia*. 1987;7(6): 189–90.
16. Maimaris C, Barnes M, Allen M. ‘Whiplash injuries’ of the neck: A retrospective study. *Injury*. 1988;19(6):393–6.
17. Balla JI. The late whiplash syndrome. *Aust N Z J Surg*. 1980;50(6):610–4.
18. Leone M, D’amico D, Grazi L, Attanasio A, Bussone G. Cervicogenic headache: A critical review of the current diagnostic criteria. *Pain*. 1998;78(1):1–5.
19. Fernández-de-las-Penas C, Ge H, Alonso-Blanco C, González-Iglesias J, Arendt-Nielsen L. Referred pain areas of active myofascial trigger points in head, neck, and shoulder muscles, in chronic tension type headache. *J Bodywork Movement Ther*. 2010;14(4):391–6.
20. Giamberardino MA, Affaitati G, Fabrizio A, Costantini R. Myofascial pain syndromes and their evaluation. *Best Practice & Research Clinical Rheumatology*. 2011;25(2):185–98.