

Three cases meniscus injury treated with Shinbaro pharmacopuncture therapy

So Jin Lee^{1,*}, Tae Kyung Yoon¹, Soo Ji Shin², Sang Min Ahn³, Seong Jin Lee⁴,
Jeong Yoon Won⁵ and Yeo Jin Jang⁶

¹Department of Acupuncture and Moxibustion Medicine, Jaseng Hospital of Korean Medicine

²Department of Korean Medicine Obstetrics & Gynecology Medicine, Jaseng Hospital of Korean Medicine

³Department of Oriental Internal Medicine, Jaseng Hospital of Korean Medicine

⁴Department of Acupuncture and Moxibustion Medicine, Wonkwang University Hospital of Korean Medicine

⁵Department of Rehabilitation Medicine of Korean Medicine, Dongshin University Hospital of Korean Medicine, Seoul, Republic of Korea

⁶Department of Acupuncture and Moxibustion Medicine, Dongshin University Hospital of Korean Medicine



[Abstract]

Objectives : The purpose of this report was to show that oriental therapy, specifically Shinbaro pharmacopuncture is effective for improvement of symptoms and range of motion (ROM) in patients diagnosed with meniscus tears in the knee.

Methods : Three patients were treated with herbal medicine, acupuncture, cupping, Shinbaro pharmacopuncture. The efficacies of the treatments in the three cases were assessed and the progress of the three cases were measured Numerical Rating Scale (NRS), Western Ontario and McMaster Universities Osteoarthritis Index (WOMAC), European Quality of Life five dimensions dimensions (EQ-5D), and range of motion (ROM) measurements.

Results : After all the treatments, NRS, WOMAC, and EQ-5D decreased. Active and passive ROM of the knee increased.

Conclusion : These reports show the effect of Shinbaro pharmacopuncture on a meniscus tear. Due to the small number of cases in this study, further case reports are needed.

Key words :

Meniscus tear;
Shinbaro pharmacopuncture;
Numerical rating scale;
Range of motion

Received : 2017. 04. 28.
Revised : 2017. 05. 30.
Accepted : 2017. 06. 14.
On-line : 2017. 08. 20.

* Corresponding author : Dept. of Acupuncture and Moxibustion Medicine, Bucheon Jaseng Hospital, 17, Buil-ro 191 beon-gil, Wonmi-gu, Bucheon-si, Gyeonggi-do, 14598, Republic of Korea
Tel : +82-10-3006-3697 E-mail : superstarjoy@naver.com

I. Introduction

During the exercise, the knee joint undergoes stress in two different places. In the sagittal plane, it undergoes flexion and extension. In the horizontal plane, it experiences internal and external rotation¹⁾. The stability of the knee joints is controlled by the ligaments, joints, and surrounding muscles²⁾. Damage to the ligaments and cartilage is commonly seen as a result of a large functional demand imposed on the knee joints¹⁾.

The function of the meniscus is to reduce the load on the joint. It also contributes to joint stability, lubrication, and the reduction of friction during exercise. The inner meniscus and outer meniscus are fibrous cartilage discs located in the knee¹⁾. The medial meniscus (MM) is attached to the medial collateral ligament (MCL) and coronary ligament. The coronary ligament is 4–5 mm in length. The lateral meniscus is divided by the lateral collateral ligament (LCL) and popliteal tendon; the coronary ligament is 13–20 mm in length. The differences in these the coronary ligament is 13–20 mm in length. The differences in these structures is the reason why the medial meniscus is more likely to rupture³⁾. The medial meniscus tends to be damaged by twisting forces²⁾. If meniscus tear occurs, immediate and acute pain occurs, and all activities are stopped⁴⁾.

In the past, meniscus tear surgery was considered as the first option for such cases. However, the meniscus was recently found to be crucial for maintaining knee function. Therefore, it is important to preserve as much of the meniscus as possible⁵⁾.

Shinbaro pharmacopuncture consists of *Acanthopanax Cortex*, *Achyranthis Radix*, *Saposhnikoviae Radix*, *Cibotii Rhizoma*, *Glycine Semen Germinatum*, *Eucommiae Cortex*. Shinbaro pharmacopuncture uses an extract that is especially effective for anti-inflammation⁶⁾ and nerve regeneration⁷⁾. It is also effective for cartilage protection in degenerative arthritis⁸⁾. There are case reports showing

Shinbaro pharmacopuncture was as effective as bee-venom pharmacopuncture for a herniated lumbar intervertebral disc, but without the side effects⁹⁾.

There are some reports describing Korean medicine therapy for meniscus tears^{10–13)}. However, there are few reports of the use of Shinbaro pharmacopuncture for meniscus tears. We observed the outstanding therapeutic effects of Korean medicine in 3 patients who were treated at Bucheon Jaseng Korean medicine hospital for meniscus injuries therefore, we present these 3 case reports.

II. Treatment and evaluation methods

1. Treatment methods.

1) Pharmacopuncture therapy

Shinbaro pharmacopuncture was performed at Jaseng Wonoe Tangjunwon, Namyangju, Korea. Using a disposable insulin syringe, 1.0 cc of Shinbaro was injected at Hyeolhae (血海, SP10), Eumsi (陰市, ST33), Yanggu (梁丘, ST34), and Dokbi (犢鼻, ST35). The needle depth was 0.5 mm. This was performed twice a day.

2) Acupuncture treatment.

The needles were disposable stainless steel needles 0.25 mm in diameter and 30 mm in length (The Eastern acupuncture equipment manufacturer, Boryung, Korea). The needles were inserted at Hyeolhae (血海, SP10), Wijung (委中, BL40), Eumsi (陰市, ST33), Yanggu (梁丘, ST34), Dokbi (犢鼻, ST35), and Eumgok (陰谷, KI10) for 15 minutes twice a day.

3) Cupping

The cups were sterilized and disposable. Cupping was performed for 4 minutes, twice a day at 血海 (SP10), 梁丘 (ST34), and 陰谷 (KI10).

Table 1. Prescription of Herbal Medicines

Prescription	Composition of medicinal herbs
Mabalgwanjeol Decoction (馬勃關節湯)	<i>Lasiosphaera Seu Calvatia</i> 12g, <i>Achyranthis Radix</i> 8g, <i>Ginseng Radix</i> 8g, <i>Glycyrrhizae Radix</i> 4g, <i>Osterici Radix</i> 4g, <i>Testudinis Plastrum</i> 4g, <i>Angelicae Pubescentis Radix</i> 4g, <i>Hordei Fructus Germinatus</i> 4g, <i>Saposhnikoviae Radix</i> 4g, <i>Amomi Fructus</i> 4g, <i>Astragali Radix</i> 4g, <i>Aconiti Tuber</i> 2.8g
Cheongpajeonsinbang2 Decoction (靑波煎新方2號)	<i>Chelidonium majus</i> Linne var. <i>asiaticum</i> Ohwi, <i>Achyranthes japonica</i> Nakai, <i>Chaenomeles sinensis</i> Koehne, <i>Acanthopanax Cortex</i> , <i>Corydalis Tuber</i> , <i>Osterici Radix</i> , <i>Atractylodis Rhizoma</i> , <i>Angelicae Gigantis Radix</i> , <i>Rehmanniae Radix</i> , <i>Paeoniae Radix Rubra</i> , <i>Clematidis Radix</i> , <i>Araliae Continentalis Radix</i> , <i>Citri Unshii Pericarpium</i> , <i>Carthami Flos</i> , <i>Amomi Fructus</i> , <i>Glycyrrhizae Radix et Rhizoma</i> , <i>Zingiberis Rhizoma Crudus</i> , <i>Zizyphi Fructus</i>
Keoseuphwalhyoljitong Decoction (祛濕活血止痛湯)	<i>Lonicerae Flos</i> 8g, <i>Akebiae Caulis</i> 8g, <i>Coicis Semen</i> 8g, <i>Atractylodis Rhizoma</i> 8g, <i>Cinnamomi Ramulus</i> 4g, <i>Dianthi Herba</i> 4g, <i>Angelicae Gigantis Radix</i> 4g, <i>Persicae Semen</i> 4g, <i>Saposhnikoviae Radix</i> 4g, <i>Angelicae Dahuricae Radix</i> 4g, <i>Rehmanniae Radix Crudus</i> 4g, <i>Linderae Radix</i> 4g, <i>Achyranthis Radix</i> 4g, <i>Clematidis Radix</i> 4g, <i>Hoelen</i> 4g, <i>Paeoniae Radix</i> 4g, <i>Citri Unshii Pericarpium</i> 4g, <i>Cnidii Rhizoma</i> 4g, <i>Gentianae scabrae Radix</i> 4g, <i>Polygoni Avicularis Herba</i> 4g, <i>Caesalpiniae Lignum</i> 2g, <i>Carthami Flos</i> 2g

4) Herbal medicine treatment

Mabalgwanjeol decoction (馬勃關節湯) was pre-scribed for case 1, cheongpajeonsinbang 2 decoction (靑波煎新方2號) for case 2, and keoseuphwalhyoljitong decoction (祛濕活血止痛湯) for case 3. The patients took the medicine 3 times a day (3 packets 3 times a day)(Table 1).

5) Physiotherapy

All cases underwent interferential current therapy (I.C.T) once a day and received hot compresses with medicinal herbs over the painful knee for 20 minutes once a day.

2. Methods of Evaluation

1) Numerical Rating Scale (NRS)

The NRS is an instrument for measuring the subjective level of pain and is good for evaluating the degree of pain. The patient subjectively assesses their degree of pain from 0 to 10¹⁴⁾. This assessment was performed twice; once on the first day of hospitalization and again on the last day of hospitalization.

2) Western Ontario and McMaster Universities Osteoarthritis Index (WOMAC)

Western Ontario and McMaster Universities Osteoarthritis Index (WOMAC) is a new elective health status instrument for patients with osteoarthritis. It is composed of 24 questions about pain, stiffness, and physical function¹⁵⁾. This assessment was performed twice, once on the first day of hospitalization and again on the last day of hospitalization.

3) European quality of life 5 dimension (EQ-5D)

The EQ-5D is an instrument for describing and evaluating that status of one's health. It defines health status using the following 5 dimensions: Mobility, Self-Care, Usual Activities, Pain/Discomfort, and Anxiety/Depression¹⁵⁾. EQ-5D was evaluated twice, once on the first day of hospitalization and again on the last day of hospitalization.

4) Range of motion (ROM) and special tests

Active and passive range of motion (ROM) for flexion, extension, and other special tests of the knee were performed at 7:00 am every day. However it was not assessed when the pain was severe.

III. Cases

1. Case 1

1) Patient

Yim ○ ○; Female, 61 years old

2) Chief complaint

Left knee pain.

3) Date of onset

End of November 2016

4) Past medical history

Hypertension and hepatitis B.

5) Present illness

Left knee pain developed while practicing yoga at the end of November 2016. Meniscus tear was diagnosed using radiographic image, and the results from magnetic resonance imaging (MRI) performed at a local clinic. The patient was prescribed medicine and received physical therapy.

6) General condition

- (1) Sleep pattern: Slept well without pain
- (2) Diet: Normal appetite (one bowl of rice per meal). Occasionally, the patient experienced gas in the bowels
- (3) Urination: Favorable
- (4) Bowel movements: Once a day with loose stools
- (5) Thirst: Usually drank a less than the average amount of warm water
- (6) Sweating: Usually had less sweat than average
- (7) Tongue assessment: Red tongue
- (8) Radial pulse assessment: Relaxed pulse (緩脈)

7) Duration of treatment

February 9, 2017 to February 23, 2017 (15 days of hospitalization)

8) Radiology

(Fig. 1)

Results of the knee MRI (02/09/2017)

MM: transverse mild tear of the posterior horn

MCL: Partial tear and sprain of the proximal portion.

Anterior cruciate ligament (ACL), posterior cruciate ligament (PCL), LCL, lateral meniscus: Not remarkable.

A small fluid collection was seen in the suprapatellar bursa, knee joint, and posterior recess of the distal femur and proximal tibia.

Conclusions:

- (1) MM: transverse mild tear of the posterior horn.
- (2) MCL: Partial tear and sprain of the proximal portion.

9) Progress after treatments

- (1) Change in the NRS (Table 2)
- (2) Change in the WOMAC (Table 2)
- (3) Change in the EQ-5D (Table 3)
- (4) Change in the ROM and results from special tests (Table 4)

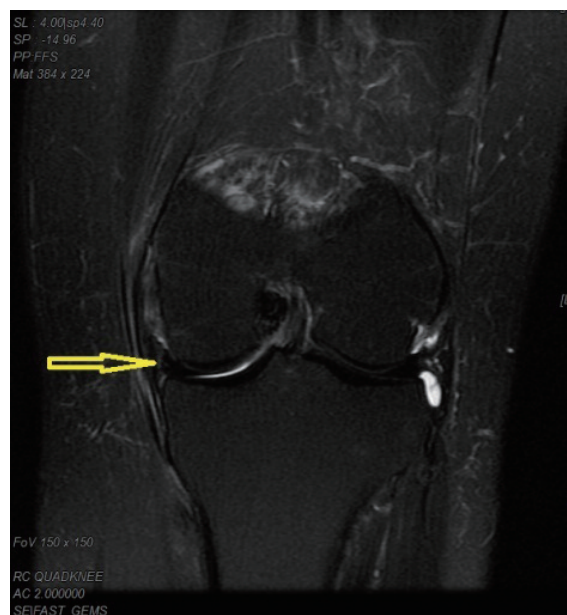


Fig. 1. Left knee MRI from case 1 (2/9/2017)

Table 2. Change in the Numerical Rating Scale(NRS) and Western Ontario and McMaster Universities Osteoarthritis Index (WOMAC)

	Admission day	Discharge day
NRS of case 1	7	3
NRS of case 2	7	2
NRS of case 3	7	3
WOMAC of case 1	75	21
WOMAC of case 2	72	11
WOMAC of case 3	73	16

2. Case 2

1) Patient

Joe OO, Female, 58 years old

2) Chief complaint

Right knee pain.

3) Date of onset

Middle of June 2016

4) Past medical history

Hypertension.

5) Present illness

Right knee pain developed in the middle of June 2016 for no specific reason. The patient was initially only prescribed medicine by the local clinic. She had a radiograph taken and was not diagnosed with any particular disease. She took the medicine and received physical therapy.

6) General condition

- (1) Sleep pattern: Awoken by pain once a day
- (2) Diet: normal appetite (one bowl of rice per meal)
- (3) Urination: favorable

Table 3. Change in the European Quality of Life–5Dimensions (EQ–5D)

EQ–5D	Admission day	Discharge day
Mobility	case 1,2,3: severe	case 1, 2, 3: slight problems case 1, 2: slight problems
Self-care	case 1,2,3: severe	case 3: no problem
Usual activities	case 1,2,3: severe	case 1, 2, 3: slight problems
Pain/Discomfort	case 1,2,3: severe	case 1, 2, 3: no problem
Anxiety/Depression	case 1,2,3: severe	case 1, 2, 3: no problem

Table 4. Change in the ROM and results from special tests

	Admission day	after 7 days	Discharge day
active flexion	100	110	130
passive flexion	110	115	120
active extension	–10	–5	0
passive extension	–5	0	0
Apley compression test	UC*	+	–
Apley distraction test	UC*	UC*	–
McMurray test	UC*	+	–
Valgus stress test	UC*	–	–
Varus stress test	UC*	–	–
Drawer's sign	UC*	UC*	–

*UC: Uncheckable.

- (4) Bowel movements: Once a day, normal stools
- (5) Thirst: Usually drank more than the average amount of cold water
- (6) Sweating: Usually had a little more than the average amount of sweat
- (7) Tongue assessment: Red tongue
- (8) Radial pulse assessment: Relaxed pulse (緩脈)

7) Duration of treatment

December 26, 2016 to February 11, 2016
(48 days of hospitalization)

8) Radiology

(Fig. 2)

Results of the right knee MRI (12/26/2016):

MM: Degenerative tear of anterior horn with a perimeniscal cyst.

Degenerative transverse tear of the posterior horn.

ACL,PCL,MCL,LCL, lateral meniscus: Not remarkable.

Medial condyle of the distal femur: Chondroma-

lacia grade 2.

Small amount of fluid collection in the suprapatellar bursa, knee joint, and posterior recess of the distal femur and proximal tibia.

Focal subchondral bone erosion in the lateral tibial plateau and proximal tibia.

Conclusion:

- (1) MM: Degenerative tear of the anterior horn with a perimeniscal cyst with a degenerative transverse tear of the posterior horn.
- (2) Mild degenerative arthritis in the medial compartment of the right knee joint.

9) Progress after treatments

- (1) Change in the NRS (Table 2)
- (2) Change in the WOMAC (Table 2)
- (3) Change in the EQ-5D (Table 3)
- (4) Change in the ROM and results from special tests (Table 5)

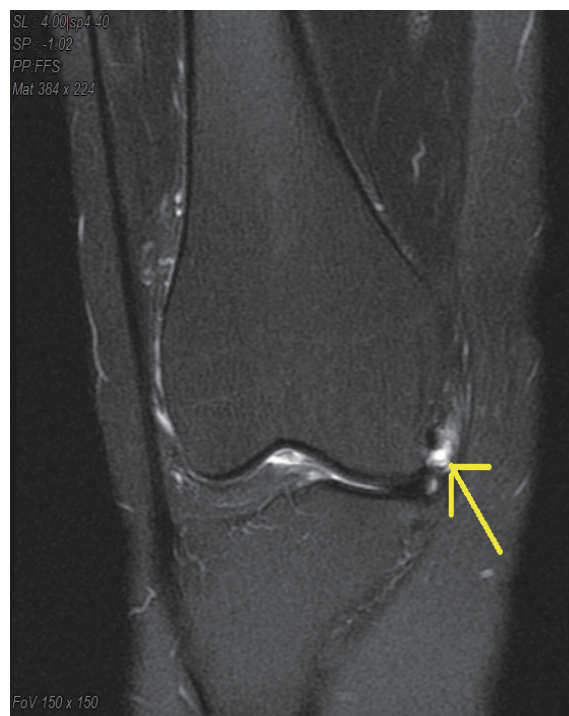
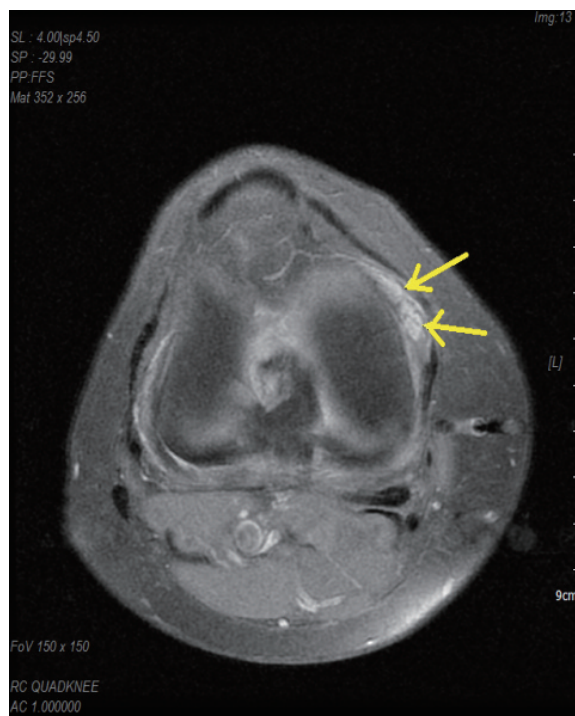
Fig. 2. Right knee MRI of case 2 (12/26/2016)

Table 5. Change in the ROM and results from special tests

	Admission day	after 16 days	after 32 days	Discharge day
active flexion	110	115	120	135
passive flexion	115	120	125	135
active extension	-20	-20	-10	0
passive extension	-10	-10	-5	0
Apley compression test	UC*	+	+	-
Apley distraction test	UC*	-	-	-
Mcmurray test	UC*	+	+	-
Valgus stress test	UC*	-	-	-
Varus stress test	UC*	-	-	-
Drawer's sign	UC*	-	-	-

*UC: Uncheckable.

3. Case 3

1) Patient

Kang O O, Male 52 years old

2) Chief complaint

Left knee pain

3) Date of onset

End of October, 2016

4) Past Medical History

Hyperlipidemia, hypertension and diabetes.

5) Present Illness

Left knee pain developed at the end of the October 2016 for no specific reason. The patient had a radiograph taken and was diagnosed with no specific disease. The patient only received injection therapy at the clinic.

6) General condition

- (1) Sleep pattern: Light sleep because of pain.
- (2) Dietary state: Less appetite (half bowl of rice per meal).
- (3) Urination: Favorable
- (4) Bowel movements: Once a day, normal stools.
- (5) Thirst: Usually drinking a less than average amount of warm water

(6) Sweating: Hardly any sweating during the day.

(7) Tongue assessment: Red tongue

(8) Radial pulse assessment: Relaxed pulse (緩脈)

7) Duration of treatment

December 24 2016 to January 4, 2017 (12 days)

8) Radiology

(Fig. 3)

Lt Knee MRI (2016/12/24)

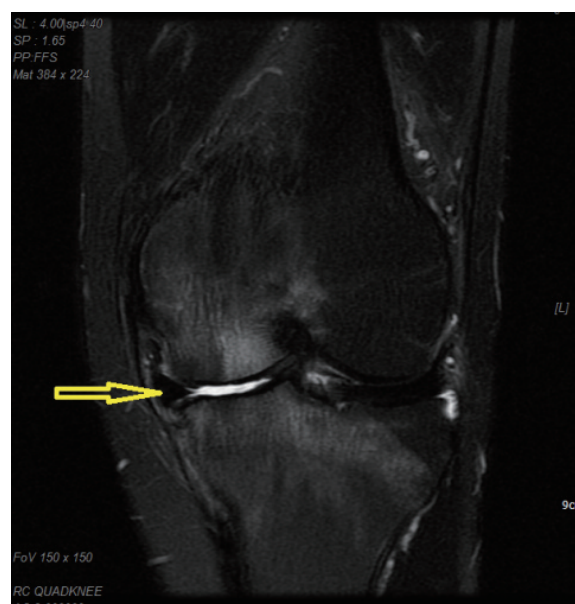


Fig. 3. Left knee MRI of case 3 (12/24/2016)

MM: Degenerative wear and tear of the posterior horn with extrusion

ACL,PCL,MCL,LCL, and lateral meniscus: Unremarkable.

Trochlear groove of the distal femur: Multifocal chondral defect and subchondral bone erosion and chondromalacia grade 3.

Inner facet of the patella: chondromalacia grade 2 and subchondral bone erosion.

Medial condyle of the distal femur: Diffuse chondral defect, chondromalacia grade 3, subchondral bone erosion, and diffuse bone marrow edema.

Medial tibia plateau: Chondromalacia and diffuse bone marrow edema.

Moderate amount of fluid collection in the suprapatellar bursa, knee joint, and posterior recess of the distal femur and proximal tibia.

Diffuse bone marrow edema in the intercondylar notch area and proximal tibia.

Tendinosis of the distal semimembranous tendon, and popliteal fossa (medial aspect).

Conclusion

- (1) Severe degenerative arthritis in the medial compartment and left knee joint.
- (2) Degenerative wear and tear of the posterior horn and extrusion status of the MM.
- (3) Degenerative arthritis in the patellofemoral

knee joint.

9) Progress after treatments

- (1) Change in the NRS (Table 2)
- (2) Change in the WOMAC (Table 2)
- (3) Change in the EQ-5D (Table 3)
- (4) Change in the ROM and results from special tests (Table 6)

IV. Discussion

The knee is the largest joint in the human body. The muscles surrounding the knee are large and strong. The ligaments have complex forms that maintain the stability of the joint¹⁶⁾. Knee perform crucial biomechanical functions during walking and running. The stability of knees is achieved mainly by the cartilage rather than the structural arrangement of the bone. Damage to the ligaments and cartilage is commonly seen as a result of large functional demands imposed on the knees¹⁾.

The meniscus is fibrous cartilage that distributes stress between the femur and tibia¹⁷⁾. It is also very important safety devices on knee because they helps reconcile and guide your knees. The shape of the meniscus resembles a half-moon with a trian-

Table 6. Change in the ROM and results from special tests

	Admission day	after 7 days	Discharge day
active flexion	100	115	135
passive flexion	105	120	135
active extension	-10	-10	0
passive extension	-5	-5	0
Apley compression test	UC*	+	+
Apley distraction test	UC*	-	-
Mcmurray test	UC*	+	-
Valgus stress test	UC*	-	-
Varus stress test	UC*	-	-
Drawer's sign	UC*	-	-

*UC: Uncheckable.

gular cross-section. The upper and lower sides are close to the femur and tibia³. Damage to the meniscus can also be accompanied by a single burst or ligament damage. Ruptures in the meniscus cause the mechanism of the knee to malfunction, contributing to degenerative arthritis¹⁷. A small tear in the meniscus can also cause instability; therefore, knee surgery will often negatively affect future knee stability, even if it is performed for therapeutic purposes. Since the most common complication of surgery is degenerative arthritis, conservative and non-invasive methods are preferred for the treatment of meniscus tears¹⁸.

In Korean medicine, the knee is referred to as “膝者筋之府，屈伸不能，行則僂附，筋將憊矣” which means the knee is where the muscles gather, and damage to the knee is seen as a sign of a dysfunctional liver¹⁹. Knee pain is expressed as 鶴膝風，歷節風，膝腫痛²⁰.

The extracts for Shinbaro pharmacopuncture are obtained by distillation. The extracts are used after filtration and freezing. They are sterilized at 121°C for 15 minutes²¹. These effects of these components include anti-inflammation, anti-arthritis, antioxidant activity, bone-regeneration, and pain reduction²². Shinbaro treatment on monosodium iodoacetate-induced osteoarthritis caused the trabecular bone to increase by approximately 40% and reduced the inflammation-inducing element, such as prostaglandin and anti-collagen antibody, by about 60% when compared to that of the control group²³.

Because conservative therapy for meniscus tears is important, a variety of treatments from oriental medicine are needed. There are reports of motion style treatment by Choi et al.¹⁰, the effects of bee venom pharmacopuncture by Kim et al.¹¹ and Lee et al.¹², the effects of treatment with general Korean medicine by Woo et al.¹³, and the effects of miniscalpel acupuncture therapy by Jung et al.⁵ However, there are few case reports about Shinbaro pharmacopuncture, so we decided to report the findings in these three cases.

Three patients were diagnosed with meniscus

tears and preferred conservative approach to treatment. Shinbaro pharmacopuncture was the main method of treatment. The extract was injected at Hyeolhae (血海, SP10), Eumsi (陰市, ST33), Yanggu (梁丘, ST34), Dokbi (犢鼻, ST35). Standards for the treatment of the knee by acupuncture have been implemented. Treatment with herbal medicine has been used to improve knee injuries. Within each case, the prescription was unchanged. In case 1, the patient complained of knee pain associated with a heaviness of the body and fatigue, so a Mabalgwanjeol decoction (馬勃關節湯) was administered. In case 2, the patient was administered a Cheongpajeonsinbang 2 decoction (靑波煎新方2號) because the chief complaint was acute pain during all types of movement. In case 3, a Keoseuphwalhyoljitong decoction (祛濕活血止痛湯) was administered, for a feeling of heaviness in the knee.

The NRS score decreased in all cases: from 7 to 3 in case 1, 7 to 2 in case 2, and 7 to 3 in case 3. The WOMAC also decreased in all cases: from 75 to 21 in case 1, 72 to 11 in case 2, and 73 to 16 in case 3. EQ-5D improved in all 3 cases. In case 1, the ROM during active flexion increased from 100 to 130, from 110 to 120 during passive flexion, and from -10 to 0 during active extension, and on the day of discharge, from -5 to 0 during passive extension ROM. Severe pain during the McMurray and Apley compression tests resolved. In case 2, after treatment was completed, the ROM changed from 110 to 135 during active flexion, from 115 to 135 during passive flexion, and from -20 to 0 during active extension, and from -1 to 0 during passive extension. During the McMurray and Apley compression tests, the response changed from positive to negative. In case 3, the ROM changed from 100 to 135 during active flexion, from 105 to 135 during passive flexion, and from -10 to 0 during active extension, and from -5 to 0 during passive extension.

All three reduced acute pain during routine motion. After the therapy, results from the special tests also improved. These cases show the strong effect of Shinbaro on tears of the meniscus. How-

ever, treatment with Shinbaro was coupled with acupuncture, herbal medicine, cupping, and physiotherapy. In addition, since there were only a small number of cases, the results cannot be generalized. Shinbaro pharmacopuncture has many effects on musculoskeletal disorders and cartilage disorders^{21,22}. Since conservative treatment for meniscus injuries is important, more case reports of treatment with Shinbaro pharmacopuncture or any other methods of Korean medicine for meniscus injuries are needed. Further reports describing a larger number of cases with objective evaluation methods for meniscus tear are necessary.

V. References

1. Donald AN. Kinesiology of the musculoskeletal system. Seoul: Jung-Dam Media. 2004:471-5, 479-80.
2. William EP, Michael IV. Techniques in musculoskeletal rehabilitation. Seoul: Koon ja Publisher. 2005:601-3.
3. Ludwig O, Pierre B, Herman JT. A system of Orthopaedic Medicine. Seoul: Hanmi medical publishing. 2008:1055-61
4. Rene C. Soft tissue pain and Disability. Seoul: Yeoung Mun publishing company. 2001:409-15
5. Lee JH, Park MS. Miniscalpel Acupuncture Therapy for a Patient with Traumatic Tears of both Menisci: A Case Report. *The Acupunct*. 2016;33(3):153-159
6. Lee SY, Kwon HK, Lee SM. Shinbaro, a New Herbal Medicine with Multifunctional Mechanism for Joint Disease: First Therapeutic Application for the Treatment of Osteoarthritis. *Arch Pharm Res*. 2011;34(11):1773-7.
7. Kim TH, Yoon SJ, Lee WC et al. Protective effect of GCSB-5, an herbal preparation, against peripheral nerve injury in rats. *J Ethnopharmacol*. 2011;136(2):297-304.
8. Kim WK, Chung HJ, Pyee Y et al. Effects of intra-articular Shinbaro treatment on monosodium iodoacetate-induced osteoarthritis in rats. *Chin Med*. 2016;11:17.
9. Park OJ, Kim SK, Lee JJ, Lee SM, KIM SJ, Cho NK. The Effect of Shinbaro and Bee Venom Pharmacopuncture in Treating Lumbar Disc Herniations. *The Acupunct*. 2013;30(5):41-50.
10. Choi YI, Kim MY, Choi HS, Shin DJ, Choo WJ. The clinical report on 2 cases of meniscal injury patients with knee pain improved by motion style treatment. *The Journal of Korea Chuna Manual Medicine for Spine & Nerves*. 2011;6(2):97-107.
11. Kim DE, Yu DS, Yeon SR, Kwon YD, Song YS. The effect of intra-articular bee venom injection on meniscal injury: four cases report. *Journal of Korean Medicine Rehabilitation*. 2010;20(1):219-30.
12. Lee JH, Kim JS, Jeong YH, Jeong B, Lee CR. A case report of intra-articular bee venom pharmacopuncture combining with oriental medical treatment for acute traumatic partial tear of meniscus. *Journal of Pharmacopuncture*. 2010;13(4):129-37.
13. Woo YH, Min KH. The Effect of Korean Medical Treatment on 4 Patients with Acute Traumatic Meniscal Tear. *The Acupunct*. 2015;32(2):197-20.
14. Ha IH, Park WS, Woo I, Kim HN, Kho DH, Yoon YS. Correlation between Horizontal Visual Analogue Scale, Vertical Visual Analogue Scale and Numerical Rating Scale for Pain Measurement. *Journal of Korean Medicine Rehabilitation*. 2006;16(4):125-33.
15. Johannes MG, David FH, Bernhard J, Henrik B, Karlmeirad G. WOMAC, EQ-5D and knee society score thresholds for treatment success after total knee arthroplasty. *J. Arthroplasty*. 2015;30:2154-8.
16. Jung JW. Musculoskeletal anatomy. Seoul: Dae-Hak-Seo-Lim. 2012:115-20.
17. John FS. Essentials of Musculoskeletal care.

- Seoul: Panmunmun Education, 2013:411-5.
18. Choi NH, Oh JS. Management of meniscal injury: repair, meniscectomy, and transplantation. J. Korean Orthop Assoc. 2012;47(3):165-70.
19. Jin JP. Hwangjenaeyeong SoMunDokSongBon. Seoul: Beob-In Mun-Hwa-Sa, 2009:108.
20. Korean Acupuncture & Moxibustion Society Textbook Compilation Committee. The acupuncture and moxibustion medicine. Seoul: Jipmoondang. 2012:193, 549.
21. Lee JH, Kim MJ, Lee JW et al. A Study on Standardization of Shinbaro Pharmacopuncture Using Herbal Medicines Identification Test and HPLC-DAD. The Acupunct. 2015;32(2):1-9
22. Kim SH, Lee CH, Lee JS et al. Anti-Inflammatory Activities of a Herbal Preparation GCSB-5 on Acute and Chronic Inflammation. Korean Journal of Pharmacognosy. 2005;36(4):311-7.
23. Kim WK, Chung HJ, Pyee Y et al. Effects of intra-articular Shinbaro treatment on monosodium iodoacetate-induced osteoarthritis in rats. Chin Med. 2016;11:17.