

# A case report of a Phantom Limb Pain (PLP) patient treated with integrative Korean and Western medicine

Heun Ju Lee\*, Ji Young Baek and Chang Beohm Ahn

Dept. of Acupuncture & Moxibustion Medicine, Samse Korean Medical Hospital



---

## [Abstract]

**Objectives :** We report a case of Phantom Limb Pain (PLP) and propose the possibility of integrative Korean and Western medicine in PLP treatment.

**Methods :** For 42 days, a patient who complained of pain and insomnia with PLP (December 20, 2016 to January 20, 2017) received Korean and Western medical treatment. The patient was treated with analgesic injection, a neuropathic pain inhibitor, the combined herbal formula powders Bojungikgitang, and acupuncture. Symptom improvement was assessed using the numerical rating scale (NRS) and continuous sleep time.

**Results :** The patient's NRS scores decreased, and continuous sleep time increased after treatment. The NRS scores decreased from 10 to 0, and the continuous sleep time increased from 2 hours to 7 to 8 hours.

**Conclusion :** According to the results, this report suggests that integrative Korean and Western medicine could be effective in the treatment of PLP patients.

---

### Key words :

Phantom limb pain;  
Acupuncture;  
Integrative Korean  
and Western medicine

Received : 2017. 04. 12.

Revised : 2017. 07. 12.

Accepted : 2017. 07. 18.

On-line : 2017. 08. 20.

\* Corresponding author : Department of Acupuncture & Moxibustion Medicine, Samse Korean Medical Hospital, 1580 Jungangdaero, Geumjeong-gu, Busan, 46302, Republic of Korea  
Tel : +82-51-580-6956 E-mail : heunju0128@hanmail.net

## I. Introduction

Phantom limb pain (PLP) is characterized by painful sensations in the missing part of the amputated limb. Common causes of limb deficiency are vascular problems, trauma, cancer, and congenital limb loss<sup>1)</sup>. PLP can be associated with various clinical characteristics such as aching; cramping; burning; tingling; sharp, shooting, or stabbing pain; or mixed burning-tingling<sup>2,3)</sup>. About one week after amputation, 92% of patients reported phantom tingling. PLP appears in 65% of patients within the first 6 months following amputation<sup>3,4)</sup>. Treatment of PLP includes medications such as analgesics, anticonvulsants, antidepressants, muscle relaxants, anesthetics, transcutaneous electrical nerve stimulation (TENS), mirror therapy and acupuncture<sup>5-8)</sup>.

In Korea, there are few studies on PLP and there are even fewer studies regarding the use of integrative Korean and Western medicine in the treatment of PLP. In this paper, we report the results of using integrative Korean and Western medicine to treat a patient suffering from PLP after amputation surgery. The patient was admitted to Samse Oriental Hospital from December 10, 2016, to January 20, 2017.

## II. Case study

### 1. Patient

Jang OO, male, 51years

### 2. Chief complaints

Phantom pain  
Insomnia

### 3. Onset

Amputation below right knee on November 25, 2016

### 4. Family history

None

### 5. Social history

Smoking for 35 years, drinking daily

### 6. Patient history

The patient had a right ankle injury in 1991 and continued to have pain in his ankle, for which he took analgesics. In 2016, the pain in his lower leg increased, and he was admitted to Pusan University Hospital for angioplasty, incision of the vessel (embolectomy or thrombectomy) of the femoral artery superficial and popliteal artery. After discharge, he had severe pain, plantar necrosis and was re-admitted for amputation below the right knee on November 25, 2016.

### 7. Examinations

#### 1) Clinical chemistry

ALT 56 ↑, RBC 3520000 ↓, Hb 11.7 ↓, Hct 35 ↓

#### 2) Radiology

Chest post-anterior (PA): No active lung lesion (Fig. 1)

### 8. Treatments

#### 1) Acupuncture

Acupuncture treatment was performed twice a

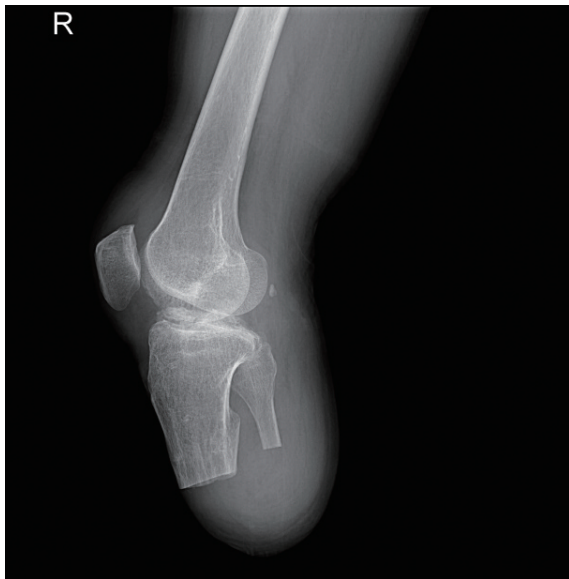

Fig. 1. Amputation below right knee X-ray

day (9:00 a.m. and 2:00 p.m.) during the patient's hospitalization and done using disposable stainless-steel needles 0.20mm in diameter and 30mm in length (Dongbang Acupuncture Inc., Korea) for 15 minutes. In the morning, acupuncture was applied at Sinjeongkyuk (腎正格), Hapmok (合谷, LI4) with no stimulation. In the afternoon, the patient was treated at ten acupoints on the unaffected side, Baekhoe (百會, GV20), Sasinchong (四神總, Ex-HN1), Sakwan (四關), Taebaek (太白, SP3), Joksamni (足三里, ST36), Sinmun (神門, HT7) with manual stimulation of rotation. The depth of needle insertion was 5~15 mm. Needle sensation including de-qi was not vigorously sought. The acupuncture treatment was performed by two Korean medical doctors with 8 years and 3 years of clinical experience.

Table 1. Mediation

Ingredients Label	Dose	Medication Purpose
Astrix BoRyung CAP. 100mg	1C QD(8A)	Antithrombotics
Plavix TAB. 75mg	1T QD(8A)	Antithrombotics
Crestor TAB. 10mg	1T QD(7P)	Antilipidemic agents
Nexium TAB. 20mg	1T QD(7A)	H+ pump inhibitors
Neurontin CAP. 100mg	1C TID	Neuropathic pain

CAP, C : capsule, TAB, T : tablet, QD : quaque die, BID : bis in die, TID: ter in die.  
A: ante meridiem, P: post meridiem.

## 2) Herbal medicine (2016.12.10–2017.01.20)

Bojungikgitang (補中益氣湯) powder insurance medicine (Mixed extract, JungWoo Medicines Co.) was prescribed from December 20, 2016 to January 20, 2017. One packet was taken 3 times a day after meals.

## 3) Moxibustion

Moxibustion was performed once a day around Jungwan (中腕, CV12) in the abdominal.

## 4) Western- medicine treatment

Western medicine was prescribed after the operation and taken daily (Table 1).

## 9. Assessment

We asked the patient about pain and sleep time in the morning before treatment. The measured value is the average value of the previous day.

### 1) Numerical rating scale (NRS)

The state of no pain at all was 0; the most severe pain was 10, and the intensity of the pain felt was reported by the patient himself<sup>9)</sup>.

### 2) Continuous Sleep Time

We measured the amount of time the patient slept continuously without waking with pain.

## 10. Result

### 1) Session 1. (12/10/2016 to 12/16/2016)

On the date of admission, the patient complained of phantom pain in his amputated foot, swelling in, and tingling. Since the PLP was severe at night, he was given an analgesic injection (Toraren INJ Myoungmoon Co.), but he woke every 2 hours. After 5 days of hospitalization, the patient could sleep without analgesic. The pain was NRS 10.

### 2) Session 2. (12/17/2016 to 12/23/2016)

Eight days after admission, the PLP reduced to NRS 3–4, so analgesic injections were not needed every day. After 10 days of hospitalization, the PLP in the amputated soles and feet decreased, but the pain increased due to recognition of the remaining portion of the amputated lower limb. On the 13th day of hospital admission, an analgesic patch (Durogesic D–trans Patch, 25  $\mu$ g/h) possessed by the patient's friend was obtained and attached arbitrarily. After 24 hours, the patch was removed immediately due to side effects it caused. After the patch was removed, an analgesic injection was administered because the PLP was more severe with the patch attached. The pain increased to NRS 7 and continuous sleep time decreased to 3 hours.

### 3) Session 3. (12/24/2016 to 12/30/2016)

The PLP was reduced on the 18th day of hospitalization, and the analgesic injection was not admin-

istered until discharge. During the hospitalization period, the analgesic injection was given five times. After 18 days of hospitalization, the PLP decreased to NRS 2–3. PLP decreased at night and appeared during the day

### 4) Session 4. (12/31/2016 to 01/06/2017)

After 25 days of hospitalization, there was almost no PLP. The NRS score was measured as 2; continuous sleep time was measured as 4–6 hours.

### 5) Session 5. (01/07/2017 to 01/13/2017)

After 33 days of hospitalization, the patient began wearing the prosthetic leg and walked using it. After the walking exercise, the PLP increased to NRS 5, and the patient slept for 3 consecutive hours. The pain increased, but the use of analgesics did not. After one day, the pain decreased to NRS 2, and continuous sleep time increased to 6 hours.

### 6) Session 6. (01/14/2017 to 01/20/2017)

After 36 days of hospitalization, PLP was NRS 0. Continuous sleep time increased up to 8 hours. After 40 days of hospitalization, the patient walked for 5 hours and the pain increased to NRS 3–4. The continuous sleep time decreased to 3.5 hours. The next day, after reducing exercise time, the intensity of pain and continuous sleep time measured the same as before exercise. The patient had no pain at discharge, but he was worried about the pain, so he was prescribed for 7 days (Table 2) (Fig. 2, 3).

**Table 2. Discharge Medication**

Ingredients Label	Dose	Medication Purpose
Anyrac TAB.	1T BID	Nonsteroidal anti inflammatory drugs
Kiase TAB.	1T TID	Digestants
K Peri TAB.	1T TID	Skeletal muscle relaxants
Levoron 25mg TAB.	1T TID	GI tract regulators

CAP, C : capsule, TAB, T : tablet, QD : quaque die, BID : bis in die, TID: ter in die.

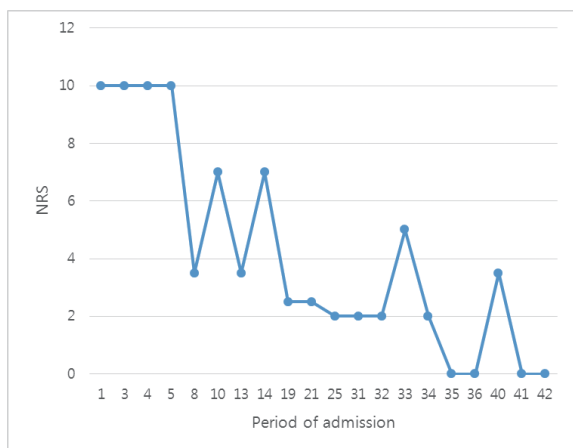


Fig. 2. Change in NRS after treatment during admission

### III. Discussion

Amputees may experience severe pain. In general, natural pain relief of PLP is prolonged and can take months, often years. The pain becomes chronic<sup>10,11</sup>. Approximately 59% of patients show a 5–10% reduction in pain intensity even 2 years after amputation<sup>12</sup>.

Although the mechanism of PLP is not fully understood, a recently reported possible cause is cortical reorganization<sup>1</sup>. The cortical areas representing the amputated limb involves an increased excitability of the corticospinal neurons and a reduction of GABA activity in the primary motor cortex<sup>1,13,14</sup>. Since PLP mechanism has not yet been clearly proven, there are various treatment methods, including medications, surgical procedures, and other adjuvant therapies.

Pharmacotherapy includes opioids, tramadol, tricyclic antidepressants, anticonvulsants, sodium channel blockers, NMDA receptor antagonist, ketamine<sup>1</sup>. The Neurontin capsule (Gabapentin) is effective in treating several syndromes of neuropathic pain, but some studies show no efficacy for this<sup>15,16</sup>.

Mirror therapy is a well-known treatment for PLP. Mirror therapy, through the senses of move-

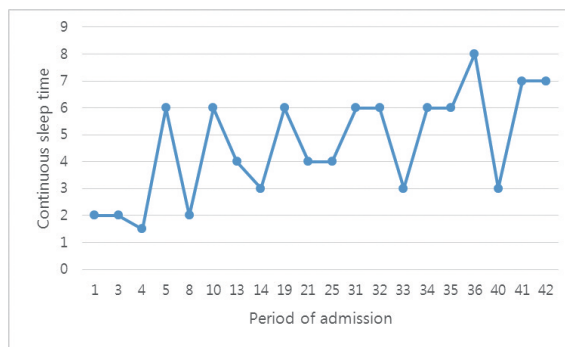


Fig. 3. Change in continuous sleep time after treatment during admission

ment and sight, is a neurorehabilitation treatment that induces somatosensory and motor pathway coupling between the phantom and real limb<sup>11,17</sup>. From the viewpoint of neurological pain treatment, acupuncture treatment uses sight, stimulation, etc. and increases cerebral blood circulation<sup>17,18</sup>. Acupuncture treatment is suggested to alter cortical mapping<sup>19</sup>.

In our case, we used the Gyozae (巨刺) acupuncture treatment method. In the basic theory of Oriental medicine, Naekyoung (內經), is a method of treating the right side for diseases on the left side, and the other way around<sup>20</sup>. Acupuncture treatment was performed twice a day at 9:00 a.m. and 2:00 p.m. except on Sunday. In the morning, Sinjeongkyuk (腎正格) and Hapgok (合谷, LI4) were used to strengthen the circulatory function in the lower limb. In the afternoon, Baekhoe (百會, GV20), Sasinchong (四神總, Ex-HN1), Sakwan (四關), Taebaek (太白, SP3), Joksamni (足三里, ST36), and Sinmun (神門, HT7) were performed to improve cerebral blood flow, improve systemic blood circulation and stabilize the heart. During the afternoon treatment, we explained to the patient that he was being treated by placing a needle on the opposite side of the PLP. These stimuli are considered important in phantom limb therapy<sup>20</sup>. The herbal medicine regimen included the insurance medicine *Bojungikgi-tang* powder due to the patient's low energy level after the surgery.

The patient received a pain killer injection at ses-

sion 1, but the pain persisted. The painkillers used at the hospital were weaker than the painkillers used at the previous hospital. As the duration of treatment increased, the pain decreased and sleep time increased without analgesic injection. In the present study, it is noteworthy that pain significantly decreased after 18 days of treatment and that the symptoms improved. After surgery, the patient's condition generally improved.

This case study was limited for various reasons. The case was insufficient, and there was no follow-up after discharge. Continuous sleep time must be based on the objective outcome measurements. In the future, larger-sample clinical trials are needed to confirm the effectiveness of integrative Korean and Western medicine for PLP.

#### IV. Reference

1. Subedi B., Grossberg G. T. Phantom limb pain: mechanisms and treatment approaches. *Pain Res Treat*. 2011;2011:864605.
2. Ehde Dawn M., Czerniecki Joseph M., Smith Douglas G. et al. Chronic phantom sensations, phantom pain, residual limb pain, and other regional pain after lower limb amputation. *Archives of Physical Medicine and Rehabilitation*. 2000;81(8):1039-44.
3. Jensen T. S., Krebs B., Nielsen J., Rasmussen P. Phantom limb, phantom pain and stump pain in amputees during the first 6 months following limb amputation. *Pain*. 1983;17(3):243-56.
4. Richardson C., Glenn S., Nurmikko T., Horgan M. Incidence of phantom phenomena including phantom limb pain 6 months after major lower limb amputation in patients with peripheral vascular disease. *Clin J Pain*. 2006;22(4):353-8.
5. Yildirim M., Kanan N. The effect of mirror therapy on the management of phantom limb pain. *Agri*. 2016;28(3):127-34.
6. Flor H. Maladaptive plasticity, memory for pain and phantom limb pain: review and suggestions for new therapies. *Expert Rev Neurother*. 2008;8(5):809-18.
7. Casale R., Alaa L., Mallick M., Ring H. Phantom limb related phenomena and their rehabilitation after lower limb amputation. *Eur J Phys Rehabil Med*. 2009;45(4):559-66.
8. Nikolajsen L., Jensen T. S. Phantom limb pain. *Br J Anaesth*. 2001;87(1):107-16.
9. Von Korff M., Jensen M. P., Karoly P. Assessing global pain severity by self-report in clinical and health services research. *Spine (Phila Pa 1976)*. 2000;25(24):3140-51.
10. MacLachlan M., McDonald D., Waloch J. Mirror treatment of lower limb phantom pain: a case study. *Disabil Rehabil*. 2004;26(14-15):901-4.
11. Hasanzadeh Kiabi F., Habibi M. R., Soleimani A., Emami Zeydi A. Mirror therapy as an alternative treatment for phantom limb pain: a short literature review. *Korean J Pain* 2013;26(3):309-11.
12. Pinto C. B., Saleh Velez F. G., Bolognini N., Crandell D., Merabet L. B., Fregni F. Optimizing Rehabilitation for Phantom Limb Pain Using Mirror Therapy and Transcranial Direct Current Stimulation: A Randomized, Double-Blind Clinical Trial Study Protocol. *JMIR Res Protoc*. 2016;5(3):e138.
13. Bolognini N., Olgiati E., Maravita A., Ferraro F., Fregni F. Motor and parietal cortex stimulation for phantom limb pain and sensations. *Pain*. 2013;154(8):1274-80.
14. Chen R., Corwell B., Yaseen Z., Hallett M., Cohen L. G. Mechanisms of cortical reorganization in lower-limb amputees. *J Neurosci*. 1998;18(9):3443-50.
15. Smith Douglas G., Ehde Dawn M., Hanley Marisol A. et al. Efficacy of gabapentin in treating chronic phantom limb and residual limb pain. *The Journal of Rehabilitation Research and Development*. 2005;42(5):645.
16. Nikolajsen L., Finnerup N. B., Kramp S., Vimtrup A. S., Keller J., Jensen T. S. A ran-

- domized study of the effects of gabapentin on postamputation pain. *Anesthesiology*. 2006; 105(5):1008–15.
17. Lee I. S., Jung W. M., Lee Y. S., Wallraven C., Chae Y. Brain responses to acupuncture stimulation in the prosthetic hand of an amputee patient. *Acupunct Med*. 2015;33(5):420–4.
  18. Sang KM, Young SK. The effect of LI4-LI11 electrical acupuncture at unaffected limb on cerebral blood flow in ischemic stroke patients using SPECT. *The Acupunct*. 2004;21(1):111–8.
  19. Campbell A. Seeing the body: a new mechanism for acupuncture analgesia? *Acupunct Med*. 2013;31(3):315–8.
  20. Committee Korean Acupuncture Society Textbook Compilation. *Acupuncture & Moxibution Medicine*. Gyeonggi: Jipmoondang. 2012:128.
  21. Wilcher D. G., Chernev I., Yan K. Combined mirror visual and auditory feedback therapy for upper limb phantom pain: a case report. *J Med Case Rep*. 2011;5:41.