

Miniscalpel acupuncture points of the cervical region: A review[※]

Ju-ran Kim¹, Jung Hee Lee¹, Han Mi Gong¹, Seungah Jun¹, Yeon-Joong Chung¹,
Chung A Park², Seong Hun Choi³, Geon-Mok Lee⁴, Hyun-Jong Lee¹ and Jae Soo Kim^{1*}

¹Department of Acupuncture & Moxibustion medicine, College of Korean medicine, Daegu Haany University

²Department of Diagnostics, College of Korean medicine, Daegu Haany University

³Department of Anatomy and Histology, College of Korean medicine, Daegu Haany University

⁴LeeGeonmok Wonli Korean Medicine Hospital



[Abstract]

Objectives : We conducted a literature search to identify trends with respect to miniscalpel acupuncture points (MAPs) of the cervical region with the aim of providing guidance regarding miniscalpel acupuncture (MA) in the cervical region.

Methods : We searched 2 overseas sites (PubMed and Google Scholar) and 5 domestic sites (NDSL, RISS, KISS, OASIS and Korean Traditional Knowledge Portal) for clinical trials of MA of the cervical region. The search terms used were “acupotomy or miniscalpel acupuncture or miniscalpel” and “cervical.” Of 73 studies found, 11 were included in this review, 6 of which presented exact MAPs. Owing to the lack of data, we refer to 1 Korean and 4 Chinese articles to analyze the exact location and meaning of the MAPs used in the published studies and to propose other clinically applicable MAPs.

Results : We identified 10 of the most commonly used MAPs in the published studies, including those located below the external occipital protuberance, 2–2.5 cm both side down of the external occipital protuberance, 4.5–5 cm both side down of the external occipital protuberance and C3–7 spinous process. Furthermore, we proposed 13 additional MAPs that can be used clinically.

Conclusion : We hope that this study will form a basis for the development of MA and hope to improve the safety and reproducibility in future MA studies of the cervical region.

Key words :

Miniscalpel acupuncture points;
Neck pain;
Miniscalpel acupuncture;
Acupotomy;
Acupoint

Received : 2017. 07. 25.

Revised : 2017. 07. 28.

Accepted : 2017. 08. 01.

On-line : 2017. 08. 20.

※ This study was supported by a grant of Comprehensive and Integrative Medicine R&D project through Comprehensive and Integrative Medicine Institute (CIMI), funded by the Ministry of Health & Welfare, Republic of Korea (Grant Number: 090–091–3000–3038–301–320–01).

* Corresponding author : Department of Acupuncture & Moxibustion medicine, Daegu Oriental hospital of Daegu Haany University, 136, Sincheondong-ro, Suseong-gu, Daegu, 706–828, Republic of Korea

Tel : +82–53–770–2108 E-mail : jaice@daum.net

© This is an Open-Access article distributed under the terms of the Creative Commons Attribution Non-Commercial License (<http://creativecommons.org/licenses/by-nc/3.0>) which permits unrestricted non-commercial use, distribution, and reproduction in any medium, provided the original work is properly cited.

The Acupuncture is the Journal of Korean Acupuncture & Moxibustion Medicine Society. (<http://www.TheAcupuncture.org>)

Copyright © 2017 KAMMS. Korean Acupuncture & Moxibustion Medicine Society. All rights reserved.

I. Introduction

A normal cervical spine is shaped like a wide letter “C” with its curve facing toward the front, but since posture in daily life is almost always in the erect position, the cervical spine is heavily weighted and sustains heavy mechanical wear. In addition, since the cervical spine has the highest range of motion in the spine, degenerative changes are more likely to occur as age increases, and the cervical spine is more likely to be easily damaged by mild trauma¹⁾.

Miniscalpel acupuncture (MA) is a new theory by Zhu Hanzhang (朱汉章) of China in 1976. MA is a combination of the Bijeuung (痺證) theory in Chinese medicine and surgery to treat chronic soft tissue injured disease. The Bijeuung (痺證) theory is about the pain, numbness, and movement disorders caused by disharmony of qi and blood. MA treats chronic pain diseases by releasing the synechia, adhesion, and scars of soft tissues and is used for a variety of diseases including musculoskeletal diseases²⁾. Particularly, it is one of the most remarkable treatments for cervical spinal diseases because of its effectiveness, ease of administration, low cost, and less lower risk of infection compared with open surgery³⁾.

There are several studies regarding cautions in MA procedures, such as side effects, risk prevention, and infection control^{4,5)}. In addition, a review of trends of MA in musculoskeletal disorders, such as peroneal nerve palsy, obesity and so forth, has been published⁶⁾. Among the musculoskeletal diseases, MA is more often used for ‘lumbar spinal diseases’ such as lumbar spinal stenosis and lumbar disc herniation^{7,8)}. Jun et al.⁹⁾ reviewed the use of MA for lumbar disc herniation in China. In the lumbar region, therefore, miniscalpel acupuncture points (MAPs) and MA procedures are being actively studied.

MA is used for various diseases. However, major structures such as spinal cord, blood vessels, and nerves are located in the cervical region and thus

are more likely to be injured¹⁰⁾, there is a lack of research on the MAPs, safety, and efficacy of the cervical region.

Therefore, we analyzed the use of MA in the cervical region in both domestic and foreign studies. Subsequently, since there was an insufficient number of papers for analysis, we also referred to 1 Korean and 4 Chinese publications including a book by Zhu Hanzhang (朱汉章), who is the creator of MA. The purpose of this review was to analyze the exact location and meaning of each MAP and to propose other clinically applicable MAPs of the cervical region^{2,3,10,11,12)}.

II. Methods

1. Study analysis

We searched PubMed and Google Scholar for overseas studies including MA of the cervical region. For domestic studies, we searched the National Discovery for Science Leaders (NSDL), the Research Information Sharing Service (RISS), the Korean Studies Information Service System (KISS), the Korean Traditional Knowledge Portal, and the Oriental Medicine Advanced Searching Integrated System (OASIS).

The search terms used were “acupotomy or miniscalpel acupuncture or miniscalpel” and “cervical. There was no limitation with respect to the year of publication. Only human, not animal, studies were collected. We excluded studies that had only an abstract and studies for which we were unable to obtain the full text. Studies that were not case reports or case series and those in which treatment included other regions besides the cervical region were also excluded. As a result, 6 domestic studies and 5 overseas studies were identified and included in our analysis (Fig. 1).

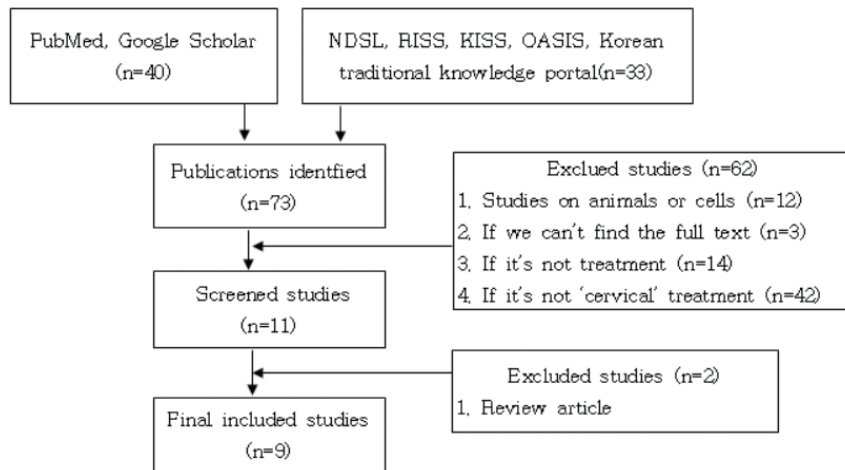


Fig. 1. Flow chart of searching strategy

Abbreviations: NDSL, National Discovery for Science Leaders; RISS, Research Information Sharing Service; KISS, Korean Studies Information Service System; OASIS, Oriental Medicine Advanced Searching Integrated System.

2. Literature analysis

In addition to the articles identified through our literature search, we refer to 1 domestic and 4 Chinese publications, including a book (*Small needle-knife therapy*) written by Zhu Hanzhang (朱汉章), in order to identify the exact location and meaning of the MAPs used in the previously searched studies and propose other clinically applicable MAPs^{2,3,10,11,12}. Because the major blood vessels and nerves pass through the front and side rather than the back of the cervical region, we determined that performing MA on that region is relatively dangerous. Therefore, we analyzed the MAPs that can be used for treatment in the posterior part of the cervical region.

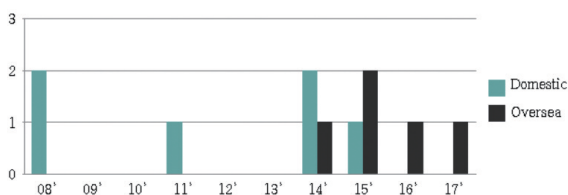


Fig. 2. Published year of studies of miniscalpel acupuncture of the cervical spine

III. Results

1. Study analysis

1) General studies (Table 1)

Before 2010, there were only 2 MA studies of the cervical region. Subsequently, more than twice as many studies have been conducted over the last 5 years (Fig. 2).

Eleven studies were examined 6 case series, 2 case reports, 2 review articles, and 1 randomized controlled trial (RCT) (Fig. 3).

The 2 review articles analyzed the use of MA cases for chronic nonspecific neck pain and myofascial pain syndrome (MPS) in China^{13,14}. In 1 of the 6 case series, the immediate results of the MA

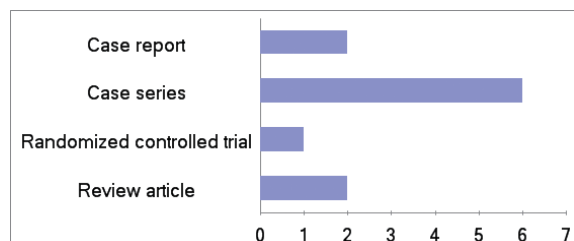


Fig. 3. Classification of study type

Table 1. Key Data of Studies Related to MA of the Cervical Spine

Study (year)	Study type	Country	Disease	MAPs	Authors' conclusions
Zheng et al. ¹⁶ (2014)	RCT	China	Chronic neck pain	Trigger point (not exact)	The MA arm was superior to the dry needling arm in reducing pain intensity and neck disability.
Li et al. ¹⁵ (2015)	Case series	China	Chronic neck pain	Painful tender points (Ashi points/not exact)	The MA release was effective, even 12 months after the treatment.
Liu et al. ¹³ (2015)	Review	China	MPS	Unspecified	All of the studies agreed on the potential benefit of MA as a strategy for MPS and its superiority compared with controls.
Li et al. ¹⁷ (2016)	Case series	China	Work-related neck and shoulder musculoskeletal disorders	One or two tender points on the neck or shoulder (not exact)	MA may be an effective intervention for work-related neck and shoulder musculoskeletal disorders and is associated with lower serum levels of inflammatory biomarkers.
Liu et al. ¹⁴ (2017)	Review	China	Chronic nonspecific neck pain	Unspecified	MA may be beneficial for chronic nonspecific neck pain.
Lee et al. ¹⁸ (2008)	Case series	Korea	Neck pain	Fig. 3 ①-⑧	The MA was effective in 14 of 16 patients.
Kim ¹⁹ (2008)	Case series	Korea	Cervical herniated intervertebral disc	Fig. 3 ①-⑧	There was significant improvement of neck pain in the MA group.
Park et al. ²⁰ (2011)	Case report	Korea	OPLL	Fig. 3 ①-⑧	MA for OPLL showed the effectiveness for pain and function of the patient.
Kim et al. ²² (2014)	Case series	Korea	Cervical herniated intervertebral disc at C3-6	C3-4, 4-5, 5-6 transverse process	MA has a meaningful effect when applied to the cervical spine.
Lee et al. ²¹ (2014)	Case series	Korea	Peripheral facial paralysis and postauricular pain	Fig. 3 ①-⑧, ⑨, facet joint of C1 and C3, mastoid	The cervical MA on the facial and trigeminal nerve branch may be effective for peripheral facial paralysis and postauricular pain.
Lee et al. ²³ (2015)	Case series	Korea	Cervical radiculopathy	Facet joint of the cervical lesion	MA was found to have clinical efficacy for cervical radiculopathy.

Abbreviations: MA, miniscalpel acupuncture; MAP, miniscalpel acupuncture point; RCT, randomized controlled trial; MPS, myofascial pain syndrome; OPLL, ossification of the posterior longitudinal ligament.

treatment as well as the results 12 months after the treatment were described¹⁵.

2) MAPs of the cervical region (Table 1)

In 9 studies (not including the 2 review articles), MA was performed on proximal acupoints. Proximal acupoints were classified as acupoints, trigger points, or Ashi points in the cervical region.

Specifically, in 3 studies, MA was performed

using the trigger or Ashi points¹⁵⁻¹⁷. In this review, we define Ashi points as the tender points or the sites where the patient feels sensitive or painful, not the acupoints, and the sites that the authors of the studies specified as Ashi points. Among the 3 studies, Zheng et al.¹⁶ conducted an RCT comparing a dry-needling arm and an MA arm for treatment of chronic neck pain, and found that the MA arm was more effective than the dry-needling arm. Li

et al.¹⁵) performed MA on painful tender points for chronic neck pain treatment, and not only did the pain decrease immediately after MA, but it was also less painful than before MA even 12 months after the MA. In another study by Li et al.¹⁷, after the MA treatment on 1 or 2 tender points on the neck or shoulder to remedy work-related neck and shoulder musculoskeletal disorders, significant effects were shown.

In the remaining 6 studies not discussed in the previous paragraph, specific MAPs were mentioned. First, in case reports on the treatment of neck pain, cervical herniated intervertebral disc, and ossification of the posterior longitudinal ligament (OPLL), the authors concluded that there was a significant therapeutic effect after MA^{18–20}. In all 3 studies, MA was performed using the same 10 MAPs (Fig. 4).

One point is centered on the external occipital

protuberance (Fig. 4 ①), and a line connecting 5 points is drawn horizontally. Then, two points are located 2–2.5 cm both side down of the external occipital protuberance on the linea nuchae superior (Fig. 4 ②), and again take one point each 2–2.5 cm from each side (Fig. 4 ③). Here, vertically from ①, take one point each at the C3–7 spinous process for a total of 5 points (Fig. 4 ④–⑧).

In addition, there was 1 case series in which peripheral facial paralysis and postauricular pain were treated using MA on 5 MAPs (①, and both ② and ③), the C1 transverse process (Fig. 4 ①A) and facet joints of C1 and C3¹⁹. Further, in 1 case series, cervical radiculopathy was treated using MA on the facet joint or the transverse process of the cervical lesion^{22,23}. In all 3 cases, the authors concluded that MA had a significant effect.

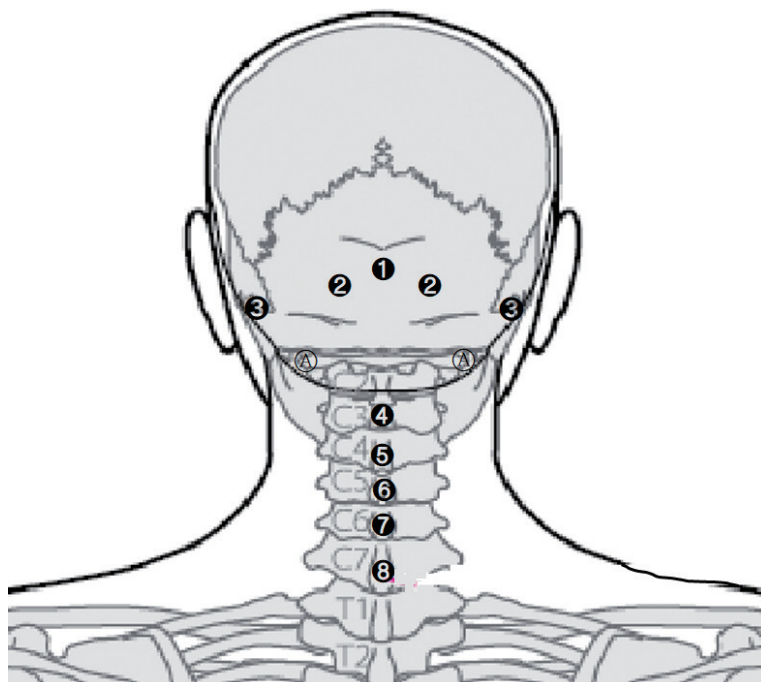


Fig. 4. The miniscalpel acupuncture points of the cervical spine (listed in the studies)

①: Below external occipital protuberance; insertion of nuchal ligament; origin of trapezius; upper site of GV16; ②: 2–2.5 cm side down of the external occipital protuberance; semispinalis capitis; origin of trapezius; insertion of obliquus capitis superior, rectus capitis posterior major, rectus capitis posterior minor; GB20; ③: 4.5–5 cm side down of the external occipital protuberance; insertion of the sternocleidomastoid muscle (posterior lateral), splenius capitis; GB12; ④–⑥: C3, C4, C5 spinous process, respectively; origin of nuchal ligament, splenius capitis; insertion of semispinalis cervicis; ⑦: C6 spinous process; origin of nuchal ligament, splenius capitis; ⑧: C7 spinous process; origin of nuchal ligament, splenius capitis; GV14; ①A: transverse process of atlas; origin of levator scapulae, obliquus capitis superior; insertion of obliquus capitis inferior.

2. Literature analysis

A review of 4 Chinese and 1 Korean publications on MA revealed MAPs in diseases such as nuchal ligament injuries, sternocleidomastoid muscle (SCM) injuries, splenius capitis injuries, and posterior neck muscle injuries^{2,3,10-12}. Of these, we found 13 additional MAPs accessible from the posterior part of the cervical region (Fig. 5).

The point in Fig. 5 ㉑ is located on the transverse process of the axis, and the points shown in Fig. 5 ㉒ and ㉓ are located on the lamina, which is 2 cm lateral to the C5 and C6 spinous processes, respectively. The point in Fig. 5 ㉔ is located at the middle point of the line connecting the C7 transverse process and the tip of the clavicle. The point in Fig. 5 ㉕ is a facet joint on both sides of the C2 spinous process, and the point in Fig. 5 ㉖ is located on the C2 spinous process.

IV. Discussion

The cervical spine has an anatomical structure that is different from that of the thoracic and lumbar spine and has designed to withstand the weight of the head and protecting the spinal cord, nerves, and blood vessels¹⁰. Recently, it is common to see neck pain in the clinic due to mental stress in the lives of modern people, caused by, for example, computer use and traffic accidents²². Neck pain is the feeling of pulling or pain in the flesh, sinews, and muscles of the front, back, side, or inside of the neck. Symptoms include limited range of motion, localized tender points, and, in severe cases, radiating pain in the scapula or upper limb¹⁹.

In medicine, cervical disc herniation, cervical spondylosis, wryneck, cervical strain, and the like are all considered “neck pain” and are treated using surgery, medication, muscle strengthening

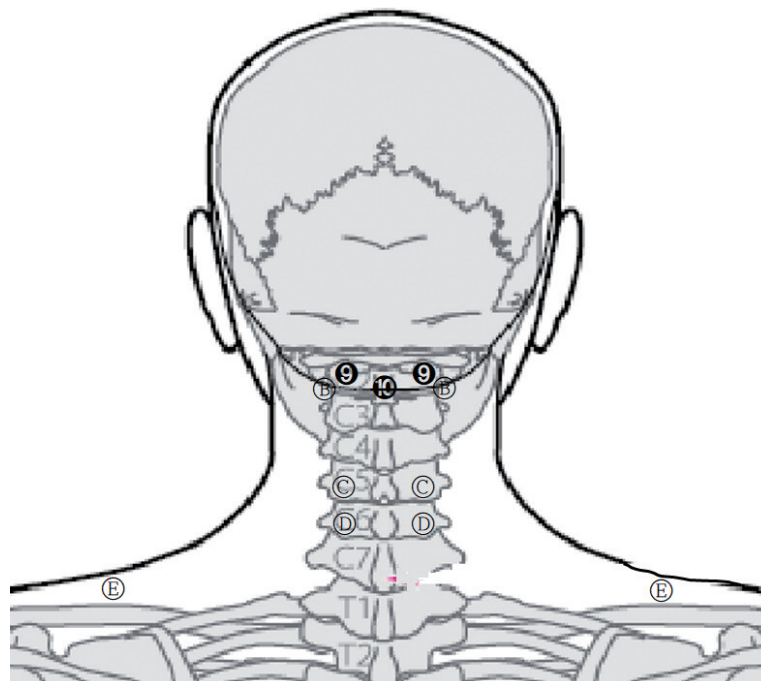


Fig. 5. The miniscalpel acupoints of the cervical spine (not listed in the studies)

㉑: Lateral to the C2 spinous process; facet joint; BL10; ㉒: C2 spinous process; origin of nuchal ligament, obliquus capitis inferior, rectus capitis posterior major; insertion of semispinalis cervicis; GV15; ㉓: transverse process of axis; origin of levator scapulae, medial scalene; ㉔: lamina of C5 (2 cm lateral to the C5 spinous process); splenius capitis; semispinalis capitis; ㉕: lamina of C6 (2 cm lateral to the C6 spinous process); splenius capitis; semispinalis capitis; ㉖: GB21; upper trapezius.

exercises, and physical therapy. In traditional Korean medicine, neck pain is considered to include stiffness of the neck (項強), headache, and painful stiff nape (頭項強痛) and is treated using Korean medicine, acupuncture, moxibustion, chuna, exercise therapy, and MA¹⁹.

MA is used to restore the tissue by a fine wound mechanism, which is to restore adhesions, scarring, and synechia of soft tissues to its previous dynamic state and to unblock lesions through dilation of small blood vessels. It is also used for chronic and troublesome musculoskeletal diseases by eliminating excessive pressure in the body and releasing adhesion of blood vessels, nerves, and muscles²⁰. However, there are no review articles on MAPs despite the fact that because the cervical spine has more important structures such as nerves and blood vessels, we should pay more attention to MAPs of the cervical spine.

When the force balance between the soft tissues in the cervical spine breaks, cervical disc pressure is increased and the cervical joint surface stimulus is added to increase the pressure of the spinal nerve roots. Ultimately, the final cause of neck pain is a soft tissue problem²⁴. MA for neck pain is a technique based on the pathological framework of chronic soft tissue injury.

On this basis, we analyzed MAPs of the posterior part of the cervical spine through both domestic and foreign studies and publications related to MA in the cervical region.

Two of the 11 studies include in this review used MA for its therapeutic effect in chronic neck pain and MPS in China, respectively. In both studies, no exact MAP was mentioned^{13,14}.

In the 3 studies using trigger points and Ashi points, it was concluded that MA had a significant effect on neck pain. However, it has been reported that the treatment of trigger points and Ashi points is effective, but the cure rate is low. Therefore, it is not likely to be suitable for clinical use with anticipation of a high therapeutic effect²⁵.

The most frequently mentioned sites in the 6 studies in which MAPs were presented were ①–⑥

in Fig. 4. There was a significant effect of MA on chronic neck pain, cervical intervertebral disc herniation, and OPLL^{18–20}.

Point ① is the upper site of GV16 and is the insertion of the nuchal ligament and origin of the trapezius muscle. Point ② corresponds to GB20, located on semispinalis capitis, and is origin of trapezius. It is also the insertion of the obliquus capitis superior, rectus capitis posterior major, and rectus capitis posterior minor. Point ③ corresponds to GB12, the posterior lateral insertion of SCM and splenius capitis. Points ④–⑧ are the origin of the splenius capitis, and points ④–⑥ are the insertion of semispinalis cervicis. Point ⑧ is equivalent to GV14. Points ① and ④–⑧ are placed on the nuchal ligament^{2,3,10–12}.

In addition, Lee et al.²⁰ conducted a comparative study between a control group treated using acupuncture and pharmacopuncture and an experimental group treated using acupuncture, pharmacopuncture, and MA for peripheral facial palsy and postauricular pain. In addition to points ①–⑧, ① and ② and facet joints of C1 and C3 were performed using MA. Point ① is the transverse process of C1, and it is also the origin of the levator scapulae, obliquus capitis superior, and insertion of the obliquus capitis inferior. Further, MA was also performed on tender points near the mastoid process for a decompression effect on the area where facial nerve starts. They reported that they obtained better results in the group treated using acupuncture, pharmacopuncture, and MA. MA used in Lee et al.²⁰'s study is expected to relax the fascia and muscles, and by stimulating the head and neck fascia by fascia theory, the release of muscle tension activates the venous and lymph circulation and helps to restore the paralyzed nerve.

To reduce the increased pressure of the spinal cord space and intervertebral foramina of the cervical spine in cervical radiculopathy, Lee et al.²⁰ tried to relieve neck pain by widening the space using MA on the facet joints of the cervical lesion. Since 50% to 70% of the patients with chronic neck pain had facet joint syndrome, this study is mean-

ingful. Therefore, MAPs of this study are considered useful for the MA procedure.

All the above-mentioned MAPs correspond to on the muscles or the origin or insertion of the muscles, and all the muscles except the SCM are muscles that help cervical motions in the back of the neck.

The main lateral muscles of the neck are the levator scapulae and trapezius, which cause continuous weighting of both shoulders. The levator scapulae is important in the mechanism for 'straightening of the cervical curvature', which refers to the posture of the head in front of the body, due to the displacement of the cervical spine resulting from an increase in the number of white-collar workers and excessive schoolwork²⁶⁾. The posterior neck muscles such as the levator scapulae, splenius capitis, suboccipitals, and trapezius act to maintain the stability of the spine in the forward head position²⁴⁾. In this process, the patient feels not only neck pain but also traction of the back of the neck and shoulder stiffness. In addition, the stiffness in the back of the neck can cause headache and dizziness by restricting the blood circulation to the head²⁶⁾. To treat weakened muscles as the 'straightening of the cervical curvature' progresses, the above-mentioned points ①-③ and ⑧ as well as points ⑨-⑩, ③-⑤, ⑥-⑧, can be used.

Point ⑨ corresponds to BL10 and can treat the obliquus capitis inferior and trapezius. Point ⑩ is equivalent to GV15 and is located at the origin of the nuchal ligament, obliquus capitis inferior, rectus capitis posterior major, and insertion of the semispinalis cervicis. MA can be performed on point ⑩ along with ① and ④-⑧ when there is nuchal ligament injury because they are located at the nuchal ligament. Excessive flexion or sudden movement of the head can result in nuchal ligament injuries, and if nuchal ligament injuries caused by acute trauma during the young adult period are not treated, the neck pain may become chronic. Over time, calcium deposits can form on this site leading to calcification or ossification,

which can cause an imbalance of the surrounding muscles and damage or degenerative changes of nearby vertebral segments²⁾. Therefore, points ①, ④-⑧, and ⑩ can be considered when the ligament is injured.

Points ③ and ⑤ can be used, along with points ③ and ⑧, to treat the splenius capitis and to treat the semispinalis capitis along with ①. Point ⑥ corresponds to GB21 and is the site where the trigger point of the trapezius occurs the most.

Point ⑧ is the origin of the levator scapulae and medial scalene. The scalene abnormality causes an imbalance of the neck and jaw, is closely related to upper limb and shoulder pain, and may be similar to a cervical herniated intervertebral disc of C5-C7. When the scalene is tense, it compresses blood vessels and nerves passing around the scalene and worsens pain at night, causing insomnia²⁷⁾. Alleviation of these symptoms can be expected by using ⑧.

The space between the obliquus capitis inferior, obliquus capitis superior, and rectus capitis posterior major is called the 'suboccipital triangle'. Since the vertebral artery and the occipital nerve passes through this space, we need to pay more attention to using MA on points ①, ②, and ⑨-⑩, which are in the suboccipital triangle and the origin or insertion of the obliquus capitis inferior, obliquus capitis superior, and rectus capitis posterior major.

We analyzed MAPs in the cervical region that were used in previous domestic and foreign studies and other clinically applicable MAPs on the posterior cervical spine presented in the publications. There is a risk of using MA on the cervical region in the clinic unless the anatomy of the cervical spine and the running direction of the nerves and blood vessels are fully understood. In addition, there are few studies, either domestic or foreign, on using MA in the cervical region, and they do not describe the exact MAPs, so the reproducibility of MA is poor. In future studies, it would be desirable to review the Chinese studies that use more MA in the cervical region, and it would be more meaningful to consider the stability of the MA as well.

Zheng et al.¹⁶⁾ showed that MA is more effective for chronic neck pain than acupuncture. This suggests that MA may be widely used in future clinical trials. Furthermore, in this study, we analyzed the location and the meaning of clinically applicable MAPs in the cervical region. Thus, we set clear standards for performing MA in the cervical region and hope that this study will be the basis for the development of MA, including improving safety and reproducibility in future MA studies of the cervical region.

V. References

- Mun MS, Kim I, Han IH. A clinical study of cervical spondylosis. *J Korean Orthop Assoc.* 1973;8(1):29–38.
- Kang CS, Yang HM. *Acupotomy and clinic.* Seoul: Dawoo. 2011:21–44, 139–58.
- Zhu HZ. *Small needle–knife therapy.* Beijing: Chinese medicine press. 1992:87, 123–40.
- Kim SC. Clinical characteristics of poor responders to acupotomy and safety pretreatment management. *The Acupunct.* 2008;25(4):117–25.
- Cho KH, Ki W, Yuk DI, Sung IS, Kim MJ, Hong KE. The study on the infection control of acupotomy. *The Acupunct.* 2013;30(4):181–7.
- Yuk DI, Kim KM, Jeon JH, Kim YI, Kim JH. A review of trends for acupotomy. *The Acupunct.* 2014;31(3):35–43.
- Yuk DI. Clinical study on 437 patients with lumbar spine stenosis treated by acupotomy combined with oriental medical treatments [dissertation]. Daejeon: Daejeon Univ. 2013. Korean.
- Jang EH, Kim SC, Lim NR et al. Case study of oriental medicine treatment with acupotomy therapy of the herniated lumbar intervertebral disc patient. *The Acupunct.* 2008;25(4):171–81.
- Jun P, Liu Y, Park JE, Jung SY, Han CH. The state of clinical trials on acupotomy for lumbar disc herniation in china. *Journal of Korean Medicine Rehabilitation.* 2017;27(2):39–54.
- Pang J. *Acupotomy basis and clinic.* China: Futian District Caitian Road Haitian Publishing Building: Shenzhen Haitian Publishing House. 2006:337–43.
- Zhu HZ. *Needle–knife clinical diagnosis and treatment.* Beijing: People’s Medical Publishing House. 1999:77–81, 87–8.
- Li DN. *Scalpel Essentials of Diagnosis and Treatment.* Beijing: China Press. 2007:115–30, 133–4.
- Liu T, Peng Y, Zhu S et al. Effect of miniscalpel–needle on relieving the pain of myofascial pain syndrome:a systematic review. *J Tradit Chin Med.* 2015;35(6):613–9.
- Liu F, Zhou F, Zhao M, Fang T, Chen M, Yan X. *Acupotomy therapy for chronic non–specific neck pain: a systematic review and meta–analysis [dissertation].* Nanchang city: Jiangxi Univ. 2017. Chinese.
- Li S, Shen T, Liang Y, Zhang Y, Bai B. Effects of miniscalpel–needle release on chronic neck pain: A retrospective analysis with 12–month follow–up [Internet]. *PLoS ONE.* 2015;10(8):e0137033.
- Zheng Y, Shi D, Wu X et al. Ultrasound–guided miniscalpel–needle release versus dry needling for chronic neck pain: A randomized controlled trial. *Evid Based Complement Alternat Med.* 2014;2014:1–8.
- Li S, Shen T, Liang Y, Bai B, Zhang Y. Miniscalpel–needle treatment is effective for work–related neck and shoulder musculoskeletal disorders. *Evid Based Complement Alternat Med.* 2016;2016:1–9.
- Lee GM, Kim DH, Kim HW et al. The clinical study on the effect of T–shaped acupotomy in neck pain. *The Acupunct.* 2008;25(4):191–6.
- Kim EK. *The clinical study on effects of acupotomy therapy in patients with cervical herniated intervertebral disc [dissertation].* Jeollabuk–do: Wonkwang Univ. 2008. Korean.

- rean.
20. Park SW, Kim SS, Yang SB, Lee GM. The clinical effects of acupotomy for ossification of the posterior longitudinal ligament. *The Acupunct.* 2011;28(4):127-35.
 21. Lee ES, Jeong JY, Seo DG et al. Clinical research of cervical acupotomy effects with acupuncture on facial & trigeminal nerve branch on peripheral facial paralysis and postauricular pain. *The Acupunct.* 2014;31(4):143-54.
 22. Kim SY, Kim HJ, Ji YS, Lee SM, Kim YI. The effect of acupotomy on lumbar and cervical spine combined with oriental medical treatment: Report of five cases. *The Acupunct.* 2014;31(2):183-93.
 23. Lee GM, Lee HJ, Kim YS et al. Minimally invasive widening of the facet joints in cervical radiculopathy by modified needles: Technical report. *Journal of Pharmacy and Pharmacology.* 2015;6(5):285-92.
 24. Peggy A. *Therapeutic Exercise for Athletic Injuries.* U.S.A: Human Kinetics Publishers, 2000: 354-86.
 25. Zhang T, Wu X. *Treatment of cervical spondylosis with T-shaped acupotomy.* Beijing: Friend of Science of Amateurs, 2008:29-30.
 26. Jin CW. *The effect of manual therapy on pain, depression and quality of life in patients with cervical hypolordosis [dissertation].* Seoul: Sungshin Univ, 2015, Korean.
 27. Park IG. *Physical therapy treatment effectiveness for patients with military neck syndrome [dissertation].* Daegu: Keimyung Univ. 2010, Korean.