

**Case Report**

## Gastric Hemangioma Treated with Argon Plasma Coagulation in a Newborn Infant

Young Ah Lee, Peter Chun\*, Eun Ha Hwang\*, Yeoun Joo Lee\*, Chang Won Kim†, and Jae Hong Park\*

Good Gang-An Hospital, Departments of \*Pediatrics and †Radiology, Pusan National University College of Medicine, Busan, Korea

Gastric hemangioma in the neonatal period is a very rare cause of upper gastrointestinal bleeding. We present a case of hemangioma limited to the gastric cavity in a 10-day-old infant. A huge, erythematous mass with bleeding was observed on the lesser curvature side of the upper part of the stomach. Surgical resection was ruled out because the location of the lesion was too close to the gastroesophageal junction. Medical treatment with intravenous H<sub>2</sub> blockers, octreotide, packed red blood cell infusions, local epinephrine injection at the lesion site, application of hemoclip, and gel-form embolization of the left gastric artery did not significantly alter the transfusion requirement. Hemostasis was achieved with endoscopic argon plasma coagulation (APC). After two sessions of APC, complete removal of the lesion was achieved. APC was a simple, safe and effective tool for hemostasis and the ablation of gastric hemangioma without significant complications.

**Key Words:** Hemangioma, Stomach, Neonate, Argon plasma coagulation

### INTRODUCTION

Hemangioma of the gastrointestinal tract may be a source of acute or chronic blood loss but is a rare occurrence. This tumor can arise in most parts of the digestive system. Gastric hemangioma is extremely rare in the pediatric age group, with only 13 cases reported in the English literature till 2007 [1]. It may present as a solitary tumor or multiple tumors and have capillary or cavernous histology [2]. Hemangiomas

grow rapidly from the first weeks of life to the age of 1 year or undergo spontaneous involution during early childhood [3].

Various therapeutic modalities including pharmacotherapy, intravascular embolization or sclerosis, endoscopic sclerotherapy or banding, surgical resection, and portal decompression are available to treat the gastrointestinal hemangiomas [3,4].

We report here a case of hemangioma limited to the gastric cavity in a 10-day-old infant who was pre-

Received : June 21, 2016, Revised : July 4, 2016, Accepted : July 5, 2016

**Corresponding author:** Jae Hong Park, Department of Pediatrics, Pusan National University Children's Hospital, 20 Geumo-ro, Mulgeum-eup, Yangsan 50612, Korea. Tel: +82-55-360-2180, Fax: +82-55-360-2181, E-mail: jhongpark@pusan.ac.kr

Copyright © 2017 by The Korean Society of Pediatric Gastroenterology, Hepatology and Nutrition

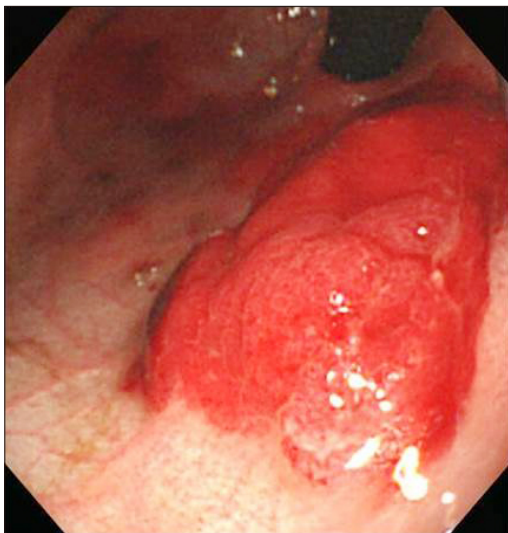
This is an open-access article distributed under the terms of the Creative Commons Attribution Non-Commercial License (<http://creativecommons.org/licenses/by-nc/4.0/>) which permits unrestricted non-commercial use, distribution, and reproduction in any medium, provided the original work is properly cited.

sented with hematemesis and melena. The bleeding was refractory to conventional treatments. Argon plasma coagulation (APC) played a significant role in hemostasis and ablation of the lesion. This is the first documented case of gastric hemangioma in a neonate treated with APC.

## CASE REPORT

The patient was a full-term-born male. The perinatal period was uneventful, and he received no medication. He was fed breast milk and ten days after birth, he vomited bright red blood. The APT test was negative, and he had no coagulopathy. His feeding was stopped but blood leakage via the nasogastric tube continued, and therefore, he was transferred to our hospital. The conjunctivae were slightly pale. The abdomen was soft and flat. The liver and spleen were not palpable. A moderate amount of melanotic stool was observed.

Initial laboratory test results were as follows: hemoglobin, 9.8 g/mm<sup>3</sup>; hematocrit, 27.8%; platelets 410,000/mm<sup>3</sup>; and leukocytes, 8,310/mm<sup>3</sup> (55.6% segmented neutrophils, 34.6% lymphocytes). No abnormalities were noted on the peripheral smear.



**Fig. 1.** Endoscopic image of the gastric hemangioma, showing a huge, erythematous mass with bleeding on the lesser curve side of the upper part of the stomach.

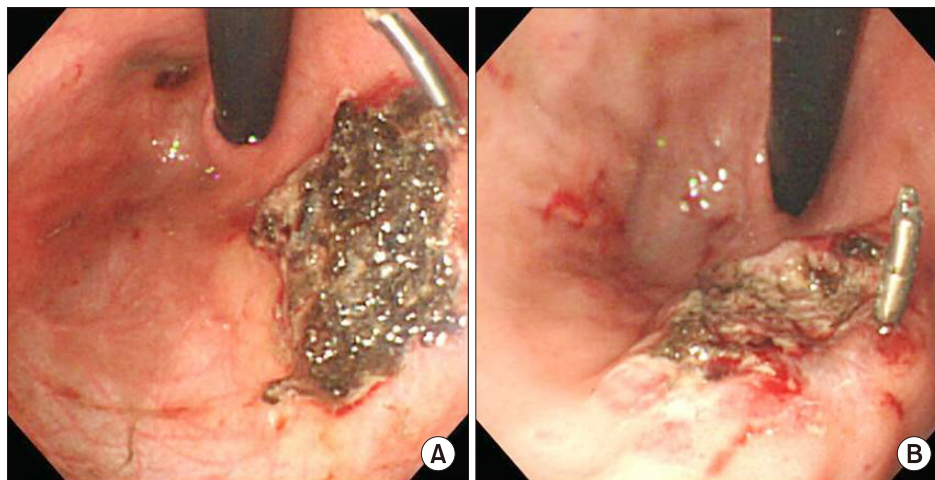
Prothrombin time, activated partial thromboplastin time, and biochemical liver function tests were normal.

Initial esophagogastroduodenoscopy (EGD) revealed a huge, erythematous mass with bleeding on the lesser curvature side of the upper part of the stomach (Fig. 1). The size of the lesion was estimated about 23×36 mm in diameter. No other vascular anomalies were found not only in the gastrointestinal tract but also in the skin. He was administered endoscopic epinephrine injection onto the lesion, H<sub>2</sub> blockers, and sucralfate, and received total parenteral nutrition. However, intermittent bloody drainage from the nasogastric tube continued.

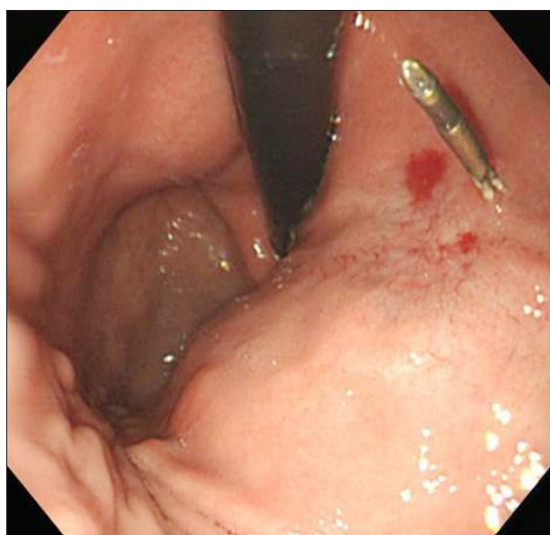
Six days later, a hemostatic clip (HX-600-135; Olympus Optical Co. Ltd., Tokyo, Japan) was applied to the lesion, and clipping was repeated twice every week. Intermittent bloody drainage from the nasogastric tube continued.

One day later, gel-form embolization on angiography was performed, which stopped the bleeding. However, after enteral feeding, bleeding recurred. Management with intravenous H<sub>2</sub> blocker, octreotide, and packed red blood cell infusions did not significantly alter the transfusion requirement.

On the nineteenth hospital day, endoscopic argon plasma cautery with ARCO-3000 Söring argon coagulation & electro-surgery unit (Söring Medizintechnik, Quickborn, Germany) was performed (Fig. 2A), and the bleeding was ceased. Repeat APC was performed 18 days later to remove the residual lesion (Fig. 2B). Bleeding did not occur after the second coagulation and the child was discharged. Two months later, hematemesis recurred. EGD revealed scarring and ulcerization with bleeding at the cauterization site. The lesion was treated with endoscopic hemostatic clipping and proton pump inhibitors. There were no further episodes of bleeding. Follow-up EGD at 9 months after initial APC demonstrated complete ablation of hemangioma without complications (Fig. 3).



**Fig. 2.** (A) Endoscopic image of initial argon plasma coagulation (APC) showing necrotic tissue on the surface of the treated area. (B) Endoscopic image after second APC performed 18 days after initial APC.



**Fig. 3.** Follow-up endoscopic image at 9 months after initial APC showing complete ablation of hemangioma without complications.

## DISCUSSION

Gastric hemangioma in the neonatal period is extremely rare. Bleeding can be fatal if not immediately managed. Nagaya et al. [5] reported a case of isolated cavernous hemangioma of the stomach treated with surgery in a neonate. To our knowledge, this is the first report of successful treatment of gastric hemangioma with APC in a newborn.

Hemangiomas proliferate at a rapid rate in the first

6 months of life, and they involute before puberty. Pharmacologic inhibition of angiogenesis is the mainstay of hemangioma therapy. However, conservative management was ruled out because of significant bleeding in this case.

Although histological examination of the tissue sample obtained via endoscopic biopsy would have aided in definitive diagnosis, it was not performed to prevent additional bleeding. Based on endoscopy and left gastric angiography (late filling phenomenon) findings, the lesion was identified as a gastric hemangioma. Angiography is helpful in demonstrating the arterial supply to the tumor and is the method of choice for confirming the diagnosis [6].

Gastrectomy should be performed only when bleeding is refractory to other procedures. Surgical wedge resection could be considered in this case. However, the location of the lesion was too close to the gastroesophageal junction, the authors worried about malfunction of the junction.

A review of the literature reveals several sporadic cases treated endoscopically, using banding, laser photocoagulation, or Nd:YAG laser and bipolar electrocoagulation in multiple hemangiomas [7,8]. Endoscopic APC has been used for the successful treatment of a wide spectrum of mucosal lesions. Khan and Weisdorf-Schindele [9] reported a gastric hemangioma managed with APC in a 9-month-old infant. They also reported that endoscopic APC was

efficacious for hemostasis and tissue ablation in 13 pediatric cases [10]. Despite various treatments, bleeding could not be controlled in this case. Ultimately, the authors applied APC to the lesion because APC had been reported as the most efficacious procedure for hemostasis and tissue ablation of the gastrointestinal hemangiomas in infants [9,10].

APC is a non-contact electrocoagulation method that uses high-frequency current transmitted to the tissues via a jet of ionizing argon gas. Because tissue destruction is homogeneous and shallow, the risks of perforation and stricture formation are low [11]. In the present case, the power setting (20-40 W) and argon flow rate (1.0 L/min) were similar to those used for adults.

Hemangioma proximal to the gastric fundus represents a technical challenge. In this case, the location of the lesion at the lesser curve side of the upper part of the stomach, necessitated performing the procedure with the scope in a retroflexed state. Repeated coagulation of hemangioma with APC can cause a scarring and ulceration [10], as in our case.

In our case, APC resulted in complete ablation of gastric hemangioma without complications. This report provides evidence that endoscopic APC is a safe and effective treatment modality for gastric hemangioma in neonates.

## REFERENCES

1. Menon P, Rao KL, Bhasin S, Vanitha V, Thapa BR, Lal A, et al. Giant isolated cavernous hemangioma of the stomach. *J Pediatr Surg* 2007;42:747-9.
2. Bamanikar AA, Diwan AG, Benoj D. Gastric hemangioma: an unusual cause of upper gastrointestinal bleed. *Indian J Gastroenterol* 2004;23:113-4.
3. Fishman SJ, Burrows PE, Leichtner AM, Mulliken JB. Gastrointestinal manifestations of vascular anomalies in childhood: varied etiologies require multiple therapeutic modalities. *J Pediatr Surg* 1998;33:1163-7.
4. López-Gutiérrez JC. Hemangiomas and vascular malformations of the stomach. *J Pediatr Surg* 2007;42:1634-5.
5. Nagaya M, Kato J, Niimi N, Tanaka S, Akiyoshi K, Tanaka T. Isolated cavernous hemangioma of the stomach in a neonate. *J Pediatr Surg* 1998;33:653-4.
6. Stillman AE, Hansen RC, Hallinan V, Strobel C. Diffuse neonatal hemangiomatosis with severe gastrointestinal involvement. Favorable response to steroid therapy. *Clin Pediatr (Phila)* 1983;22:589-91.
7. Bak YT, Oh CH, Kim JH, Lee CH. Blue rubber bleb nevus syndrome: endoscopic removal of the gastrointestinal hemangiomas. *Gastrointest Endosc* 1997;45:90-2.
8. Dieckmann K, Maurage C, Faure N, Margulies A, Lorette G, Rudler J, et al. Combined laser-steroid therapy in blue rubber bleb nevus syndrome: case report and review of the literature. *Eur J Pediatr Surg* 1994;4:372-4.
9. Khan K, Weisdorf-Schindele S. Gastric hemangiomas in an infant managed with argon plasma coagulation. *Pediatr Endosurgery Innov Tech* 2003;7:185-8.
10. Khan K, Schwarzenberg SJ, Sharp H, Weisdorf-Schindele S. Argon plasma coagulation: clinical experience in pediatric patients. *Gastrointest Endosc* 2003;57:110-2.
11. Grund KE. Argon plasma coagulation (APC): ballyhoo or breakthrough? *Endoscopy* 1997;29:196-8.