

방사선 조사된 상악골에서 all-on-4 임플란트에 의해 지지되는 지르코니아 고정성 보철물 수복 증례

최은주¹ · 조혜원^{2*}

¹원광대학교 치과대학 ¹구강악안면외과학교실, ²치과보철학교실

Zirconia ceramic fixed dental prosthesis with all-on-4 concept implants for irradiated maxilla: A case report

Eun-Joo Choi¹, Hye-Won Cho^{2*}

¹Department of Oral and Maxillofacial Surgery, ²Department of Prosthodontics, College of Dentistry, Wonkwang University, Iksan, Republic of Korea

The implant-supported fixed dental prosthesis in irradiated maxilla needs meticulous treatment planning due to low bone healing capacity. All-on-4 concept implantation can reduce the number of implants to be placed avoiding bone grafting procedure. Conventionally, prefabricated angled abutments for tilted implants have been used. However, in this case, it was replaced with computer-aided design and computer-aided manufacturing (CAD/CAM) abutment. This case report described all-on-4 concept implantation and fabrication of CAD/CAM zirconia fixed dental prostheses using CAD/CAM titanium abutments. (*J Korean Acad Prosthodont* 2017;55:218-24)

Keywords: Tilted implant; All-on-4 implant; Maxillary edentulous patient; Zirconia fixed prosthesis

Introduction

For a patient with single edentulous arch opposed by a natural or restored dentition, complete denture or implant assisted overdenture might not be considered as the standard therapy any more due to varying support.¹ Prosthodontic replacement in irradiated edentulous maxilla needs meticulous treatment planning due to low bone remodeling capacity, radiation caries, periodontal infection and reduced salivary secretions.²

Implant placement in patients with reduced bone volume in the posterior region can be treated using all-on-4 concept implantation avoiding bone grafting procedures.^{3,6} The advantages of all-on-4 concept implantation are reduced number of implants needed, capability of longer implant placement, and decreased cantilever length of prosthesis.⁷

Zirconia ceramic complete-arch implant-supported fixed dental prosthesis has been encouraged by high biocompatibility, low bacterial surface adhesion, high flexural strength and improved esthetic properties.⁸⁻¹⁰ The metal-resin hybrid prosthesis has shown complications such as fracture of resin teeth or resin base, loosening or fracture of prosthetic or abutment screws, and fracture of implant abutments.^{11,12} Since zirconia based, implant-supported fixed dental prosthesis showed high survival rate up to 100%,¹¹ it could be a good substitute for metal-resin prosthesis. The purpose of this case report was to document a treatment procedure of maxillary edentulous patient with all-on-4 concept implantation using customized titanium abutments and cement-retained zirconia ceramic complete-arch fixed dental prostheses. Treatment goals were to improve mastication and esthetics.

*Corresponding Author: Hye-Won Cho

Department of Prosthodontics, College of Dentistry, Wonkwang University

460 Iksan-daero, Iksan, Jeonbuk 54538, Republic of Korea

+82 (0)63 859 2938 : e-mail, hwcho@wku.ac.kr

Article history: Received December 13, 2016 / Last Revision January 18, 2017 / Accepted February 3, 2017

※ Supported by Wonkwang University 2017.

© 2017 The Korean Academy of Prosthodontics

© This is an Open Access article distributed under the terms of the Creative Commons Attribution Non-Commercial License (<http://creativecommons.org/licenses/by-nc/3.0>) which permits unrestricted non-commercial use, distribution, and reproduction in any medium, provided the original work is properly cited.

Case Report

A 62-year-old woman was found with ulcerative lesion on the left maxillary tuberosity and diagnosed as squamous cell carcinoma (pT2N0M0) 7 years ago. Operation was performed including wide excision, elective neck dissection of level I to III, reconstruction of soft tissue defect with partial thickness of skin graft, and extraction of maxillary right posterior teeth. Adjunctive radiotherapy was done on primary site and ipsilateral neck with total irradiation of 6040cGy 2 month later. On follow-up check of 5 years after operation, there was no evidence of recurrence or distant metastasis. However all the posterior teeth were lost in the maxilla and left lateral incisor and canine needed to be extracted due to secondary caries and severe mobility (Fig. 1). It was considered that possibilities of development of osteoradionecrosis on left maxillary premolar area due to the irradiation history. However, bone healing was completed after extraction showing healing potential after dental implantation.

Her chief complaint was masticatory difficulty and unesthetic appearance due to loss of teeth. She could not bear the use of removable partial denture due to xerostomia after radiation and reported with restricted mouth opening (approximately 2.3 cm). She wanted to restore

maxilla only as a result of gloomy prognosis of maxillary and mandibular remaining teeth due to cervical caries and mobility. A complete-arch implant-supported fixed dental prosthesis for maxilla was planned after a thorough discussion with her.

A cone beam computerized tomography scan (Alphard VEGA 3030, Asahi Co., Tokyo, Japan) was used to plan an all-on-4 procedure (Fig. 2). Patient was classified into Group 4, based on Maló's classification, whose maxillary bone was available up to canine-to-canine region.³ In the Group 4 patient, the 2 posterior tilted implants can be placed to follow the medial wall of maxillary sinus and restored as first premolars. The 2 anterior axial implants can be placed on 2 central incisor positions and all 4 implants splinted in one framework can be cantilevered to 1st molars.^{3,4,7}

The right canine and lateral incisor were atraumatically extracted and the right posterior tilted implant (4.0 × 11.5 mm, USII, Osstem, Pusan, Korea) was placed with 45-degree inclination along the medial margin of right maxillary sinus according to surgical stent. The left posterior tilted implant (4.0 × 13 mm) was placed 30-degree inclination 5 mm apart from the left sinus due to weak bone density. The two anterior axial implants (4.0 × 13 mm) were placed on the sockets of central incisors according to Group 4 protocol (Fig. 3).

After 6 months of healing, 4 implants were exposed and 30° angled

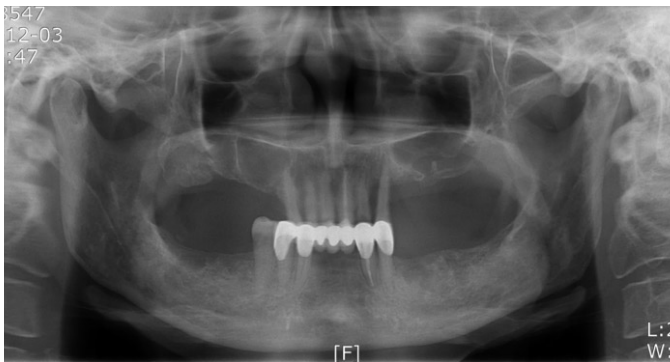

Fig. 1. Preoperative diagnostic panoramic radiograph.

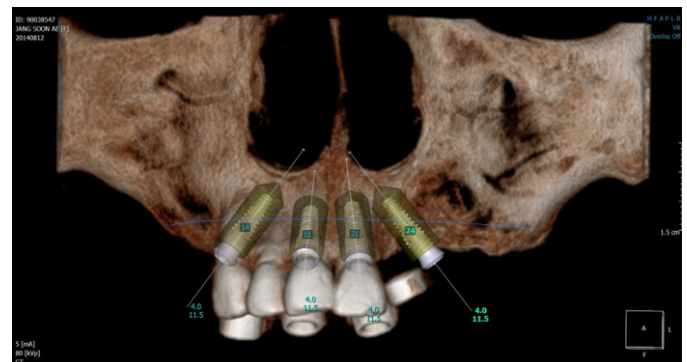


Fig. 2. Computerized tomographic view of planned implant positions for all-on-4 concept.

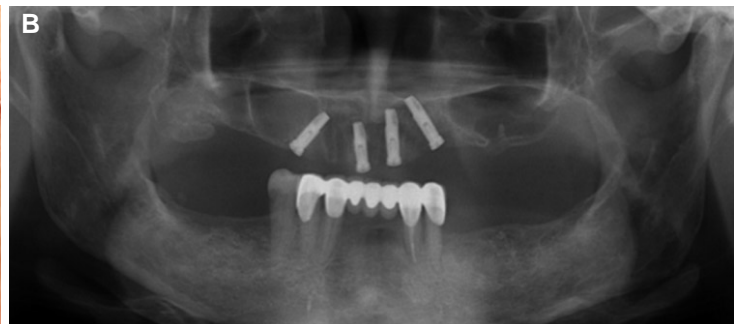
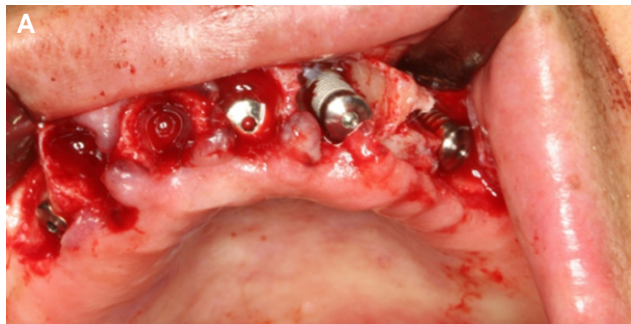

Fig. 3. Placement of implants. (A) Intraoral surgery images of implants placed in the maxilla. (B) Panoramic radiograph after all-on-4 implant placement surgery.

abutments (Multi-unit abutment, Nobel Biocare AB, Göteborg, Sweden) and impression copings (Multi-unit impression copings, Nobel Biocare AB) were placed on 2 tilted implants. Implant level impression copings (Osstem, Pusan, Korea) were connected on 2 axial implants and 4 impression copings were splinted with dental floss and autopolymerizing acrylic resin (Pattern resin, GC, Tokyo, Japan) (Fig. 4A). After 15 minutes of polymerization of acrylic resin, an impression was made using a high-viscosity polyvinyl siloxane impression material (Honigum Mono, DMG, Hamburg, Germany) in a custom open tray. The angled abutments were retrieved from the mouth and an implant-level definitive cast was fabricated (Fig. 4B). Screw-retained acrylic resin prostheses with temporary titanium abutments were delivered and followed up for 3 months (Fig.

4C). Occlusal contacts from right 1st premolar to left canine and no occlusal contact on cantilevered right 2nd premolar were maintained. Canine guidance during right and left lateral excursions and protrusive incisal guidance were provided in the provisional prosthesis.

A cement-retained implant-supported fixed prosthesis was planned after analysis of angulation and position of 4 implants. Computer-aided design and computer-aided manufacturing (CAD/CAM) titanium abutments (Smartfit abutment, Osstem, Pusan, Korea) were fabricated on 4 implants (Fig. 5) and new provisional prosthesis using 4 CAD/CAM abutments was delivered to examine the function and esthetics (Fig. 6). After 3 months, the CAD/CAM abutments were retrieved and old provisional prostheses was redelivered. The CAD/CAM abutments and new provisional

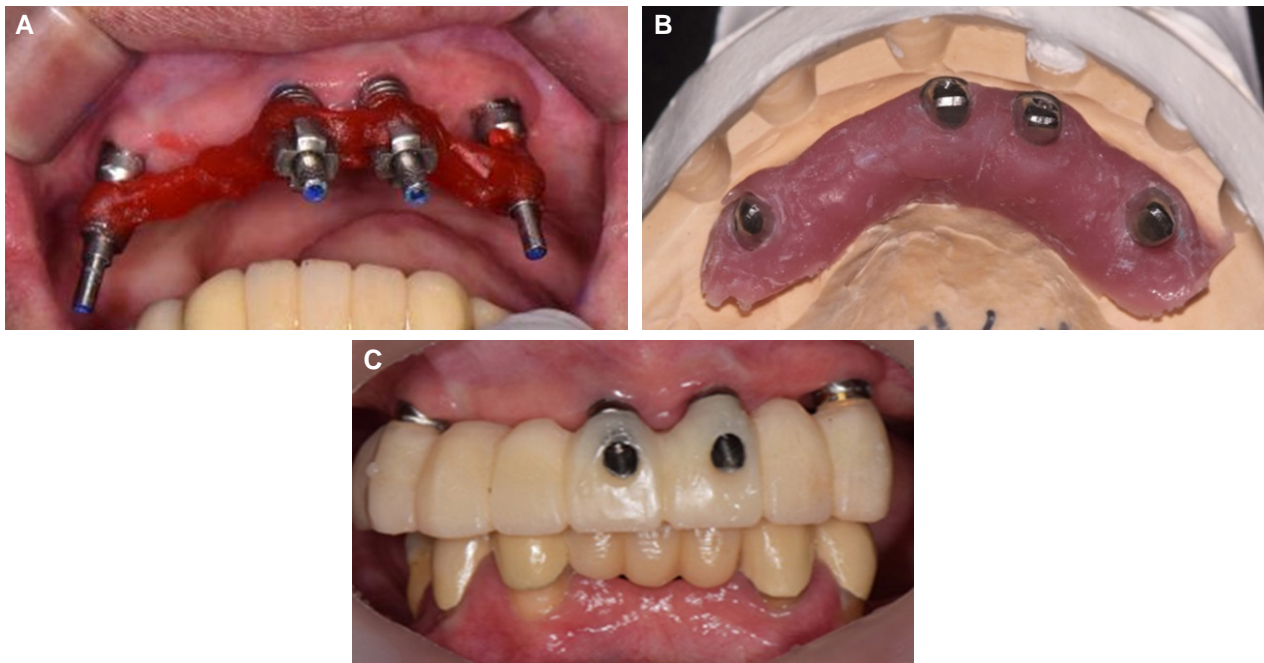


Fig. 4. Impression and provisional prosthesis. (A) Splinted impression copings connected to implants, (B) Definitive implant-level cast, (C) Delivery of provisional restorations with temporary abutments.

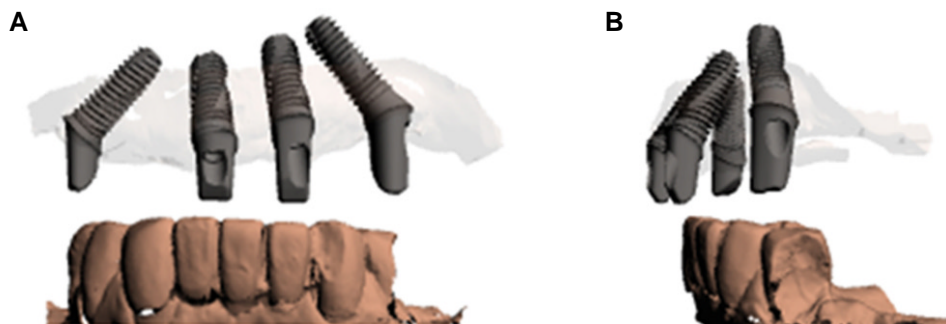

Fig. 5. Digital design of customized titanium CAD/CAM abutments. (A) frontal view, (B) sagittal view.

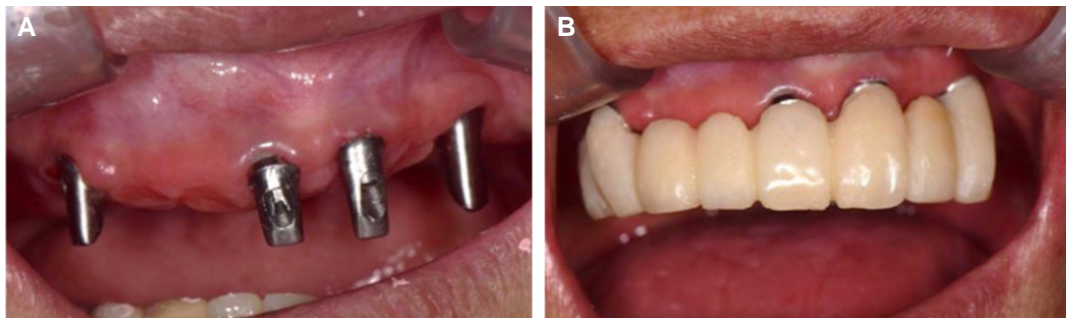


Fig. 6. CAD/CAM abutments. (A) Connected customized abutments to implants, (B) Provisional restoration on the CAD/CAM abutments.

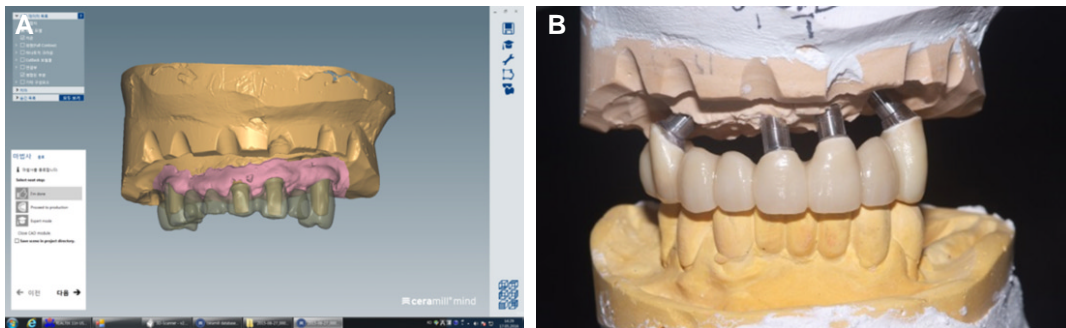


Fig. 7. Fabrication of zirconia ceramic prostheses. (A) Digitally designed zirconia framework, (B) Fabricated porcelain veneered zirconia fixed dental prostheses.

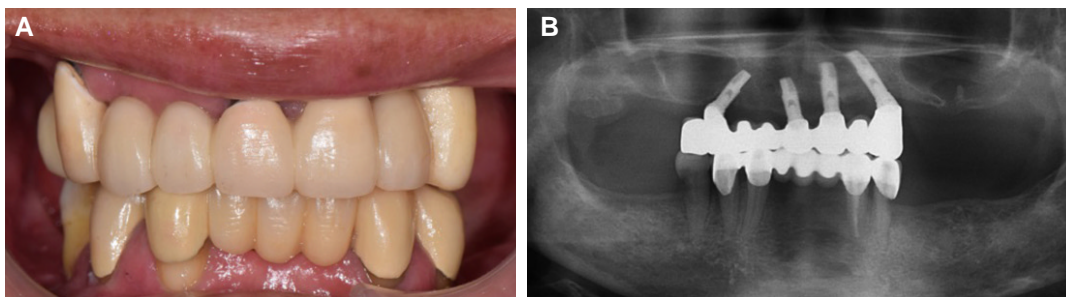


Fig. 8. Definitive zirconia prostheses. (A) Delivery of definitive zirconia ceramic prostheses, (B) Panoramic view of definitive prostheses in the patient.

prosthesis were placed on the mounted cast and digitally scanned with a laboratory scanner (Ceramill Map400, Amann Girrbach, Koblach, Austria). Zirconia framework was designed with software (Ceramill Mind v 2.7.05, Amann Girrbach) to mimic the provisional prosthesis (Fig. 7A). The zirconia framework was milled from the pre-sintered zirconia disc (Zolid, Amann Girrbach) using a 5-axis milling machine (Ceramill Motion2, Amann Girrbach). The margins were examined and the zirconia framework was crystallized in a sintering furnace (Ceramill therm, Amann Girrbach). Veneer porcelains (IPS e.max Ceram, Ivoclar Vivadent, Schaan, Liechtenstein) were added to the labial surfaces of zirconia framework and fired in a ceramic furnace (Fig. 7B).

The CAD/CAM titanium abutments were connected to 4 implants

and radiographically confirmed. The abutments were tightened to 20 Ncm torque twice with 10-minute intervals using a hand torque wrench in consideration of weak bone density.¹³ The marginal and internal adaptation of zirconia framework was confirmed with a dental explorer and evaluated with fit checker. Minor occlusal adjustments were done and the definitive complete-arch implant-supported fixed dental prosthesis was delivered using temporary cement at first and cemented using an adhesive resin cement (Rely X Unicem, 3M ESPE, Neuss, Germany) after 3 months (Fig. 8A). The patient has been seen every 6 months as a recall. After 2-year follow-up, there were no complications with the zirconia ceramic prosthesis or implants (Fig. 8B).

Discussion

Salivary changes in volume and viscosity after irradiation of major salivary glands predispose the patient to caries and periodontal disease.² All radiation-induced xerostomia patients are susceptible to cervical caries that may involve the entire circumference eventually leading to amputation of crowns.²

The patient had severe xerostomia and restricted mouth opening after radiation therapy. She lost all the molars and premolars in the maxilla due to cervical caries and periodontal infection. The loss of teeth seemed to be continuing in her mandibular teeth even though she was recalled regularly.

These changes also attribute to impairment of deglutition and poor tolerance of prosthetic restorations.² She tried to use maxillary and mandibular removable partial dentures for several years, but failed. She strongly refused to wear the removable partial dentures due to xerostomia, and an implant-supported fixed dental prosthesis using all-on-4 concept implantation was planned.

According to the treatment plan for Group 4,³ the posterior tilted implants can be restored as the 1st premolars and then cantilevered to the 1st molars. However, following cancericidal doses of radiation therapy, significant changes in bone affect the remodeling capability of bone.¹⁴ The implants in irradiated bone appeared to have significantly lower success rates than implants in non-irradiated bone and demonstrated advanced bone loss at an early stage. When the tumor dose exceeds 5500 cGy, conventional dental treatment cannot be employed.¹⁴ However, a dose of 6040 cGy was delivered to her left maxilla, the implant placed on that site was osseointegrated well enough to deliver a fixed dental prosthesis.

In this case, the right tilted implant was used as an abutment for the 1st premolar and extended to the 2nd premolar due to the absence of opposing teeth. On the other hand, the left tilted implant could not follow the left sinus wall because of weak bone density of irradiated maxilla, and restored as canine without cantilevered extension. She had no opposing teeth in the left side also. This type of shortened arch restoration could be beneficial for irradiated maxilla in accordance with the remaining mandibular dentition. After rehabilitation of completely edentulous mandible with implant-supported fixed prosthesis using 4 or more implants, maxillary zirconia ceramic fixed dental prosthesis can be extended to the 1st molars in both sides.

Immediate implant placement after extraction of 4 remaining teeth was planned because tooth-supported surgical guide was easily stabilized on the central incisors. Eventually the two anterior axial implants were immediately placed on the sockets of central incisors without surgical guide. As a matter of fact, since they were positioned too facially to hide access holes, a cement-retained fixed dental prosthesis was chosen for this patient to improve the esthetics and

function.

The CAD-CAM titanium abutments were fabricated to increase the dimension of implant abutments for better support of complete-arch zirconia fixed dental prosthesis. The prefabricated angled abutments for conventional hybrid prosthesis can be damaged by inadequate cylinder dimensions in a zirconia-based prosthesis.¹⁵ Although the cement-retained implant prosthesis is lacking in retrievability, the access to the abutment screws can be located precisely using a CAD-CAM screw channel drilling guide.¹⁶

The patient was satisfied with CAD-CAM zirconia fixed dental prostheses with all-on-4 concept implantation in edentulous maxilla. Since the zirconia-based fixed dental restorations exhibited 7% higher veneer chipping and less than 1% core fracture,¹⁷ the patient was scheduled for aggressive regular check-up.

Conclusion

The presented treatment using all-on-4 concept implantation and CAD-CAM titanium abutments resulted in the prosthetic restoration of an irradiated edentulous maxilla and improved mastication and esthetics.

ORCID

Eun-Joo Choi <http://orcid.org/0000-0002-6981-8439>

Hye-Won Cho <http://orcid.org/0000-0003-0623-5647>

References

1. Zarb G, Bolender C, Eckert S, Jacob R, Fenton A, Mericske-Stern R. Prosthodontic treatment for edentulous patients. 12th ed. St. Louis: Elsevier Mosby; 2004. p. 427.
2. Beumer J III, Curtis TA, Marunick MT. Maxillofacial rehabilitation: prosthodontic and surgical considerations. St. Louis: Ishiyaku Euro America, Inc.; 1996. p. 65-70, 85.
3. Maló P, Nobre Md, Lopes A. The rehabilitation of completely edentulous maxillae with different degrees of resorption with four or more immediately loaded implants: a 5-year retrospective study and a new classification. *Eur J Oral Implantol* 2011;4:227-43.
4. Maló P, de Araújo Nobre M, Lopes A, Francischone C, Rigolizzo M. "All-on-4" immediate-function concept for completely edentulous maxillae: a clinical report on the medium (3 years) and long-term (5 years) outcomes. *Clin Implant Dent Relat Res* 2012;14:e139-50.
5. Maló P, de Araújo Nobre MA, Lopes AV, Rodrigues R. Immediate loading short implants inserted on low bone quantity for the rehabilitation of the edentulous maxilla using an All-on-4 design. *J Oral Rehabil* 2015;42:615-23.
6. Barnea E, Tal H, Nissan J, Tarrasch R, Peleg M, Kolerman R. The Use of Tilted Implant for Posterior Atrophic Maxilla. *Clin*

- Implant Dent Relat Res 2016;18:788-800.
7. Kim KS, Kim YL, Bae JM, Cho HW. Biomechanical comparison of axial and tilted implants for mandibular full-arch fixed prostheses. *Int J Oral Maxillofac Implants* 2011;26:976-84.
 8. Abdulmajeed AA, Lim KG, Närhi TO, Cooper LF. Complete-arch implant-supported monolithic zirconia fixed dental prostheses: A systematic review. *J Prosthet Dent* 2016;115:672-7.
 9. Papaspyridakos P, Lal K. Computer-assisted design/computer-assisted manufacturing zirconia implant fixed complete prostheses: clinical results and technical complications up to 4 years of function. *Clin Oral Implants Res* 2013;24:659-65.
 10. Rojas-Vizcaya F. Full zirconia fixed detachable implant-retained restorations manufactured from monolithic zirconia: clinical report after two years in service. *J Prosthodont* 2011;20:570-6.
 11. Pozzi A, Holst S, Fabbri G, Tallarico M. Clinical reliability of CAD/CAM cross-arch zirconia bridges on immediately loaded implants placed with computer-assisted/template-guided surgery: a retrospective study with a follow-up between 3 and 5 years. *Clin Implant Dent Relat Res* 2015;17:e86-96.
 12. Kern JS, Kern T, Wolfart S, Heussen N. A systematic review and meta-analysis of removable and fixed implant-supported prostheses in edentulous jaws: post-loading implant loss. *Clin Oral Implants Res* 2016;27:174-95.
 13. Tsuge T, Hagiwara Y. Influence of lateral-oblique cyclic loading on abutment screw loosening of internal and external hexagon implants. *Dent Mater J* 2009;28:373-81.
 14. Roumanas E, Nishimura R, Beumer J, Moy P, Weinlander M, Lorant J. Craniofacial defects and osseointegrated implants: Six-year follow-up report on the success rates of craniofacial implants at UCLA. *Int J Oral Maxillofac Implants* 1994;9:579-85.
 15. Chang JS, Ji W, Choi CH, Kim S. Catastrophic failure of a monolithic zirconia prosthesis. *J Prosthet Dent* 2015;113:86-90.
 16. Lee DH. CAD/CAM-fabricated template for locating implant abutment screws in cement-retained anatomic zirconia restorations. *J Prosthet Dent* 2015;114:343-5.
 17. Heintze SD, Rousson V. Survival of zirconia- and metal-supported fixed dental prostheses: a systematic review. *Int J Prosthodont* 2010;23:493-502.

방사선 조사된 상악골에서 all-on-4 임플란트에 의해 지지되는 지르코니아 고정성 보철물 수복 증례

최은주¹ · 조혜원^{2*}

원광대학교 치과대학 '구강악안면외과학교실, '치과보철학교실

방사선치료를 받은 상악에 임플란트 지지 고정성 보철물을 이용하여 수복하는 것은 골치유능력이 낮기 때문에 상세한 치료계획이 필요하다. All-on-4 개념에 의한 임플란트 식립은 골이식을 피하면서 임플란트를 매식할 수 있어 유리하다. 일반적으로 경사된 임플란트에는 기성 경사형 지대주를 사용해왔다. 본 임상증례에서는 computer-aided design and computer-aided manufacturing (CAD/CAM)으로 제작된 지대주를 사용하였다. 본 증례는 all-on-4 개념에 의해 임플란트를 매식하고 CAD/CAM titanium 지대주를 제작한 다음 CAD/CAM zirconia 고정성 보철물로 수복하여 좋은 결과를 얻었기에 보고하고자 한다. (*대한치과보철학회지 2017;55:218-24*)

주요단어: 경사형 임플란트; all-on-4 임플란트; 상악무치악 환자; 지르코니아 고정성 보철물

*교신저자: 조혜원
54538 전북 익산시 익산대로 460 원광대학교 치과대학 치과보철학교실
063 859 2938 : e-mail, hwcho@wku.ac.kr

원고접수일: 2016년 12월 13일 / 원고최종수정일: 2017년 1월 18일 / 원고채택일:
2017년 2월 3일

© 2017 대한치과보철학회

© 이 글은 크리에이티브 커먼즈 코리아 저작자표시-비영리 3.0 대한민국 라이선스에 따라
이용하실 수 있습니다.

※ Supported by Wonkwang University 2017.