

# The Incidence of Venous Thromboembolism Following Shoulder Surgery: A Pilot Study

Chul-Hyun Cho<sup>✉</sup>, Hyung-Gyu Jang, Ui-Jun Park<sup>1</sup>, Hyoung Tae Kim<sup>1</sup>

Departments of Orthopedic Surgery and <sup>1</sup>Vascular Surgery, Dongsan Medical Center, Keimyung University School of Medicine, Daegu, Korea

**Background:** To assess the incidence of venous thromboembolism (VTE) following shoulder surgery and to evaluate the role of postoperative duplex ultrasonography.

**Methods:** The study comprised a total of 224 patients who underwent shoulder surgery, including 180 shoulder arthroscopic surgeries, 28 shoulder arthroplasties, and 16 plate fixations for proximal humerus fracture between January 2014 and December 2014. The mean age of patients was 59.0 years, and there were 81 men and 143 women. Clinical data, including body mass index, blood tests, metabolic work-up for liver and renal function, previous, and present medical history, were evaluated. Duplex ultrasonography in the operative arm was performed on 2 to 4 days after surgery.

**Results:** The overall incidence of VTE following shoulder surgery was 0.45% (1/224). One patient with open reduction and plate fixation for proximal humerus fracture had asymptomatic deep vein thrombosis that showed complete remission after anticoagulant medication during a 2-month period. Four patients had asymptomatic superficial cephalic vein thrombosis and complete remission without any treatment. There was no case of pulmonary embolism.

**Conclusions:** The incidence of VTE following shoulder surgery was extremely low in Asians. Duplex ultrasonography may be not considered a routine follow-up of shoulder surgery and can be selectively performed in high-risk or symptomatic patients for VTE.

(*Clin Shoulder Elbow* 2017;20(1):18-23)

**Key Words:** Shoulder; Surgery; Venous thromboembolism; Ultrasonography; Duplex

## Introduction

Venous thromboembolism (VTE), including deep vein thrombosis (DVT) and pulmonary embolism (PE), is a serious complication that is potentially life-threatening. For this reason, VTE prevention has been identified as a critical patient safety issue with medicolegal practice.<sup>1)</sup>

Although VTE following lower extremity orthopedic surgery is common and well-established for its prevalence, treatment, and prevention, VTE following shoulder surgeries, including arthroplasty, arthroscopy, or fracture stabilization, has been considered as an extremely rare complication.<sup>2)</sup> However, the exact incidence of VTE following shoulder surgery remains controversial.

Previous articles have reported variable incidence rates, ranging from <0.01% to 13% after shoulder surgery.<sup>3-11)</sup> According to a systematic review by Ojike et al.,<sup>8)</sup> the incidence of DVT after shoulder surgery was 0.24% and the incidence of PE was 0.11% with an overall incidence of VTE as 0.35%. Conversely, a recent prospective study by Willis et al.<sup>11)</sup> demonstrated that the incidence of DVT, confirmed by the Doppler ultrasonography, after shoulder arthroplasty was 13%, which was comparable to that after hip arthroplasty.

The low incidence rate of VTE following shoulder surgery is most likely underestimated because previously published reports have mostly been case reports or retrospective case series describing symptomatic DVT or PE.<sup>1,7,12-21)</sup> Saseedharan and Bhar-

**Received** June 28, 2016. **Revised** August 15, 2016. **Accepted** September 1, 2016.

**✉ Correspondence to:** Chul-Hyun Cho

Department of Orthopedic Surgery, Keimyung University Dongsan Medical Center, 56 Dalseong-ro, Jung-gu, Daegu 41931, Korea

**Tel:** +82-53-250-8160, **Fax:** +82-53-250-7205, **E-mail:** oscho5362@dsmc.or.kr

IRB approval (No. 2016-06-021).

**Financial support:** None. **Conflict of interests:** None.

gava<sup>10</sup>) asserted that a large number of upper extremity deep vein thrombosis (UEDVT) goes undetected because the problem is generally asymptomatic. Along with the increasing number of shoulder surgeries performed, reports of VTE after shoulder surgery have also increased, suggesting that those events are not as rare as initially thought.<sup>2,13</sup> In view of the exponential growth of shoulder surgeries, including shoulder arthroscopy, shoulder arthroplasty, and stabilization for proximal humerus fractures, we can expect an increase in the incidence of VTE.

The prompt recognition of DVT is important because patients may develop fatal PE.<sup>22</sup> Duplex ultrasonography is a useful tool to screen and diagnose extremity DVT. Recent studies have demonstrated the usefulness of duplex ultrasonography in detecting and locating preoperative or postoperative thrombosis.<sup>8,10,22,23</sup>

To date, most studies have been conducted using Western populations with respect to the incidence rate of VTE following shoulder surgery. There is no report on an Asian population. It is unknown how many silent or asymptomatic cases may have occurred during the early postoperative period in Asian populations.<sup>12</sup> Therefore, we conducted a pilot study to investigate the incidence of VTE following shoulder surgery in an Asian population. The purpose of this study was to assess the incidence of VTE following shoulder surgery and to evaluate the role of postoperative duplex ultrasonography.

## Methods

Between January 2014 and December 2014, a total of 224 patients who underwent shoulder surgery and postoperative duplex ultrasonography (Logiq E9; GE Healthcare, Milwaukee, WI, USA) were enrolled in this study. Shoulder surgery included shoulder arthroscopy in 180 cases, shoulder arthroplasty in 28 cases, and open reduction with plate fixation for proximal humerus fracture in 16 cases. Clavicle fractures, scapular fractures, acromioclavicular joint dislocation, and humerus shaft fractures were excluded. The mean age of patients was 59.0 years (range, 17–98 years), and there were 81 men and 143 women.

We checked the body mass index (BMI) and blood tests, including coagulation profile (fibrinogen levels, prothrombin time, and activated prothrombin time), white blood cell count, hemoglobin, and metabolic work-up for liver and renal functions. We also assessed the previous and present medical histories, including the presence of malignancy and use of anticoagulation agents. Twelve patients used anticoagulation agents, such as aspirin, clopidogrel, or disgren, due to medial comorbidities, including myocardial infarction, stroke, and arrhythmia. According to the instructions from a physicians, 8 patients stopped taking anticoagulation agents 3 or 5 days prior to the surgery, and 4 patients continued to take anticoagulation agents regardless of surgery.

All operative procedures were performed by a single surgeon. No perioperative DVT prophylaxes, such as anti-embolic stocking, pneumatic compression devices, or intraoperative heparin administration, were used. Wearing an abduction brace, all patients were engaged in a range-of-motion exercises of the elbow, wrist, and hand immediately following the surgery. From 1 week after surgery, passive range of motion exercise of the shoulder was initiated and individualized according to the disease entity.

To evaluate the incidence of postoperative VTE, all patients underwent duplex ultrasonography in the operative arm 2 to 4 days after the surgery. Duplex ultrasonographic examination was performed by an experienced sonographer certificated by the American Registry for Diagnostic Medical Sonography, and the results were interpreted by a vascular surgeon. The examination was performed with the patient in supine and arm abduction position, using a 4–14 MHz linear probe for the cephalic, basilic, and brachial vein, and using a 3–11 MHz linear probe for the axillar and subclavian vein. The presence, location, and nature of thrombosis was assessed and recorded. Positive findings of acute venous thrombosis include echogenic material in the lumen of the vein, incompressible vein walls with external transducer pressure, no detectable vein wall motion in the central veins according to the B-mode image, and color filling defect in a color Doppler ultrasonography.

## Results

The incidence of UEDVT following shoulder surgery was 0.45% (1/224). One patient who underwent open reduction and plate fixation for proximal humerus fracture had asymptomatic DVT in the brachial vein and complete remission after anti-coagulant medication within 2 months. Four patients—including 2 patients who underwent open reduction with plate fixation for proximal humerus fracture, 1 patient with hemiarthroplasty, and 1 patient with arthroscopic rotator cuff repair—had asymptomatic superficial cephalic vein thrombosis and complete remission without any further treatment. There was no case of PE.

### Case Series

#### 1) Patient 1

A 72-year-old right-hand-dominant woman presented with painful limitation of motion in the left shoulder. She fell down a flight of stairs, resulting in displaced proximal humerus fracture. Open reduction with plate fixation was performed 2 days after the initial trauma. She had diabetes mellitus and was on hypoglycemic agents. Her BMI was 21.3 kg/m<sup>2</sup>. There was no history of hematologic clotting or bleeding abnormalities. The laboratory findings were normal. The operative time was 75 minutes. Four days after the surgery, duplex ultrasonographic finding of the left upper extremity revealed acute brachial vein thrombosis. However, there was no symptom for DVT. She was treated with

rivaroxaban (Xarelto; Bayer Schering Pharma, Berlin, Germany) for 2 months and had complete remission on a follow-up duplex ultrasonography (Fig. 1).

### 2) Patient 2

A 63-year-old right-handed woman presented with painful limitation of motion in the right shoulder for 3 years. She had severe osteoarthritis of the shoulder with no response to a long-standing conservative treatment. She underwent hemiarthroplasty for osteoarthritis of the right shoulder. She had diabetes mellitus, chronic kidney disease, and congestive heart disease. Her BMI was 41.1 kg/m<sup>2</sup>. There was no history of hematologic clotting or bleeding abnormalities. The laboratory findings were

normal, except the serum creatinine level, which was 1.58. Four days after the surgery, duplex ultrasonographic finding of her upper extremity revealed right superficial cephalic vein thrombosis without symptoms (Fig. 2). We were under close observation for any symptoms without any medication. No complication for superficial vein thrombosis was found during the serial follow-up evaluation.

### 3) Patient 3

A 53-year-old right-handed man presented with pain and weakness in the right shoulder for 3 years. He had a massive rotator cuff tear with failed conservative treatment and underwent arthroscopic rotator cuff repair. His BMI was 31.0 kg/m<sup>2</sup>, without

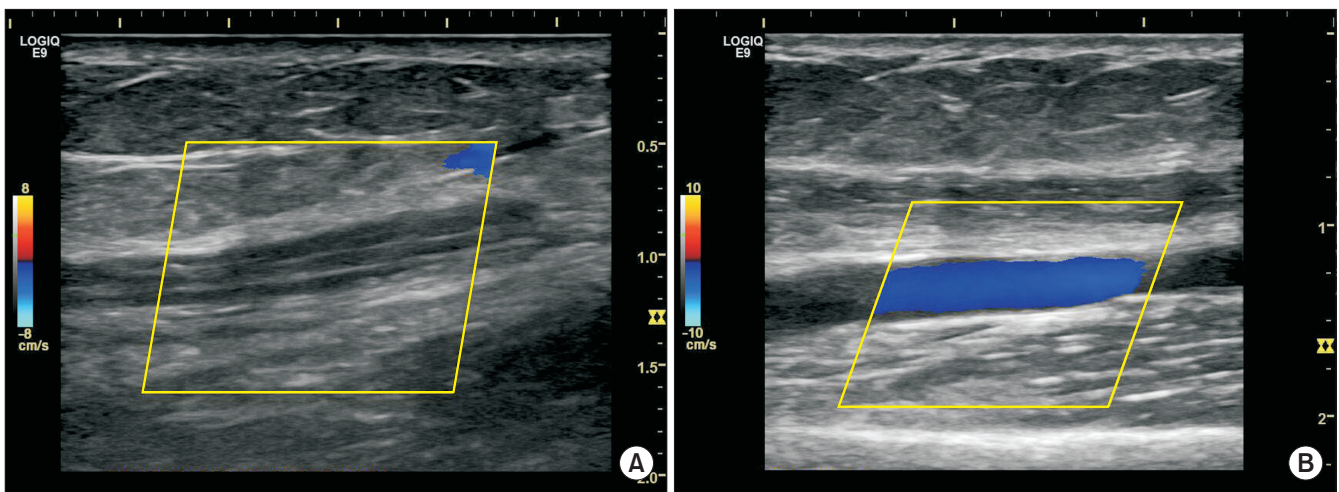


Fig. 1. Duplex ultrasonographic images from a 72-year-old woman who underwent open reduction and plate fixation for displaced proximal humerus fracture. (A) Longitudinal color Doppler image of the left brachial vein shows an expansile, hypoechoic thrombus, which implies an acute process. (B) The image shows no evidence of a thrombus after 2-month rivaroxaban treatment.

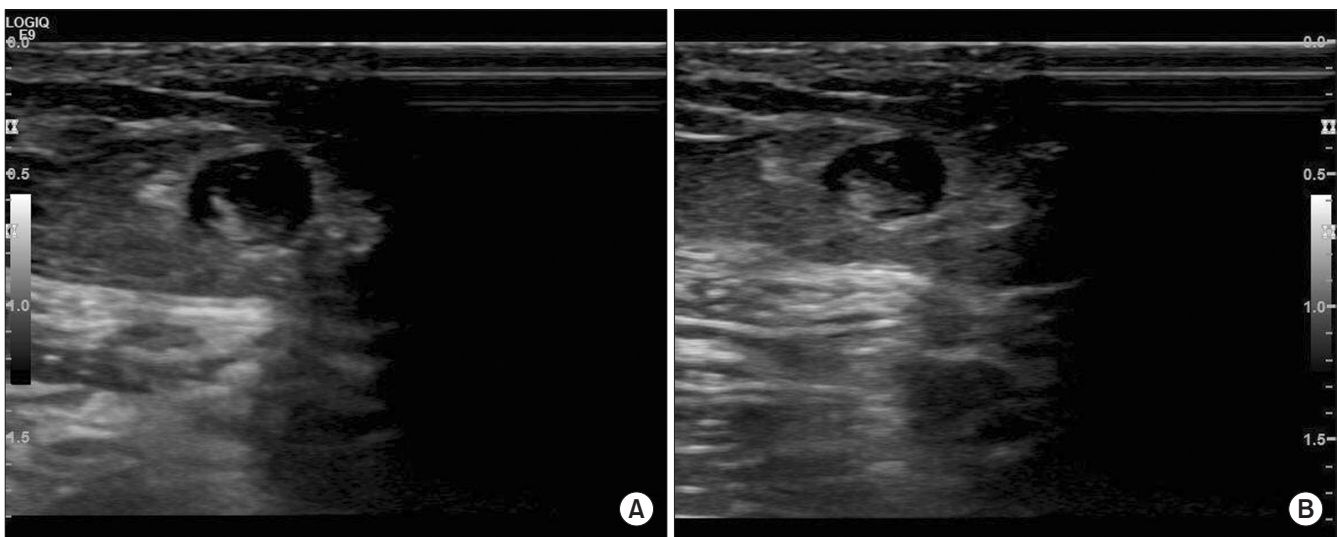


Fig. 2. Duplex ultrasonographic images from a 63-year-old woman who underwent hemiarthroplasty for osteoarthritis of the right shoulder. (A) Transverse image shows a thrombus within the right cephalic vein. (B) Transverse image shows that enlarged and tubular structure filled with thrombus is not compressible by the probe.



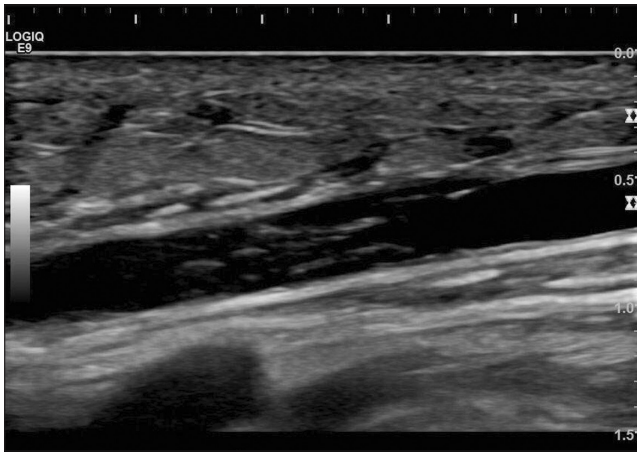


Fig. 3. Duplex ultrasonographic images from a 53-year-old man who underwent arthroscopic repair for massive rotator cuff tear of right shoulder. Longitudinal image of the right cephalic vein shows a hypoechoic thrombus.

any significant medical history. The laboratory findings were normal. Four days after the surgery, duplex ultrasonographic finding of his upper extremity revealed right superficial cephalic vein thrombosis without symptoms (Fig. 3). We were under close observation for any symptoms without any medication. No complication for superficial vein thrombosis was found during the serial follow-up evaluation.

## Discussion

The present study revealed that the incidence of VTE following shoulder surgery was 0.45% (1/224 cases) despite the prospectively collected cohort with postoperative duplex ultrasonographic screening. Our study is meaningful since, to the best of our knowledge, it is the first study to assess the incidence of VTE following shoulder surgery in an Asian population.

As shoulder surgeries, including arthroscopy, arthroplasty, and fracture stabilization, have been quickly increasing recently, interest in VTE has also been increasing. Although it is generally believed that VTE after shoulder surgery is very rare, there are increasing reports of DVT and PE associated with shoulder surgery.<sup>8)</sup> However, there is a large amount of variability in the incidence of VTE following shoulder surgery reported in the literature, which ranged widely from <0.01% to 13%.<sup>3-11)</sup> The lowest value represents VTE events with significant symptoms that required readmission for management, which have been typically reported in the retrospective studies. The highest value represents VTE events, including asymptomatic DVTs confirmed by Doppler ultrasonographic screening of all subjects in a prospective cohort study.

The incidence of DVT after shoulder arthroscopy was found to be between <0.01% and 0.38%. Jameson et al.<sup>5)</sup> reported that the incidence of DVT related to arthroscopic shoulder

surgery was less than 0.01%, and that the incidence of PE was also less than 0.1%. They concluded that VTE is not a significant problem after arthroscopic shoulder surgery, and prophylaxis may not be required even in high-risk patients. Conversely, Kuremsky et al.<sup>6)</sup> reported that postoperative DVT and PE after arthroscopic shoulder surgery may have potentially fatal consequences, with an incidence rate of 0.31% (6/1,908 cases). All patients required hospitalization and subsequent anticoagulation therapy. Hoxie et al.<sup>4)</sup> reported that the overall incidence of symptomatic PE following a rotator cuff repair was 0.26% (3/116 cases). They concluded that it should raise surgeons' awareness about this possible complication following rotator cuff repair.

Initially, it has been widely believed that the incidence rate of VTE after shoulder arthroplasty was approximately 0.01% to 0.52%. However, a recent study by Willis et al.<sup>11)</sup> demonstrated that the incidence of DVT confirmed by Doppler ultrasonography after shoulder arthroplasty was 13%, which is comparable to that after hip arthroplasty. They suggested that shoulder surgeons should be aware of the potential risk of perioperative thromboembolic complications in both acute and subacute postoperative periods. Patients having shoulder arthroplasty may be more prone to VTE due to increased dissection, extreme arm positioning, and blood loss.<sup>2)</sup>

According to the analysis of a United Kingdom database by Jameson et al.,<sup>5)</sup> the incidence rate of DVT and PE for proximal humerus fracture were 0.19% and 0.40%, respectively. They described that the VTE events after fracture surgery were more common than elective shoulder surgeries.

According to a systematic review by Dattani et al.,<sup>3)</sup> a total of 14 papers were available for analysis, most of which were retrospective studies and case series. They described that the incidence of VTE was 0.038% from 92,440 shoulder arthroscopic procedures, 0.52% from 42,261 shoulder replacements, and 0.64% from 4,833 procedures for proximal humerus fracture. However, they mentioned that this is an underestimate of the true rate given that many cases may go undiagnosed as they are asymptomatic or present with non-distinct symptoms.

In the current study, only 1 patient who underwent open reduction and plate fixation for proximal humerus fracture had asymptomatic DVT in the brachial vein. There was no case of VTE in the 180 cases with arthroscopic shoulder surgery and 28 cases with shoulder arthroplasty. Although our results cannot be generalized due to a small sample size, we showed that the incidence of VTE following shoulder surgery was extremely low in an Asian population. We had four cases with thrombosis of cephalic vein in the operative arm. However, we think that this is not meaningful because all cases had superficial venous thrombosis without any symptoms. Although the incidence of VTE was extremely low, surgeons should still be aware of the possibility for a serious complication in patients with shoulder surgery.

In up to one third of patients with UEDVT, symptomatic PE

may develop, which can be fatal.<sup>14)</sup> According to Di Nisio et al.,<sup>22)</sup> ultrasonography may most likely be the first choice to investigate UEDVT. A prospective study used Doppler ultrasonography after shoulder arthroplasty to identify a 4-limb prevalence of postoperative DVT, and it reported a DVT incidence of 13% and PE incidence of 3%.<sup>11)</sup> There has been no suggestion about the optimal timing of duplex sonographic screening for DVT after shoulder surgery. However, the hypercoagulable state after surgical injury continues for at most 48 hours, during which time, the occurrence of deep venous thrombosis will peak.<sup>24)</sup> Making a clear distinction between acute and chronic thrombosis in duplex ultrasonography is important. The vein is normally distended under low pressure and can be compressed easily with little pressure from the probe. If thrombus is present, the vein does not completely collapse with probe compression. In acute thrombus, the vein usually distends and thrombus exhibits a homogenous and hypochoic nature; whereas in chronic thrombus, the vein collapses and thrombus shows a heterogeneous and echogenic nature.

The general risk factors of VTE for the upper and lower extremities are similar, and include a history of VTE, old age, obesity, smoking, diabetes mellitus, history of malignancy, longer operative time, and venous stasis.<sup>1,2,6,8)</sup> Specific risk factors of developing DVT in the upper limbs are as follows: Presence of a central venous catheter, operating in the lateral decubitus position with the affected limb in traction, and interscalene block.<sup>1,7,13,14)</sup> Kuremsky et al.<sup>6)</sup> reported the presence of significant risk factors in 50% of patients developing DVT after shoulder arthroscopy. In our study, the patient with DVT had risk factors of old age and diabetes mellitus.

The current study has several limitations to consider when interpreting our results. First, our sample size was too small to claim strong evidence because this is a pilot study. Moreover, we were unable to assess the correlation with VTE and various factors. Second, this study had heterogeneity of the disease entity. Third, we did not have a work-up for lower extremity DVT. Further prospective large-scale multi-center studies are needed to determine the exact incidence, risk factor, and best strategy of VTE following shoulder surgery.

## Conclusion

The incidence of VTE following shoulder surgery was extremely low in an Asian population. Duplex ultrasonography may not be considered a routine procedure following shoulder surgery and can be selectively performed in high-risk or symptomatic patients for VTE.

## References

1. Anakwe RE, Middleton SD, Beresford-Cleary N, McEachan JE,

- Talwalkar SC. Preventing venous thromboembolism in elective upper limb surgery. *J Shoulder Elbow Surg.* 2013;22(3):432-8.
2. Saleh HE, Pennings AL, ElMaraghy AW. Venous thromboembolism after shoulder arthroplasty: a systematic review. *J Shoulder Elbow Surg.* 2013;22(10):1440-8.
3. Dattani R, Smith CD, Patel VR. The venous thromboembolic complications of shoulder and elbow surgery: a systematic review. *Bone Joint J.* 2013;95(1):70-4.
4. Hoxie SC, Sperling JW, Cofield RH. Pulmonary embolism following rotator cuff repair. *Int J Shoulder Surg.* 2008;2(3):49-51.
5. Jameson SS, James P, Howcroft DW, et al. Venous thromboembolic events are rare after shoulder surgery: analysis of a national database. *J Shoulder Elbow Surg.* 2011;20(5):764-70.
6. Kuremsky MA, Cain EL Jr, Fleischli JE. Thromboembolic phenomena after arthroscopic shoulder surgery. *Arthroscopy.* 2011;27(12):1614-9.
7. Manaqibwala MI, Ghobrial IE, Curtis AS. Upper extremity thrombosis presenting as medial elbow pain after shoulder arthroscopy. *Case Rep Orthop.* 2014;2014:653146.
8. Ojike NI, Bhadra AK, Giannoudis PV, Roberts CS. Venous thromboembolism in shoulder surgery: a systematic review. *Acta Orthop Belg.* 2011;77(3):281-9.
9. Randelli P, Castagna A, Cabitza F, Cabitza P, Arrigoni P, Denti M. Infectious and thromboembolic complications of arthroscopic shoulder surgery. *J Shoulder Elbow Surg.* 2010;19(1):97-101.
10. Saseedharan S, Bhargava S. Upper extremity deep vein thrombosis. *Int J Crit Illn Inj Sci.* 2012;2(1):21-6.
11. Willis AA, Warren RF, Craig EV, et al. Deep vein thrombosis after reconstructive shoulder arthroplasty: a prospective observational study. *J Shoulder Elbow Surg.* 2009;18(1):100-6.
12. Bongiovanni SL, Ranalletta M, Guala A, Maignon GD. Case reports: heritable thrombophilia associated with deep venous thrombosis after shoulder arthroscopy. *Clin Orthop Relat Res.* 2009;467(8):2196-9.
13. Cortés ZE, Hammerman SM, Gartsman GM. Pulmonary embolism after shoulder arthroscopy: could patient positioning and traction make a difference? *J Shoulder Elbow Surg.* 2007;16(2):e16-7.
14. Creighton RA, Cole BJ. Upper extremity deep venous thrombosis after shoulder arthroscopy: a case report. *J Shoulder Elbow Surg.* 2007;16(1):e20-2.
15. Edgar R, Nagda S, Huffman R, Namdari S. Pulmonary embolism after shoulder arthroscopy. *Orthopedics.* 2012;35(11):e1673-6.
16. Garofalo R, Notarnicola A, Moretti L, Moretti B, Marini S, Castagna A. Deep vein thromboembolism after arthroscopy of the shoulder: two case reports and a review of the literature. *BMC Musculoskelet Disord.* 2010;11:65.
17. Hariiri A, Nourissat G, Dumontier C, Doursounian L. Pulmonary embolism following thrombosis of the brachial vein after shoulder arthroscopy. A case report. *Orthop Traumatol Surg*

- Res. 2009;95(5):377-9.
18. Kang S, Chung PH, Kim JP, Kim YS, Lee HM, Jang HG. Pulmonary embolism after screw fixation for a greater tubercle fracture of humerus. *Clin Should Elbow*. 2014;17(4):201-4.
  19. Gwark JY, Koh JS, Park HB. Pulmonary embolism after arthroscopic rotator cuff repair: a case report. *Clin Should Elbow*. 2014;17(1):31-5.
  20. Kim SJ, Yoo KY, Lee HC, Kim WM, Jeong CW, Lee HJ. Fatal pulmonary embolism caused by thrombosis of contralateral axillary vein after arthroscopic right rotator cuff repair: A case report. *Korean J Anesthesiol*. 2010;59 Suppl:S172-5.
  21. Yamamoto T, Tamai K, Akutsu M, Tomizawa K, Sukegawa T, Nohara Y. Pulmonary embolism after arthroscopic rotator cuff repair: a case report. *Case Rep Orthop*. 2013;2013:801752.
  22. Di Nisio M, Van Sluis GL, Bossuyt PM, Büller HR, Porreca E, Rutjes AW. Accuracy of diagnostic tests for clinically suspected upper extremity deep vein thrombosis: a systematic review. *J Thromb Haemost*. 2010;8(4):684-92.
  23. Chin EE, Zimmerman PT, Grant EG. Sonographic evaluation of upper extremity deep venous thrombosis. *J Ultrasound Med*. 2005;24(6):829-38; quiz 839-40.
  24. Sun Y, Chen D, Xu Z, et al. Incidence of symptomatic and asymptomatic venous thromboembolism after elective knee arthroscopic surgery: a retrospective study with routinely applied venography. *Arthroscopy*. 2014;30(7):818-22.