



# Use of polyaryletherketone (PAEK) based polymer for implant-supported telescopic overdenture: A case report

Chan Park, Dae-Jeon Jun, Sang-Won Park, Hyun-Pil Lim\*

Department of Prosthodontics, School of Dentistry, Chonnam National University, Gwangju, Republic of Korea

Although many prosthetic materials exist for fabrication of implant-supported telescopic overdentures, available materials have not been thoroughly evaluated from a functional standpoint. This case report describes the use of polyaryletherketone (PAEK) based polymer for an implant-supported telescopic overdenture, a seldom used material in dentistry. This material is lighter than traditional materials, can accommodate changes in retentive forces, and is an easily retrievable by CAD/CAM fabrication. This case highlights the possibility of using new polymer materials for implant-supported telescopic overdentures. [*J Adv Prosthodont 2017;9:74-6*]

**KEYWORDS:** Polymer; Polyaryletherketone (PAEK); Implant overdenture; Telescopic abutment

## INTRODUCTION

Implant-supported overdenture treatment is very useful for patients undergoing full mouth rehabilitation. Implant-supported overdenture prostheses can be divided into bar overdentures and single attachment overdentures. Single attachment elements for overdentures include single retentive anchors, single magnet anchors, and individually cast telescopic copings.<sup>1</sup> Among these, telescopic copings have the benefit of implant splinting found in bar overdentures and the retrievability of single attachment overdentures. However, this method is typically fabricated using gold materials, so it is not an economical treatment option. Also, if an inner crown will be worn, it is difficult to maintain appropriate retentive forces.

In this case report, a telescopic implant-supported overdenture prosthesis was made using a new material, poly-

aryletherketone (PAEK) based polymer (Pekkton ivory, Cendres + Métaux SA, Biel/Bienne, Switzerland). It shares benefits of typical telescopic coping, in addition to being highly economical, wear resistant, and light in weight compared to conventional implant overdenture prostheses.

## CASE REPORT

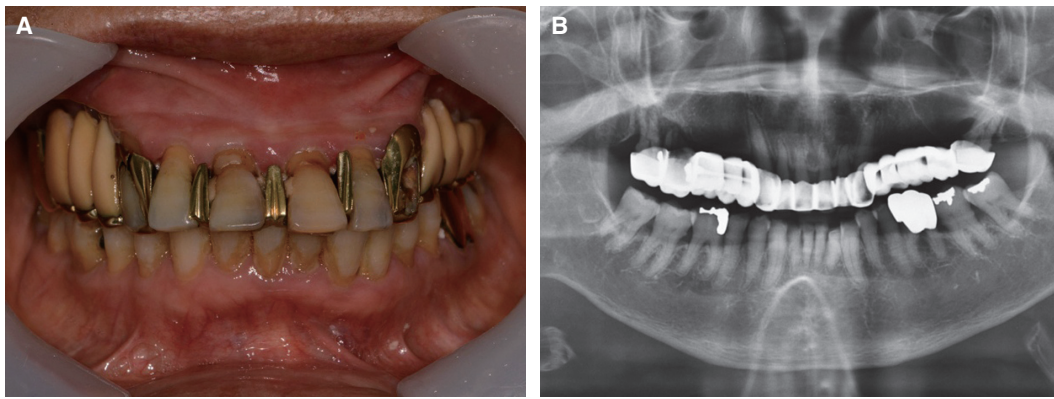
A 79-year-old woman with mobile maxillary dentition and caries (Fig. 1) presented to the Department of Prosthodontics at Chonnam National University Dental Hospital. After clinical and radiographic examinations, maxillary full mouth rehabilitation was planned to improve esthetics and functional oral health.

After maxillary teeth extractions and use of provisional maxillary complete denture for six months, six small diameter implant fixtures (3.0 × 10.0 mm USII, Osstem implant Co. Ltd., Seoul, Korea) were installed due to insufficient bone width (Fig. 2A). The definitive prosthesis was planned as a telescopic overdenture using PAEK based polymer.

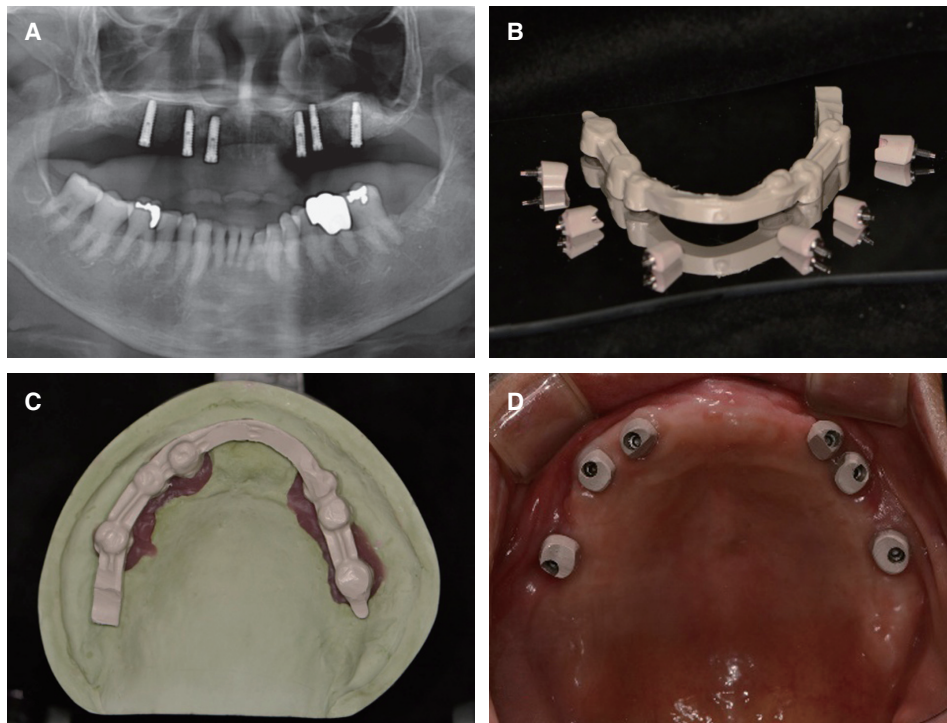
After a making definitive impression by polyvinylsiloxane (Honigum, DMG, Hamburg, Germany), a polymer telescopic abutment and an outer overdenture frame were fabricated with consideration of the patient's vertical dimension (Fig. 2B, Fig. 2C). Telescopic abutment and framework design were laid out by CAD software (Exocad dental CAD, exocad GmbH, Darmstadt, Germany). The milling machine (S1, vhf camfacture AG, Ammerbuch, Germany) made the final framework and abutment according to the design.

Corresponding author:  
Hyun-Pil Lim  
Department of Prosthodontics, School of Dentistry, Chonnam National University, 33 Yongbong-ro, Buk-gu, Gwangju 61186, Republic of Korea  
Tel. +82625305638; e-mail, mcnihil@jnu.ac.kr  
Received May 25, 2016 / Last Revision November 30, 2016 / Accepted December 20, 2016

© 2017 The Korean Academy of Prosthodontics  
This is an Open Access article distributed under the terms of the Creative Commons Attribution Non-Commercial License (<http://creativecommons.org/licenses/by-nc/3.0>) which permits unrestricted non-commercial use, distribution, and reproduction in any medium, provided the original work is properly cited.

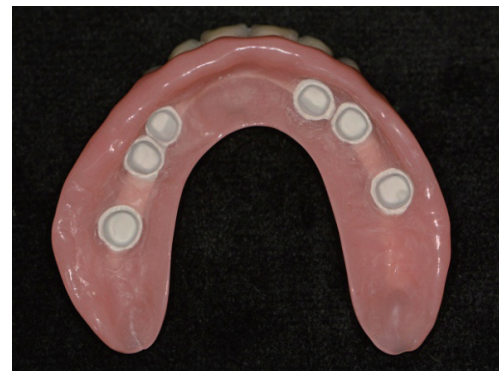

**Fig. 1.** (A) Pretreatment intraoral frontal view, (B) Panoramic radiograph before treatment.

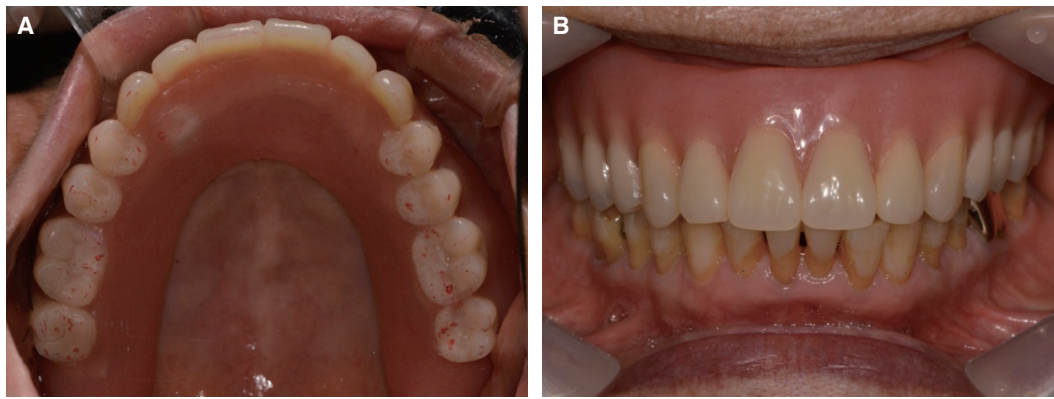

**Fig. 2.** (A) Panoramic radiograph after implant installation, (B) Polymer telescopic abutment and overdenture bar frame, (C) Polymer prosthesis on master cast, (D) Polymer abutment try in.

Polymer abutment and titanium link were sandblasted by 110 um grit aluminum oxide, and bonded with primer (SR link, Ivoclar Vivadent, Schaan, Liechtenstein) and bonding agent (Multilink N, Ivoclar Vivadent, Schaan, Liechtenstein). After that, the definitive prosthesis was made by auto-polymerized pour-type resin (Press LT, Retec, Rosbach, Germany) (Fig. 3). The telescopic overdenture was fitted intraorally (Fig. 4); the design and weight of the prosthesis were adjusted to achieve acceptable esthetics and phonetics. After 6 months, there were no problems with alveolar bone around the implant fixtures and retention of the overdenture prosthesis.



**Fig. 3.** Definitive implant-supported overdenture by polymer (inner side).



**Fig. 4.** (A) Implant-supported overdenture try in (occlusal view), (B) Implant-supported overdenture try in (frontal view).

## DISCUSSION

A previous report<sup>2</sup> has discussed implant overdenture types and materials for successful treatment. However, no treatment modality meets all criteria for successful treatment, and conventional overdenture material can sometimes be limited by economic, functional, and technical considerations. Now, many new prosthetic materials are available to overcome these limitations, and as in this case, a new polymer can be used to make telescopic crowns and frameworks to obtain satisfactory results.

PAEK based polymer, Pekkton ivory, as used in this case, is a member of the high performance semi-crystalline thermoplastic resin group, recognized for its keto and ether group ratio. PAEK has good dimensional stability at high temperature, high chemical and mechanical resistance against wear, and high tensile, fatigue and flexural strength, making it an attractive material with expanded uses in medicine and dentistry.<sup>3</sup> However, PEEK (polyetheretherketone), a conventional PAEK-based polymer, cannot be used as a permanent material due to its relatively weak physical properties. A new material, Pekkton, is mainly composed of PEKK (polyetherketoneketone); its molecular structure has an added ketone to the structure of PEEK with and has a wide range of uses due to its amorphous and crystalline structure. PEKK reveals up to 80% greater compressive strengths than PEEK, so this polymer may be used in permanent prostheses according to the manufacturer.<sup>4</sup> Thus, this new polymer can be considered to have greater strength than PEEK and have greater esthetics titanium, higher resin bond strength than zirconia, and a lighter weight (1.4 g/cm<sup>3</sup>) than metal. Therefore, this material is found to be mechanically suitable for FPD frameworks, milled overdenture bars, clasps, telescopic crowns, and other applications. Despite the reportedly good bond strength, bonding between the titanium link and the telescopic abutment is still very sensitive, with the risk of fracture of the thin abutment wall due to connecting titanium link; hence more studies are needed on such cases.

The patient was monitored following delivery of the

prosthesis. She reported satisfaction with its strength and esthetics, and no negative symptoms. Due to the lack of evidence on the long term retentive capabilities of this material, continuous follow up would be beneficial.

## CONCLUSION

Due to its functional and economic advantages, PAEK based polymer is a good alternative material to conventional materials and methods in the fabrication of implant overdenture.

## ACKNOWLEDGEMENTS

The authors thank the Young-Chul Cho, Vision Dental Lab, for making implant-supported telescopic overdenture using PAEK based polymer.

## ORCID

Chan Park <http://orcid.org/0000-0001-5729-5127>

Dae-Jeon Jun <http://orcid.org/0000-0001-6991-0262>

Sang-Won Park <http://orcid.org/0000-0002-9376-9104>

Hyun-Pil Lim <http://orcid.org/0000-0001-5586-1404>

## REFERENCES

1. Zarb GA, Hobkirk J, Eckert S, Jacob R. Prosthodontic treatment for edentulous patients: complete dentures and implant-supported prostheses. 12th ed. St. Louis: Elsevier; 2004.
2. Zarb GA, Schmitt A. The edentulous predicament. II: The longitudinal effectiveness of implant-supported overdentures. *J Am Dent Assoc* 1996;127:66-72.
3. Passia N, Ghazal M, Kern M. Long-term retention behaviour of resin matrix attachment systems for overdentures. *J Mech Behav Biomed Mater* 2016;57:88-94.
4. Fuhrmann G, Steiner M, Freitag-Wolf S, Kern M. Resin bonding to three types of polyaryletherketones (PAEKs)-durability and influence of surface conditioning. *Dent Mater* 2014;30:357-63.