

Correlation between Optic Nerve Sheath Diameter Measured by Computed Tomography and Elevated Intracranial Pressure in Patients with Traumatic Brain Injury

Tae Kyo Lim, M.D., Byug Chul Yu, M.D., Dae Sung Ma, M.D., Gil Jae Lee, M.D., Min A Lee, M.D., Sung Yeol Hyun, M.D., Ph.D, Yang Bin Jeon, M.D., Ph.D, Kang Kook Choi, M.D.

Department of Traumatology, Gachon University Gil Medical Center, Incheon, Korea

Received: November 27, 2017

Revised: December 14, 2017

Accepted: December 17, 2017

Correspondence to

Kang Kook Choi, M.D.

Department of Traumatology, Gachon University Gil Medical Center, 21 Namdong-daero 774beon-gil, Namdong-gu, Incheon 21565, Korea
Tel: +82-32-460-3010
Fax: +82-32-460-2372
E-mail: choikangkook@gilhospital.com

Purpose: The optic nerve sheath diameter (ONSD) measured by ultrasonography is among the indicators of intracranial pressure (ICP) elevation. However, whether ONSD measurement is useful for initial treatment remains controversial. Thus, this study aimed to investigate the relationship between ONSD measured by computed tomography (CT) and ICP in patients with traumatic brain injury (TBI).

Methods: A total of 246 patients with severe trauma from January 1, 2015 until December 31, 2015 were included in the study. A total of 179 patients with brain damage with potential for ICP elevation were included in the TBI group. The remaining 67 patients comprised the non-TBI group. A comparison was made between the two groups. Receiver operating characteristic (ROC) curve analysis was performed to determine the accuracy of ONSD when used as a screening test for the TBI group including those with TBI with midline shift (with elevated ICP).

Results: The mean injury severity score (ISS) and glasgow coma scale (GCS) of all patients were 24.2 ± 6.1 and 5.4 ± 0.8 , respectively. The mean ONSD of the TBI group (5.5 ± 1.0 mm) was higher than that of the non-TBI group (4.7 ± 0.6 mm). Some significant differences in age (55.3 ± 18.1 vs. 49.0 ± 14.8 , $p < 0.001$), GCS (11.7 ± 4.1 versus 13.3 ± 3.0 , $p < 0.001$), and ONSD (5.5 ± 1.0 vs. 4.7 ± 0.6 , $p < 0.001$) were observed between the TBI and the non-TBI group. An ROC analysis was used to assess the correlation between TBI and ONSD. Results showed an area under the ROC curve (AUC) value of 0.752. The same analysis was used in the TBI with midline shift group, which showed an AUC of 0.912.

Conclusions: An ONSD of >5.5 mm, measured on CT, is a good indicator of ICP elevation. However, since an ONSD is not sensitive enough to detect an increased ICP, it should only be used as one of the parameters in detecting ICP along with other screening tests.

Keywords: Traumatic brain injury; Intracranial pressure; Optic nerve

INTRODUCTION

Intracranial pressure (ICP) is one of the important indicators of traumatic brain injury (TBI) or altered mental status in patients admitted to the initial trauma department. Patients with elevated ICP may require interventional therapy as it can lead to poor outcomes [1,2]. However, a neurologic exam has a limited capacity to detect ICP elevation as multiple injuries, sedation including a drunken state, or paralysis may occur during pre-hospital care [3]. A brain computer tomography (CT) is the best examination in detecting intracranial lesions after TBI. However, CT is not used in patients with unstable vital signs, if it delays the transport of patients to an advanced hospital, and in patients without acute hemorrhage [4].

The optic nerve sheath diameter (ONSD) is among the indicators of elevated ICP. Several studies in Western countries have reported a correlation between ONSD and ICP [5-9].

This study aimed to determine the relationship between ONSD measured by CT and ICP elevation in patients with TBI.

METHODS

This study included 509 patients with injury severity score

(ISS) of 15 or higher who visited the trauma center from January 1, 2015 until December 31, 2015. Of the 509 patients who underwent CT scan, 354 had injuries on the brain, chest, and abdomen. Patients below 18 years old whose growth was not physically terminated were excluded from this study. Patients with suspected orbital injury and brain lesions other than trauma were also excluded (Fig. 1).

Two hundred forty-six patients included in present study were classified into two groups: TBI group and non-TBI group. The TBI group comprised patients with extra-axial or intra-axial hematoma as determined by the abbreviated injury scale (AIS), the non-TBI group included patients without TBI as determined by the AIS (Fig. 1). For identifying ONSD changes as ICP increases, we also classified TBI group into elevated ICP group and non-elevated ICP group. Elevated ICP group included patients with TBI plus midline-shifting, and the remaining patients were classified as non-elevated ICP group. We excluded 82 patients diagnosed TBI without mass-effect such as diffuse axonal injury, concussion or traumatic subarachnoid hemorrhage. Because these patients usually do not have elevated intracranial pressure and often have conservative treatment even if they have symptoms (Fig. 1).

We retrospectively collected the following patient characteristics: age, gender, ISS, GCS, and mortality. Brain CT was performed via 3 mm thickness-helical scan. The

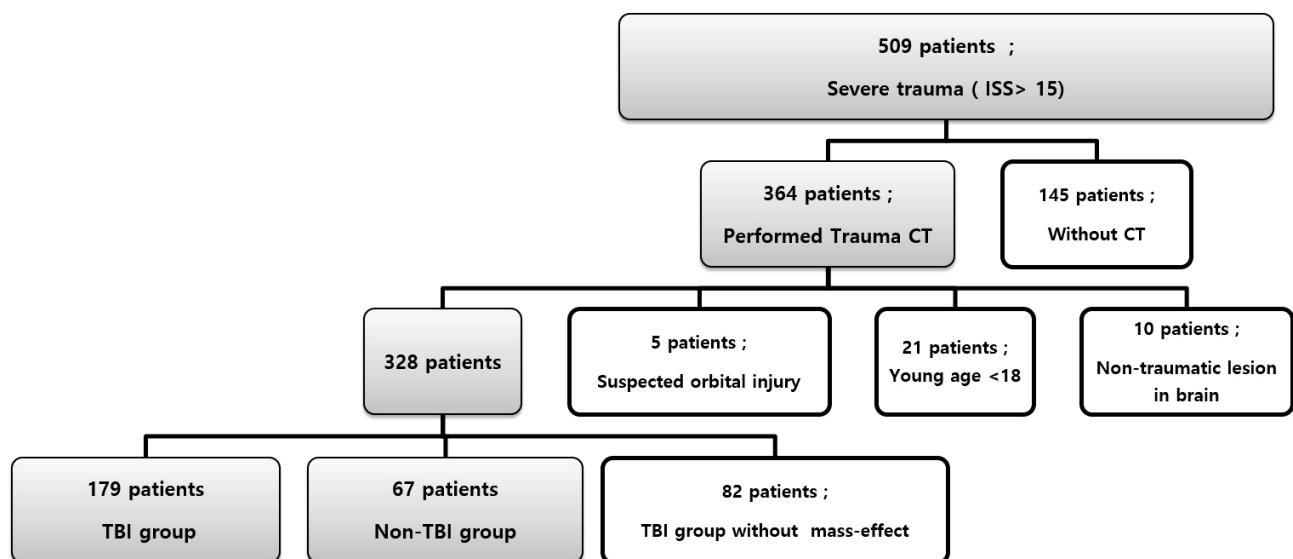


Fig. 1. Selection of patients in the present study. ISS: injury severity score, CT: computed tomography, TBI: traumatic brain injury.

scan angle was set parallel to the skull base line and the scan range was from top of C1 lamina to top of calvarium. We estimated the diameter of the midline shift and the amount of hematoma using the ABC/2 estimation technique in the CT image. The ONSD was measured at 3 mm behind the optic globe in the CT scan (Fig. 2).

A statistical analysis was performed using the IBM SPSS Statistics ver. 20.0 (IBM Corp., Somers, NY, USA). The characteristics of both groups were compared using a student's *t*-test, and a *p* value of <0.05 denotes a statistical difference. Receiver operating characteristic (ROC) curve analysis was used to determine the correlation between ONSD and TBI or TBI with midline shift.

RESULTS

In this study, 182 of the 246 patients were males. The mean age was 54.06±14.05 years, while the mean ISS and GCS were 24.2±6.1 and 5.4±0.8 respectively (Table 1). SDH was the most common diagnosis among patients with TBI. The mean OSND of all patients was 5.4±0.8 (16.3%). The mortality rate of all patients was 16.2%. The age (55.3±18.1 vs. 49.0±14.8 years, *p*<0.001), GCS (11.7±4.1 vs. 13.3±3.0, *p*<0.001), and ONSD (5.5±1.0 vs.

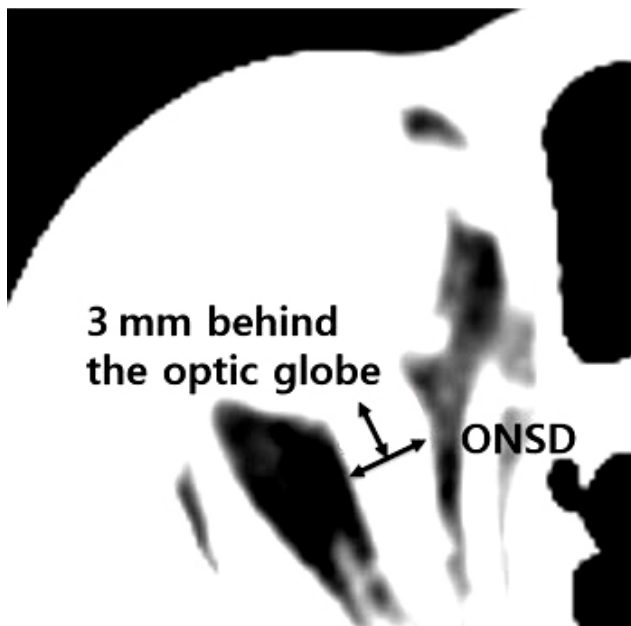


Fig. 2. Method of measuring ONSD in CT. ONSD: optic nerve sheath diameter, CT: computed tomography.

4.7±0.6, *p*<0.001) did not differ significantly between the TBI and the non TBI group (Table 2). There was no significant difference in sex ratio, mean ISS, and mortality between the two groups.

The ROC analysis revealed a correlation between TBI and ONSD, with an area under the ROC curve (AUC) value of 0.752 (Fig. 3). Therefore, TBI with a sensitivity of 46.9% and a specificity of 88% indicates that ICP increas-

Table 1. Patient characteristic in the present study

Patient characteristics	Value
Sex	
Male	182
Female	64
Age (years)	54.06±14.05
ISS	24.2±6.1
GCS	5.4±0.8
Diagnosis	
SDH	102
EDH	61
Hemorrhagic contusion	12
ICH	4
Non-TBI trauma	67
ONSD (mm)	5.3±0.8
No. of deaths	40

Values are presented as number or mean±standard deviation. ISS: injury severity score, GCS: glasgow coma scale, SDH: subdural hematoma, EDH: epidural hematoma, ICH: intracerebral hemorrhage, TBI: traumatic brain injury, ONSD: optic nerve sheath diameter.

Table 2. Comparison between TBI group and non-TBI group

	TBI (n=179)	Non-TBI (n=67)	<i>p</i> -value
Sex			0.57
Male	135	47	
Female	44	20	
Age (year)	55.3±18.1	49.0±14.8	0.001 ^a
ISS	24.7±8.0	23.2±8.5	0.12
GCS	11.7±4.1	13.3±3.0	0.001 ^a
Mortality	31 (17.3)	9 (9.8)	0.072
ONSD (mm)	5.5±1.0	4.7±0.6	< 0.001 ^a

Values are presented as number (%) or mean±standard deviation. TBI: traumatic brain injury, ISS: injury severity score, GCS: Glasgow coma scale, ONSD: optic nerve sheath diameter.

^a*p*<0.05.

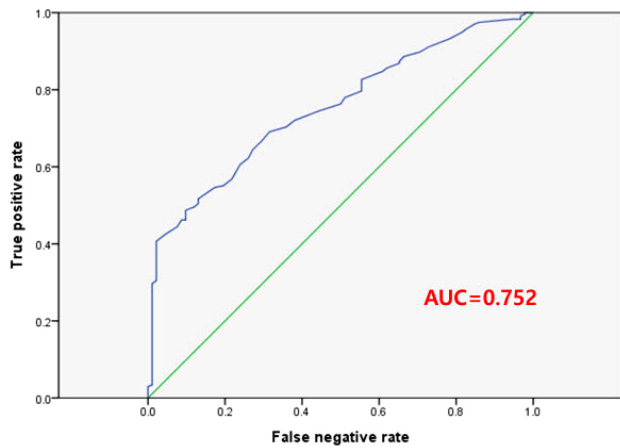


Fig. 3. ROC curve for ability of ONSD to determine TBI suspected of ICP elevation. ROC: receiver operating characteristic, ONSD: optic nerve sheath diameter, TBI: traumatic brain injury, ICP: intracranial pressure, AUC: area under the ROC curve.

es when ONSD is 5.5 mm or higher. These results suggested that the ONSD measurement is not highly relevant to the TBI group. An ROC curve was used to analyze the correlation between TBI group and those with midline shift seen on CT scans. Results revealed an AUC of 0.912 (Fig. 4). When the ONSD was 5.5 mm or higher, TBI with midline shift was shown to have a sensitivity of 89.9% and specificity of 80%. Therefore, ONSD is a good indicator of midline shift in patients with TBI.

DISCUSSION

Patients with severe trauma with TBI usually have high mortality and morbidity rates [1,2]. Patients with severe trauma often experience loss of consciousness due to unstable vital signs, are placed on a sedative state, or suffer from brain injury at initial treatment [9]. Therefore, patients with severe trauma should be evaluated for traumatic brain injury. A brain computer tomography is the gold standard for evaluation of traumatic brain injury. However, a CT scan is not used in patients with unstable vital signs, if it delays the transport of patients, and in mass casualty incidents [10]. Thus, a bedside procedure to identify a brain injury that can lead to elevated ICP may be useful in some situations.

The ultrasonographic measurement of the ONSD can

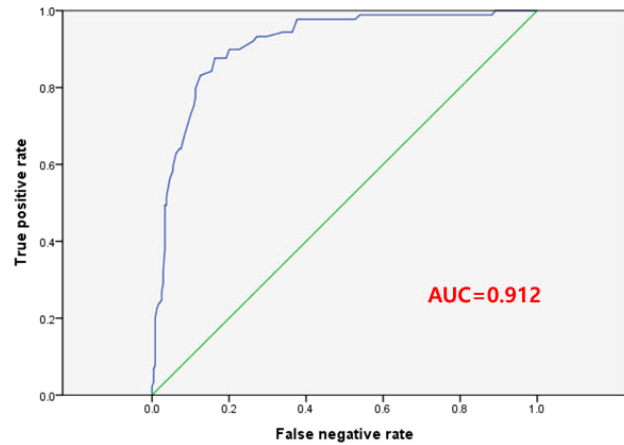


Fig. 4. ROC curve for ability of ONSD to determine TBI with midline shift. ROC: receiver operating characteristic, ONSD: optic nerve sheath diameter, TBI: traumatic brain injury, AUC: area under the ROC curve.

be performed at the patient's bedside; several studies have reported the association between ICP and ONSD [5-9]. Previous studies revealed that ONSD increases to >5 mm on ultrasonography if the ICP increases by >20 mmHg or a lesion develops which can trigger ICP elevation. According to Geeraerts et al., the ONSD in patients with TBI with an elevated ICP was 6.3 ± 0.6 , which was 1 mm higher than the ONSD in patients with normal ICP [11]. On the other hand, Strumwasser et al. reported a weak correlation between ICP elevation and ONSD based on the results of the ROC analysis (AUC=0.36) [12]. Considering the results of the previous studies, the correlation between ONSD measured by ultrasonography and elevated ICP remains controversial.

Thus, this study aimed to examine the association between ONSD measured on CT and TBI. The results of this study may be necessary in the treatment of patients with TBI with elevated ICP as the ultrasound measurement of ONSD may be inaccurate based on how it was performed. The TBI group had a mean ONSD value of 5.5 ± 1.0 . In the TBI with midline shift group, the ROC curve analysis showed a correlation between brain herniation and ONSD, with an AUC of 0.912. The results of the present study and the previous studies suggested that the ONSD increases to 5.5 mm as the ICP increases.

ICP elevation is difficult to detect in patients with trauma during initial treatment. Symptoms such as headache, papilloedema, and vomiting are indicative of elevated

ICP. However, the degree of the above symptoms and elevations in ICP are not related [6]. Changes in the blood pressure and pulse rate and an abnormal respiratory pattern occur in the later stages of elevated ICP due to brainstem compression [13]. The deterioration of consciousness based on the patient's GCS is linked to the gradual elevation of ICP [14]. However, in the case of patients with severe trauma, the level of consciousness remains decreased even if TBI is not severe [3]. In this study, ONSD might be a less useful screening test to detect ICP elevation during initial treatment. Based on the results of the ROC analysis in the TBI group, an ONSD of 5.5 mm or more yielded a sensitivity of 46.9%. Therefore, ONSD should be used as one of the parameters in detecting ICP elevation during the initial treatment of patients with severe trauma as it is not useful in ICP monitoring or checking patient's level of consciousness.

This study has several limitations. As we measured ONSD on initial brain CT, we could not confirm the ICP value of patients who were diagnosed with TBI. Also, we could not control all variable biases because it was a retrospective study. However, this result is considered valid since there are sufficient number of cases and measuring ONSD by CT is less deviations according to performer than ultrasonographical measurement.

CONCLUSION

Our findings indicate that the ONSD measured via CT increases to 5.5 mm or more with a clear increase in ICP. However, ONSD is not likely to be useful in screening tests. Therefore, ONSD should be used as one of the parameters when the conventional method for ascertaining ICP elevation cannot be used in the initial treatment of patients with severe trauma.

REFERENCES

1. Becker DP, Miller JD, Ward JD, Greenberg RP, Young HE, Sakalas R. The outcome from severe head injury with early diagnosis and intensive management. *J Neurosurg* 1977;47:491-502.

2. Marshall LF, Smith RW, Shapiro HM. The outcome with aggressive treatment in severe head injuries. Part II: acute and chronic barbiturate administration in the management of head injury. *J Neurosurg* 1979;50:26-30.
3. Bullock RM, Chesnut RM, Clifton GL. Initial management. *J Neurotrauma* 2000;17:463-9.
4. Goel RS, Goyal NK, Dharap SB, Kumar M, Gore MA. Utility of optic nerve ultrasonography in head injury. *Injury* 2008;39:519-24.
5. Galetta S, Byrne SF, Smith JL. Echographic correlation of optic nerve sheath size and cerebrospinal fluid pressure. *J Clin Neuroophthalmol* 1989;9:79-82.
6. Hansen HC, Helmke K. Validation of the optic nerve sheath response to changing cerebrospinal fluid pressure: ultrasound findings during intrathecal infusion tests. *J Neurosurg* 1997;87:34-40.
7. Helmke K, Hansen HC. Fundamentals of transorbital sonographic evaluation of optic nerve sheath expansion under intracranial hypertension. I. Experimental study. *Pediatr Radiol* 1996;26:701-5.
8. Helmke K, Hansen HC. Fundamentals of transorbital sonographic evaluation of optic nerve sheath expansion under intracranial hypertension. II. Patient study. *Pediatr Radiol* 1996;26:706-10.
9. Blaivas M, Theodoro D, Sierzenski PR. Elevated intracranial pressure detected by bedside emergency ultrasonography of the optic nerve sheath. *Acad Emerg Med* 2003;10:376-81.
10. The Brain Trauma Foundation. The American Association for Neurological Surgeons. The Joint Section on Neurotrauma and Critical Care. Trauma systems. *J Neurotrauma* 2000;17:457-62.
11. Geeraerts T, Launey Y, Martin L, Pottecher J, Vigué B, Duran-teau J, et al. Ultrasonography of the optic nerve sheath may be useful for detecting raised intracranial pressure after severe brain injury. *Intensive Care Med* 2007;33:1704-11.
12. Strumwasser A, Kwan RO, Yeung L, Miraflor E, Ereso A, Castro-Moure F, et al. Sonographic optic nerve sheath diameter as an estimate of intracranial pressure in adult trauma. *J Surg Res* 2011;170:265-71.
13. Ritter AM, Muizelaar JP, Barnes T, Choi S, Fatouros P, Ward J, et al. Brain stem blood flow, pupillary response, and outcome in patients with severe head injuries. *Neurosurgery* 1999;44:941-8.
14. Dunn IT. Raised intracranial pressure. *J Neurol Neurosurg Psychiatry* 2002;73Suppl 1:i23-7.