

<Case Report>

Congenital mitral valve stenosis in a Chinchilla cat

Ta-Li Lu¹, Yong-Wei Hung¹, Ran Choi², Changbaig Hyun^{2,*}

¹Cardiospecial Veterinary Hospital, Taipei 10662, Taiwan

²Section of Small Animal Internal Medicine, College of Veterinary Medicine, Kangwon National University, Chuncheon 24341, Korea

(Received: April 13, 2016; Revised: June 8, 2016; Accepted: July 6, 2016)

Abstract: A one-year-old, 3.25 kg intact male Chinchilla cat presented with acute right hind limb paralysis. Diagnostic imaging studies found cardiomegaly with interstitial lung pattern, abnormal mitral valve leaflets without maximum opening at the end of the ventricular diastole and during atrial systole and severe mitral inflow obstruction. Based on these findings and its young age, the case was diagnosed as congenital mitral valve stenosis. Treatment was directed to stabilize clinical conditions related to heart failure, to prevent further formation of thrombus and to relieve pain associated with thromboembolism. After one month of therapy, hind limb motor function was fully recovered.

Keywords: cats, flat E-F slope, inflow jet, mitral stenosis, pulmonary hypertension

Congenital mitral valve stenosis (MS) in cats is a rare heart disease characterized by a narrowed mitral valve orifice and progressive left atrial (LA) dilation due to increased pressure gradient across the mitral valvular annulus [1, 2]. Acquired MS has been also reported in cats with bacterial myocarditis [8], although this type is always associated with rheumatic fever in humans [2, 5].

A one-year-old, 3.25 kg intact male Chinchilla cat was presented with acute right hind limb paralysis. According to the owner's statement, the cat was anorexic and depressed from last few days before the presentation. On the day of admission, the cat was responsive and had no deep pain in right hind limb. In this side of limb, the femoral pulse was faint. The respiration and heart rates were 42 breaths/min and 200 beats/min, respectively. Systolic blood pressure measured by Doppler method was 146 mmHg. Cardiac auscultation revealed III-IV/VI left apical diastolic murmur. Electrocardiogram found P pulmonale (0.3 mV) and QT prolongation (230 msec). Full complete blood counts and serum biochemistry tests revealed no particular abnormalities except leukocytosis (23,400 counts/ μ L). Thoracic radiographs revealed a cardiomegaly (vertebral heart scale 9.0) with bi-atrial dilation (Valentine heart), along with unstructured interstitial lung pattern (Fig. 1). Two-dimensional echocardiography taken at right parasternal long-axis view of the four chambers at the end of ventricular diastole (Fig. 2A) and during atrial systole (Fig. 2B) revealed that the mitral valve leaflets were not maximally opened. A left apical view of the heart at the end of ventricular diastole also

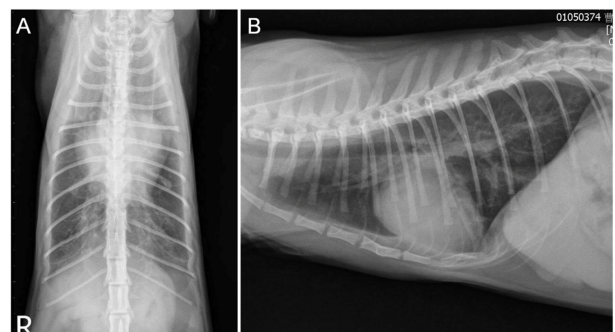


Fig. 1. The thoracic radiography of this case. (A) Ventrodorsal view of thoracic radiograph revealed a cardiomegaly with bi-atrial dilation (Valentine heart). (B) Right lateral of thoracic radiograph revealed a cardiomegaly (vertebral heart scale 9.0) with unstructured interstitial lung pattern.

revealed the mitral valve leaflets were not maximally opened (Fig. 2D). The color Doppler imaging taken at right parasternal long-axis view of the four chambers at the end of ventricular diastole found a diastolic jet from LA to left ventricle (LV). A right parasternal view of the aorta (Ao) and LA revealed severely enlarged LA (LA/Ao ratio 2.48; Fig. 3A). The left auricle projected cranially from the body of the LA, indicating the left auricle was also enlarged (Fig. 3A). M-mode echocardiography revealed slow early diastolic closure of the mitral valve indicated by remarkably reduced E-F slope (mid-diastolic closure velocity) and thickened mitral valve (Fig.

*Corresponding author

Tel: +82-33-250-8681, Fax: +82-33-259-5627

E-mail: hyun5188@kangwon.ac.kr

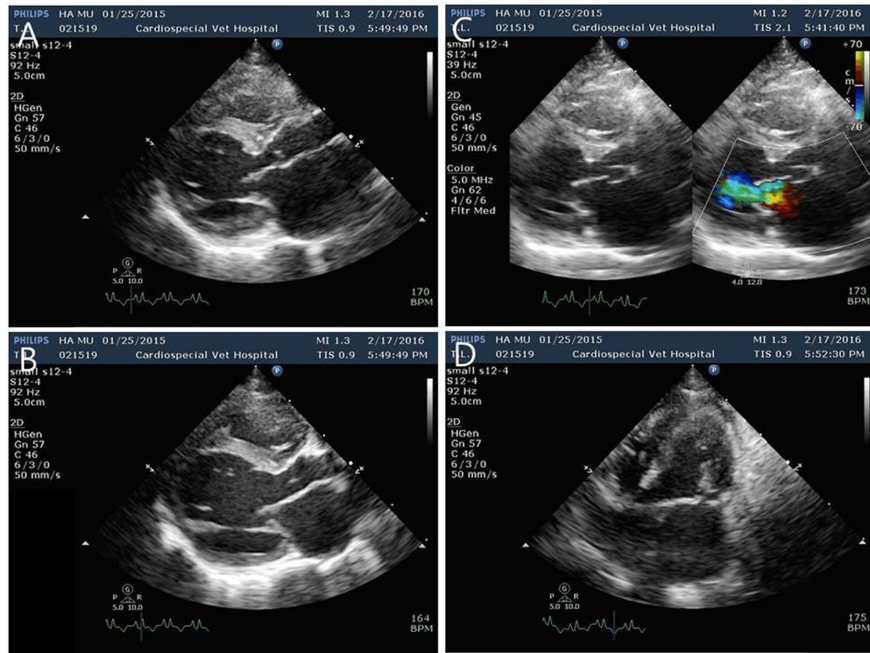


Fig. 2. The echocardiography of this case. (A and B) Two-dimensional echocardiography taken at right parasternal long-axis view of the four chambers at the end of ventricular diastole (A) and during atrial systole (B) revealed that the mitral valve leaflets were not maximally open. (C) The color Doppler imaging taken at right parasternal long-axis view of the four chambers at the end of ventricular diastole found a diastolic jet from left atrial (LA) to left ventricle (LV). (D) A left apical view of the heart at the end of ventricular diastole also revealed the mitral valve leaflets were not maximally open.

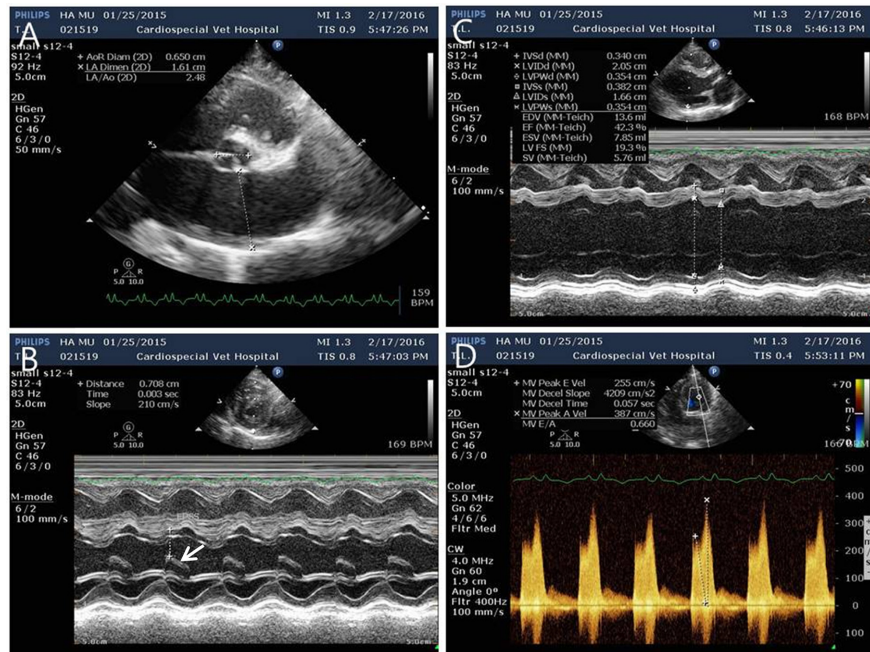


Fig. 3. The echocardiography of this case. (A) A right parasternal view of the aorta (Ao) and LA revealed severely enlarged LA (LA/Ao ratio 2.48). The left auricle projected cranially from the body of the LA, indicating the left auricle was also enlarged. (B) M-mode echocardiography revealed slow early diastolic closure of the mitral valve indicated by remarkably reduced E-F slope, thickened mitral valve and anterior movement of posterior mitral valve leaflet in early diastole. (C) The M-mode echocardiography revealed that markedly increased LV end-diastolic diameter (2.05 cm) and the end-systolic diameter (1.66 cm). The %fraction shortening (19.3%) and ejection fraction (42.3%) were also markedly reduced. (D) The continuous wave Doppler tracing at mitral annulus of left apical 4 chamber view found the peak velocity in early diastole (T-wave to P-wave on electrocardiogram) and atrial systole (P-wave to QRS complex) were 2.55 m/sec and 3.87 m/sec, respectively, indicating severe MS.

3B). Another M-mode finding was the anterior movement of posterior mitral valve leaflet in early diastole (Fig. 3B). The M-mode echocardiography revealed that markedly increased LV end-diastolic diameter (2.05 cm, normal = 1.2 cm) and the end-systolic diameter (1.66 cm, normal = 0.6 cm) (Fig. 3C). The %fraction shortening (19.3%) and ejection fraction (42.3%) were also markedly reduced, although the wall thicknesses were normal (Fig. 3C). The continuous wave Doppler tracing at mitral annulus of left apical 4 chamber view found the peak velocity in early diastole (T-wave to P-wave on electrocardiogram) and atrial systole (P-wave to QRS complex) were 2.55 m/sec and 3.87 m/sec, respectively, indicating severe MS (Fig. 3D). Mild pulmonary hypertension (PHT) was also indicated by high tricuspid regurgitation jet velocity of 3.18 m/sec. Based on these findings and young age, the case was diagnosed as congenital MS.

Initial treatment was directed to stabilize clinical condition related to heart failure using furosemide (0.5 mg/kg, q12h, orally [PO]; Sanofi-Aventis, USA) and pimobendan (0.3 mg/kg, q12h, PO; BI, Germany) and to prevent further thromboembolism using clopidogrel (18.75 mg/kg, q24h, PO; Sanofi-Aventis). Buprenorphine (0.03 mg/kg, q6–8h, subcutaneously; Reckitt Benckiser, UK) was also given for pain relieve in this cat. To improve anorexic condition, forced feeding with a prescription diet (Recovery; Royal Canine, USA) was requested to the owner. After 2 days of treatment, clinical condition of this cat was stabilized, although the cat was still anorexic. Respiration rate was ~20–30 breaths/min at resting. Deep pain sensation was recovered on right hind limb, although the right hind limb was still immobile. The cat was treated with the same medication. The function of right hind limb regained after 1 month of treatment. The cat is still alive and is being administered with the same medication, except pain relief.

Partial obstruction of blood flow from the LA to LV in diastole is characterized feature of MS in cats [1, 3, 6], causing pulmonary edema by the increased resistance of blood flow and subsequent increase in LA pressure along with increase in pulmonary capillary pressures [2]. Marked LA dilation can also facilitate the formation of thrombus in the LA and systemic circulation [8]. In this cat, the right hind limb paralysis might be caused by the markedly enlarged LA from severe mitral inflow obstruction. Tachypnea in this cat might be caused by mild pulmonary edema and pain associated with arterial thromboembolism on the right hind limb. Reflex pulmonary vasoconstriction by lower cardiac output in this cat might lead to PHT, evidenced by moderately increased velocity of tricuspid regurgitation jet. PHT is common complication in humans with mitral stenosis [2]. It has been also reported in dogs with MS [7]. Since the cause of PHT was increased pulmonary venous pressure by LA pressure overload, the PHT might not be severe, unless there is no concurrent right sided heart failure. No dog or cat with isolated MS has been reported with severe PHT, to date.

The cat presented with clinical signs (e.g., acute hind limb paralysis) consistent with hypertrophic cardiomyopathy (HCM).

In addition, the thoracic radiography showing cardiomegaly with marked bi-atrial dilation along with mild diffuse pulmonary infiltration, more convincingly suggested HCM in this cat. However, the echocardiograms in this cat were surprising and demonstrated that there were two combined problems (i.e., MS and PHT) without any evidence of HCM. Restricted leaflet motion and a turbulent inflow jet at mitral annulus in diastole were diagnostic findings of MS on the 2-D echocardiograms. The severity of the MS is generally determined by mitral valve orifice area and mean pressure gradient between LA and LV in human [2]. Severe MS can be defined by mitral valve orifice area $< 1.0 \text{ cm}^2$ and $> 10 \text{ mmHg}$ mean gradient in human [2]. However, the guideline for determining the severity of MS has yet been established in cats. Instead of a normal pressure gradient that peaks at approximately 2 mmHg, the pressure gradient in this cat was 25 to 60 mmHg, suggesting very severe stenosis. The E/E' ratio in this cat was 25, suggesting the LA pressure is higher than 20 mmHg. When the LA pressure increases to 20 mmHg, pulmonary edema starts to develop and progresses rapidly with increasing LA pressure. The progressively increased LA pressure might lead to PHT in this cat.

The M-mode echocardiogram in human with rheumatic mitral stenosis generally shows prolongation of the ejection fraction slope indicated by decreased (flat) E-F slope [2, 5]. In addition, the leaflet thickening and anterior motion of the posterior mitral leaflet on the M-mode echocardiography are diagnostic for rheumatic MS in human [2, 5]. Although rheumatic MS has never been reported in cats, the diagnostic features of MS on the M-mode echocardiography are similar [1, 3]. In this cat, those features were clearly demonstrated and suggested congenital MS. One feline study found that HCM can cause acquired MS [10]. However, there was no thickening of ventricular septal and free wall in this cat, indicating the HCM was unlikely.

Therapeutic options for MS in human are directed to manage rheumatic fever and heart failure with antibiotics and cardiac medication and to restore mitral valve function by either surgical mitral valve replacement or mitral valvuloplasty with balloon dilation [2]. Percutaneous balloon mitral valvuloplasty has been successfully applied in dogs and humans with good success rates [5, 7]. Acute mitral regurgitation is the most common complication after balloon mitral valvuloplasty [2]. However, the balloon mitral valvuloplasty has not been attempted in this cat, due to technical difficulty. Instead, treatment in this cat was directed to stabilize clinical condition related to heart failure, to prevent further formation of thrombus and to relieve pain associated with thromboembolism. Although thrombolytic therapy was not done in this cat, the hind limb function was regained with anti-coagulant therapy with pain control. The acute heart failure was manageable by the conventional cardiac medication including diuretics. Recent feline studies found that pimobendan was beneficial for reducing mortality and improving clinical sings associated with heart failure [4, 9]. In this case, administration of

pimobendan was beneficial to control clinical signs associated with heart failure.

In conclusion, this case was described a rare case of congenital MS complicated with PHT. The cat was successfully treated with conventional cardiac medication along with anti-coagulant therapy.

References

1. **Campbell FE, Thomas WP.** Congenital supravulvar mitral stenosis in 14 cats. *J Vet Cardiol* 2012, **14**, 281-292.
2. **Carabello BA.** Modern management of mitral stenosis. *Circulation* 2005, **112**, 432-437.
3. **Fine DM, Tobias AH, Jacob KA.** Supravulvar mitral stenosis in a cat. *J Am Anim Hosp Assoc* 2002, **38**, 403-406.
4. **Gordon SG, Saunders AB, Roland RM, Winter RL, Drourr L, Achen SE, Hariu CD, Fries RC, Boggess MM, Miller MW.** Effect of oral administration of pimobendan in cats with heart failure. *J Am Vet Med Assoc* 2012, **241**, 89-94.
5. **Kang DH, Park SW, Song JK, Kim HS, Hong MK, Kim JJ, Park SJ.** Long-term clinical and echocardiographic outcome of percutaneous mitral valvuloplasty: randomized comparison of Inoue and double balloon techniques. *J Am Coll Cardiol* 2000, **35**, 169-175.
6. **Kuijpers NW, Szatmári V.** Mitral valve dysplasia in a cat causing reversible left ventricular hypertrophy and dynamic outflow tract obstruction. *Tijdschr Diergeneeskd* 2011, **136**, 326-331.
7. **Lehmkuhl LB, Ware WA, Bonagura JD.** Mitral stenosis in 15 dogs. *J Vet Intern Med* 1994, **8**, 2-17.
8. **Matsuo A, Kanda T, Sugiyama A, Murase T, Hikasa Y.** Mitral stenosis with bacterial myocarditis in a cat. *J Vet Med Sci* 2007, **69**, 1171-1174.
9. **Reina-Doreste Y, Stern JA, Keene BW, Tou SP, Atkins CE, DeFrancesco TC, Ames MK, Hodge TE, Meurs KM.** Case-control study of the effects of pimobendan on survival time in cats with hypertrophic cardiomyopathy and congestive heart failure. *J Am Vet Med Assoc* 2014, **245**, 534-539.
10. **Takemura N, Nakagawa K, Machida N, Washizu M, Amasaki H, Hirose H.** Acquired mitral stenosis in a cat with hypertrophic cardiomyopathy. *J Vet Med Sci* 2003, **65**, 1265-1267.