

The Challenges of Diagnosing and Following Wilson Disease in the Presence of Proteinuria

Soofia Khan, Michael Schilsky*, Gary Silber, Bruce Morgenstern†, and Tamir Miloh‡

*Department of Pediatrics, Phoenix Children's Hospital, Phoenix, AZ, *Department of Gastroenterology, Yale University Medical Center, New Haven, CT, †Department of Pediatrics, Roseman University of Health Sciences, Las Vegas, NV, ‡Department of Pediatrics, Texas Children's Hospital, Houston, TX, USA*

The coexistence of Wilson disease with Alport syndrome has not previously been reported. The diagnosis of Wilson disease and its ongoing monitoring is challenging when associated with an underlying renal disease such as Alport syndrome. Proteinuria can lead to low ceruloplasmin since it is among serum proteins inappropriately filtered by the damaged glomerulus, and can also lead to increased urinary loss of heavy metals such as zinc and copper. Elevated transaminases may be attributed to dyslipidemia or drug induced hepatotoxicity. The accurate diagnosis of Wilson disease is essential for targeted therapy and improved prognosis. We describe a patient with a diagnosis of Alport syndrome who has had chronic elevation of transaminases eventually diagnosed with Wilson disease based on liver histology and genetics.

Key Words: Wilson, Glomerulopathy, Copper, Alport syndrome, Proteinuria, Zinc

INTRODUCTION

Alport syndrome is a glomerulopathy due to abnormal type 4 collagen in the glomerular basement membrane, and predisposes affected individuals to develop glomerulosclerosis. Affected individuals present with hematuria, renal failure, hearing loss, dyslipidemia, and retinal flecks. Diagnosis can be made by skin biopsy, renal biopsy, or genetic testing. Management includes angiotensin blockade therapy in the setting of overt proteinuria, and kidney trans-

plant if/when the disease progresses to end stage renal disease [1]. In Wilson disease (WD), copper accumulates in the liver, kidneys, brain, corneas, and other organs due to mutations in ATP7B. The diagnosis of WD may involve testing for serum ceruloplasmin, urinary excretion of copper, hepatic copper concentration, neurologic or psychiatric abnormalities and screening for ATP7B mutations [2,3]. In patients with renal disease that causes glomerular damage and non-selective proteinuria, the urinary copper excretion may be difficult to interpret since

Received : October 6, 2015, Revised : November 11, 2015, Accepted : January 4, 2016

Corresponding author: Tamir Miloh, Department of Pediatrics, Texas Children's Hospital, 6701 Fannin Street, Houston, TX 77030, USA. Tel: +832-8222778, Fax: +832-8253633, E-mail: tamir.miloh@bcm.edu

Copyright © 2016 by The Korean Society of Pediatric Gastroenterology, Hepatology and Nutrition

This is an open-access article distributed under the terms of the Creative Commons Attribution Non-Commercial License (<http://creativecommons.org/licenses/by-nc/4.0/>) which permits unrestricted non-commercial use, distribution, and reproduction in any medium, provided the original work is properly cited.

there are losses of heavy metals associated with proteins in their urine [4,5]. Little is known about levels of urinary copper and zinc excretion in children with proteinuric kidney diseases. We report on the case of a child diagnosed at an early age with Alport syndrome whom later developed abnormal liver enzymes, low serum ceruloplasmin and elevated urine heavy metals, findings that may be associated with glomerulopathy and medications. The concomitant diagnosis of WD was established, enabling targeted therapy to prevent progression of the liver disease.

CASE REPORT

A 17-year-old male was diagnosed with Alport syndrome at the age of 5 years due to the presence of hematuria, proteinuria, and a positive family history in his mother, maternal uncle, and brother. He did not have hearing loss or eye involvement. There was no family history of liver disease. Angiotensin blockade therapy was started. Routine laboratory monitoring revealed persistent elevation of transaminases (alanine aminotransferase 108-120 IU/L, aspartate aminotransferase 64-66 IU/L) for 2 years. Initially, this elevation was thought to be due to medication hepatotoxicity. However, liver enzymes

remained persistently elevated after medication discontinuation. Additionally, he had an elevated cholesterol (256 mg/dL) and triglycerides (270 mg/dL) and an abdominal ultrasound with increased echogenicity of the liver. Further workup due to chronic abnormal liver enzymes showed a low serum ceruloplasmin (< 10 mg/dL) and albumin (3.5 g/dL) but a normal total serum protein (6.4 g/dL). Urinary 24-hour excretion of copper was 159 mcg. Based on these results, a percutaneous liver biopsy was performed. Histological analysis showed diffuse bridging fibrosis, microvesicular and macrovesicular steatosis, and quantitative copper analysis demonstrated a high concentration of copper (1,260 mcg/gr dry weight liver), suggesting the diagnosis of WD (Fig. 1 and 2). Further confirmation was obtained with genetic testing showing the presence of two heterozygous WD mutations of ATP7B, V1262F and M645R. The patient was started on a chelating agent, trientine, and liver enzymes improved (Table 1). While on trientine, the 24-hour urinary excretion of zinc was high at 4,987 mcg, even though he was not on zinc supplementation at the time. He was transitioned 7 years after the diagnosis of WD to zinc maintenance monotherapy as his liver enzymes were near normal and 24-hour urine copper excretion was

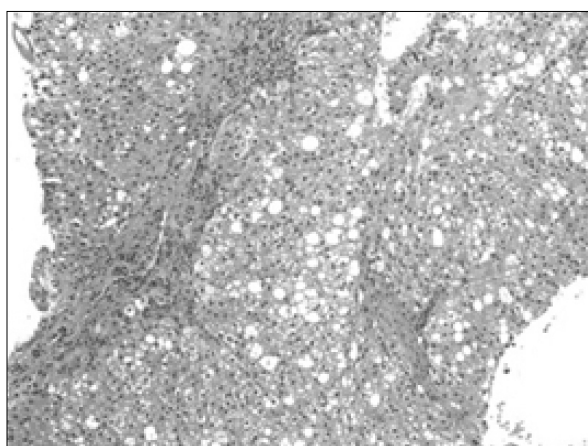


Fig. 1. Mild periportal inflammatory infiltrate composed of lymphocytes as well as the micro/macrovesicular steatosis. Provided by Department of Pathology, Phoenix Children's Hospital (H&E stain, $\times 200$).

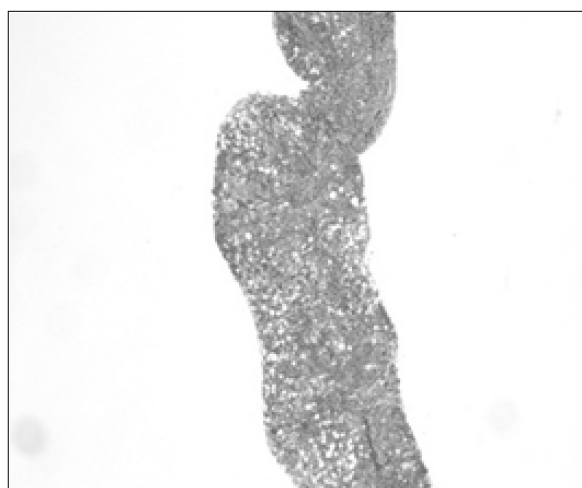


Fig. 2. In above picture, blue stained collagen is forming early bridging in the liver. Provided by Department of Pathology, Phoenix Children's Hospital (trichrome stain, $\times 40$).

Table 1. Laboratory Values

Date	Aspartate aminotransferase (IU/L)	Alanine aminotransferase (IU/L)	Ceruloplasmin (mg/dL)	Urinary protein (24-hour, mg/day)	Urinary copper (24-hour, mcg/day)	Urinary zinc (24-hour, mcg/day)
7/12/2006	64	103	< 10	-	-	-
12/1/2006			Started on trientine			
2/7/2007	61	104	-	-	246	-
8/12/2013	36	70	< 8	632	185	3,178
8/1/2013			Switched to zinc monotherapy			
12/23/2013	22	35	< 8	473	91	-
4/28/2014	31	57	-	-	118	2,399

decreasing. After 4 months on zinc, the liver enzymes normalized and 24-hour urine copper decreased appropriately to 91 mcg.

DISCUSSION

The diagnosis of WD and its ongoing monitoring is challenging when associated with an underlying kidney disease such as Alport syndrome. The frequency of abnormal liver enzymes in patients with Alport syndrome is unknown and the differential diagnosis can be broad. Elevated transaminases may initially be attributed to dyslipidemia or drug induced hepatotoxicity. Additionally, dyslipidemia may worsen in the setting of nephrotic syndrome. Angiotensin-converting enzyme-inhibitors, including Enalapril, Captopril, and Lisinopril, frequently used in the treatment of Alport syndrome, may infrequently have hepatotoxic effects [6-8]. However the differential diagnosis for the abnormal liver tests should also include hepatitis B, hepatitis C, alpha-1 antitrypsin, autoimmune hepatitis, nonalcoholic steatohepatitis and WD.

Initial laboratory results in the patient presented in our case report included a low serum ceruloplasmin. However, in Alport syndrome, proteinuria alone might lead to a low serum ceruloplasmin since this protein is among the serum proteins inappropriately filtered by the damaged glomerulus. Furthermore, Alport syndrome can also lead to increased urinary loss of heavy metals such as zinc and copper due to be presence of proteinuria [4,5,9], which may also com-

plicate the diagnosis and monitoring of the disease. Trientine treatment may also contribute to increased urinary zinc loss. Zinc deficiency has not been reported in patients with WD on chelation therapy, likely due to the ubiquitous presence of dietary zinc. Urine macroglobulin was not measured which could assist in differentiating the etiology of the urine zinc loss between proteinuria and chelation therapy.

Based on the Leipzig criteria for establishing a diagnosis of WD, elevated urine copper > 2 times the upper limit of normal will give 2 points, and low ceruloplasmin below 10 ng/dL will give an additional 2 points, summing 4 points, which is considered as a high likelihood of WD diagnosis [10]. In the patient described and in other patients with non-selective proteinuria, a low serum ceruloplasmin and increased urine copper could be attributed to the glomerulopathy rather than WD. We suggest that in patients with proteinuria and abnormal liver tests or other symptomatology (neurological or psychiatric), additional work up, including a liver biopsy and genetic testing, should be considered.

Little has been published about urinary zinc excretion in patients with WD not on zinc therapy. In our patient, urinary zinc excretion was high even before he was transitioned from trientine to zinc. This was similar to a recent report showing high zinc excretion in WD patients on trientine taken once daily [11]. Urine zinc may therefore be elevated due to chelation with trientine, however in our patient zinc excretion due to the leaky glomerulus and protei-

nuria could not be excluded. Therefore it may be difficult to monitor compliance with zinc therapy for maintenance as well unless baseline values are known for the patient off of all therapy [4,5,9]. On zinc monotherapy for his WD, the patient's liver enzymes have normalized and urinary copper excretion remains decreased, suggesting effective treatment.

REFERENCES

1. Savage J, Gregory M, Gross O, Kashtan C, Ding J, Flinter F. Expert guidelines for the management of Alport syndrome and thin basement membrane nephropathy. *J Am Soc Nephrol* 2013;24:364-75.
2. Roberts EA, Schilsky ML; American Association for Study of Liver Diseases (AASLD). Diagnosis and treatment of Wilson disease: an update. *Hepatology* 2008; 47:2089-111.
3. European Association for Study of Liver. EASL clinical practice guidelines: Wilson's disease. *J Hepatol* 2012; 56:671-85.
4. Morgan SM, Zantek ND. Therapeutic plasma exchange for fulminant hepatic failure secondary to Wilson's disease. *J Clin Apher* 2012;27:282-6.
5. Asfaha S, Almansori M, Qarni U, Gutfreund KS. Plasmapheresis for hemolytic crisis and impending acute liver failure in Wilson disease. *J Clin Apher* 2007;22:295-8.
6. da Silva GH, Alves AV, Duques P, Sevá-Pereira T, Soares EC, Escanhoela CA. Acute hepatotoxicity caused by enalapril: a case report. *J Gastrointest Liver Dis* 2010;19:187-90.
7. Droste HT, de Vries RA. Chronic hepatitis caused by lisinopril. *Neth J Med* 1995;46:95-8.
8. Schattner A, Kozak N, Friedman J. Captopril-induced jaundice: report of 2 cases and a review of 13 additional reports in the literature. *Am J Med Sci* 2001;322: 236-40.
9. Teslariu O, Nechifor M. Divalent cations levels change in nephrotic syndrome. *Rev Med Chir Soc Med Nat Iasi* 2012;116:883-7.
10. Stec J, Podracká L, Pavkovceková O, Kollár J. Zinc and copper metabolism in nephrotic syndrome. *Nephron* 1990;56:186-7.
11. Bovio G, Piazza V, Ronchi A, Montagna G, Semeraro L, Galli F, et al. Trace element levels in adult patients with proteinuria. *Minerva Gastroenterol Dietol* 2007;53: 329-36.