

# Acromion Fracture after Hook Plate Fixation for Distal Clavicle Injury: A Report of 2 Cases

Suk Kang, Ho Min Lee<sup>✉</sup>, In Hwa Back

Department of Orthopaedic Surgery, Dongguk University College of Medicine, Gyeongju, Korea

Fractures at the lateral end of the clavicle inevitably require surgical treatment as there is high potential for delayed union or nonunion. Acromioclavicular dislocation also requires stable and solid fixation for healing, and surgical treatment is recommended for the maintenance of joint function. The hook plate maintains the biomechanics of the acromioclavicular joint, enabling early range of motion. Therefore, for the past 10 years, the hook plate has been widely used in distal clavicle fractures and acromioclavicular joint injuries. However, the hook plate is associated with several complications, such as proximal clavicle fractures, widening of the hook hole, rotator cuff tear, subacromial impingement, and often acromial fractures. We report on two unusual cases of acromion fracture after hook plate fixation in patients with distal clavicle fracture and acromioclavicular dislocation alongside a literature review.

(Clin Shoulder Elbow 2016;19(3):168-171)

**Key Words:** Acromion; Clavicle; Hook plate; Osteolysis

For the past 10 years, the hook plate has been widely used in distal clavicle fractures and acromioclavicular joint injuries. Fractures at the lateral end of the clavicle account for 12% to 15% of all clavicle fractures, and it inevitably requires surgical treatment as there is high potential for delayed union (45%–65%) or nonunion (22%–33%).<sup>1)</sup> Acromioclavicular injuries account for 9% of all shoulder injuries<sup>2)</sup> and also require surgical treatment in some cases (Rockwood type III to IV) to recover joint function and minimize functional impairment.<sup>3)</sup> The hook plate maintains the biomechanics of the acromioclavicular joint<sup>4)</sup> and does not directly damage the joint, enabling early recovery of the range of motion.<sup>5)</sup> The hook plate also reduces the need for ligament reconstruction of the acromioclavicular joint<sup>6,7)</sup> and is associated with fewer complications than traditional methods.<sup>5,8)</sup> However, a hook plate may cause complications, such as proximal clavicle fractures, widening of the hook hole, rotator cuff tear, subacromial impingement, and often acromial fractures. Herein, we report on two cases of acromion fracture after hook plate fixation.

## Case Report

### Case 1

A 64-year-old man, who worked as a manual laborer, visited our emergency department with right shoulder pain that developed after falling on the floor. Swelling and tenderness were observed in the right acromioclavicular joint, and the range of motion was restricted. Instability and deformity of the acromioclavicular joint were confirmed. A simple radiograph showed widening and dislocation of the acromioclavicular joint, but the clavicle and acromion were intact; therefore, we planned to observe the patient with an 8-shape bandage and arm sling. On the 9th day follow-up, widening of the acromioclavicular joint was found and we decided to perform surgical treatment (Fig. 1A). He underwent open reduction-internal fixation with locking compression plate (LCP) clavicle hook plate fixation (Synthes, Solothurn, Switzerland) (Fig. 1B). An abduction brace was applied, and the patient was instructed to limit shoulder motion and heavy activity.

**Received** March 16, 2016. **Revised** June 3, 2016. **Accepted** July 25, 2016.

<sup>✉</sup>**Correspondence to:** Ho Min Lee

Department of Orthopaedic Surgery, Dongguk University Gyeongju Hospital, Dongguk University College of Medicine, 87 Dongdae-ro, Gyeongju 38067, Korea

**Tel:** +82-54-770-8221, **Fax:** +82-54-770-8378, **E-mail:** [shoulder2011@dongguk.ac.kr](mailto:shoulder2011@dongguk.ac.kr)

**Financial support:** None. **Conflict of interests:** None.

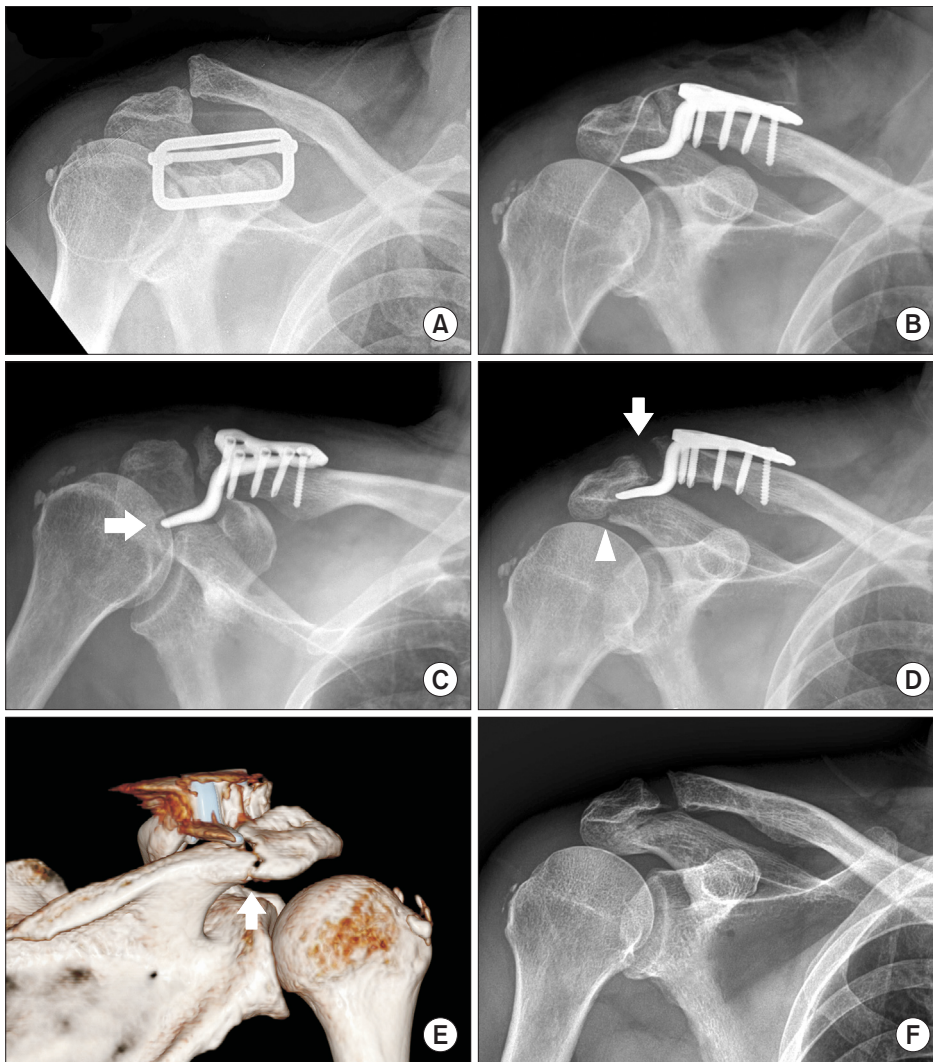


Fig. 1. (A) The clavicle anteroposterior view showing acromioclavicular joint dislocation of Rockwood type V. (B) Immediate postoperative radiograph showing acceptable reduction and internal fixation with locking compression plate clavicle hook plate. (C) At postoperative 4 weeks, radiography showing erosion (arrow) around the hook of the plate. (D) At postoperative 10 weeks, radiography showing fracture of the acromion (arrowhead) and dislocation of the acromioclavicular joint (arrow). (E) At postoperative 10 weeks, 3-dimensional computed tomography showing fracture of the acromion (arrow) and unhooking of the plate. (F) The radiography obtained 15 months after the initial surgery showing solid union of acromion.

Four weeks following the surgery, a simple radiograph showed erosion around the hook (Fig. 1C). However, the implant was maintained firmly according to the simple radiograph, and shoulder pain was tolerable on physical examination. Therefore, we decided to keep the abduction brace. Ten weeks after the surgery, a simple radiograph (Fig. 1D) and 3-dimensional computed tomography (3D-CT) (Fig. 1E) showed unhooked plate from below the acromion with an acromion fracture. The patient complained of increasing shoulder pain and limited range of motion. The implant was removed immediately, but acromion fixation was not performed because the acromion was found to be stable. On the 17-week follow-up, a simple radiograph and 3D-CT showed callus formation of the acromion and stable acromioclavicular joint. On the 15-month follow-up, radiograph showed union of the acromion (Fig. 1F), and the patient achieved active forward elevation of 140°, external rotation of 20°, his University of California at Los Angeles (UCLA) score was 32 points and Constant-Murley score was 90 points.

## Case 2

A 48-year-old man with an intellectual and developmental disability had painful disability of the left shoulder and right ankle after a pedestrian traffic accident. Swelling and tenderness was observed on the lateral end of the clavicle, and limitation of shoulder motion was observed. A simple radiograph showed a displaced fracture at the lateral end of the clavicle (Neer type IIB), but no injury was observed on the acromioclavicular joint (Fig. 2A). The fracture was managed with open reduction and internal fixation, using an LCP clavicle hook plate, and the shoulder was protected by 8-shape bandage and arm sling (Fig. 2B).

Two weeks after surgery, a simple radiograph showed erosion of the acromion around the hook, but we determined to further observe the patient, as shoulder pain was tolerable (Fig. 2C). However, displacement of the fracture site was observed on a follow-up X-ray taken postoperative 6 weeks (Fig. 2D). Seven weeks after the surgery, the patient complained of increased shoulder pain. A 3D-CT showed a fracture of the acromion

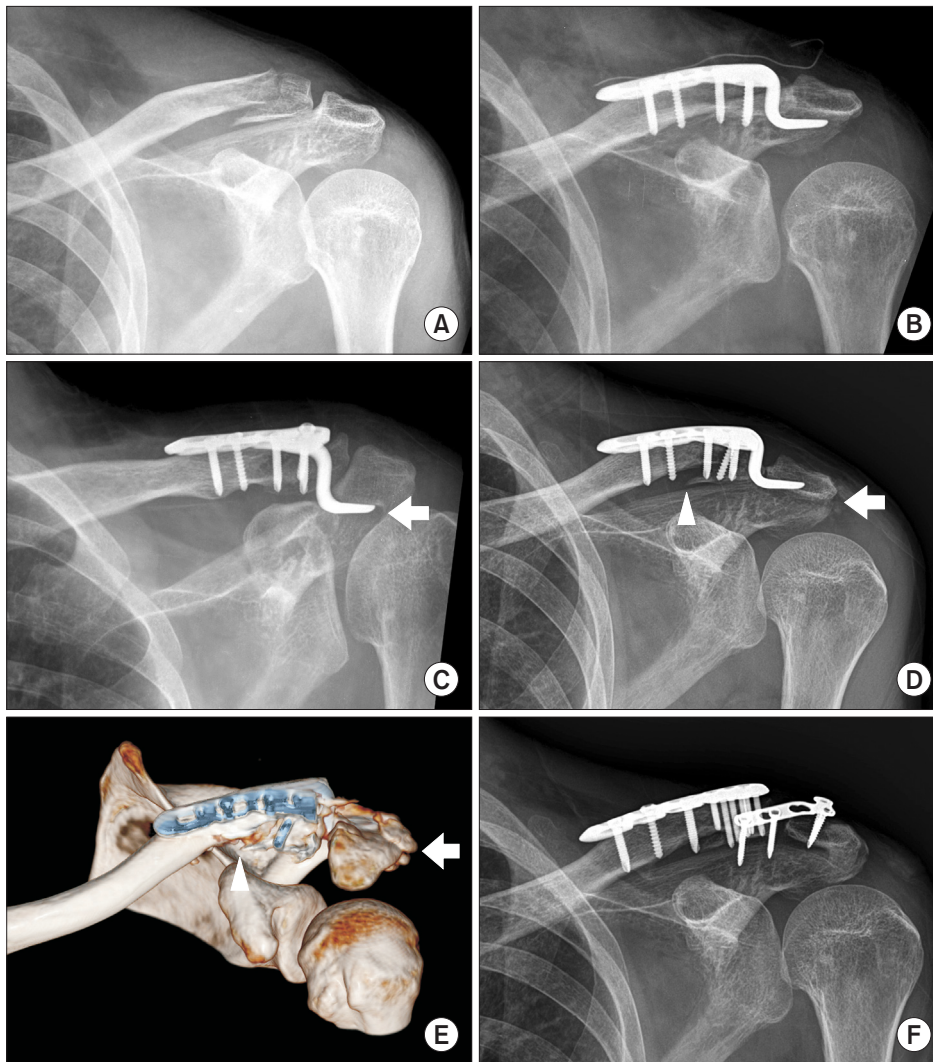


Fig. 2. (A) The initial radiography showing Neer type IIB fracture of lateral end of clavicle. (B) Immediate postoperative radiograph showing acceptable reduction and internal fixation with locking compression plate clavicle hook plate. (C) At postoperative 2 weeks, radiography showing erosion (arrow) around the hook of the plate. (D) The follow-up radiography taken 6 weeks after fixation showing displacement of fracture site (arrowhead) and fracture of acromion (arrow). (E) At postoperative 7 weeks, 3-dimensional computed tomography showing fracture of the acromion (arrow) and displacement of fracture site (arrowhead). (F) Radiography obtained 8 months after initial surgery showing callus formation and partial union of the acromion and union of the clavicle.

and displacement at the fracture site (Fig. 2E). The implant was removed 8 weeks after the surgery, and the clavicle was fixed with a LCP superior distal clavicle plate (Synthes) and acromion with a 2.7 mm locking L plate (Zimmer, Warsaw, IN, USA). The shoulder was protected with an immobilizer, and the patient was instructed not to use his shoulder for 3 weeks. At postoperative 6 months, the follow-up X-ray showed callus formation and partial union of the acromion and union of the clavicle (Fig. 2F). The patient achieved active forward elevation of 150°, external rotation of 45°, his UCLA score was 31 points and Constant-Murley score was 78 points.

## Discussion

Surgical methods for clavicle lateral end fracture and acromioclavicular dislocation include tension band wires, interfragmentary screws, intramedullary pins, coracoclavicular stabilization with sutures and wires, and Kirschner wires across the

acromioclavicular joint. Hook plate have recently been used widely due to the following advantages: easy manipulation during implant insertion, accurate maintenance of reduction,<sup>9</sup> and excellent results.<sup>5,8</sup> Hackenbruch et al.<sup>3</sup> reported that hook plates were associated with fewer complications than other surgical methods. In particular, the hook plate is useful in achieving a stable and solid union when there is a highly comminuted fracture at the distal clavicle.<sup>6</sup> Rotational movement occurs on the acromioclavicular joint during flexion and abduction of the humerus. The conventional rigid fixation method tends to limit the movement of the shoulder joint, leading to adhesive capsulitis.<sup>3</sup> However, the hook plate maintains the biomechanics of the acromioclavicular joint by reducing the necessity for ligament reconstruction and conserving the rotational movement of the acromioclavicular joint,<sup>4</sup> thus enabling early recovery of the range of motion for the shoulder joint.<sup>5</sup>

However, as with any other surgical procedures, complications can occur with the hook plate. Such complications include



medial clavicle fracture,<sup>6,4,9)</sup> widening of the hook hole, rotator cuff damage, subacromial impingement, hook cut-out, and acromial fracture.<sup>5)</sup> Among them, fracture of the acromion is an unusual complication associated with hook plates. Odak and Burton<sup>10)</sup> reported an acromial fracture in a 64-year-old male patient who underwent surgical management using a hook plate. At postoperative 12 weeks, the patient complained of increasing shoulder pain; acromion fracture was found on a computed tomography. Chiang et al.<sup>3)</sup> reported on an acromioclavicular joint dislocation (Rockwood type V) in a 54-year-old male patient who was operated with a clavicular hook plate (Synthes). On a postoperative 4-month follow-up X-ray, osteolysis of the acromion was observed. However, the patient refused to remove the hook plate, and acromion fracture and upward cutting of hook through the acromion was found at 8 months after the surgery.

Osteolysis and fracture of the acromion is thought to be due to stress overload on the acromion.<sup>6)</sup> Charity et al.<sup>7)</sup> insisted on early mobilization, but advised patients to avoid movements involving reaching high and heavy-lifting activities to minimize stress on the fixation and reduce movements of the hook under the acromion, for fear of erosion of the acromion or unhooking. Nevertheless, two of the three fixation cases showed failure in the absence of a second injury. Kashii et al.<sup>5)</sup> suggested that patients should be instructed to avoid forward flexion or adduction greater than 90° as well as internal rotation of the shoulder behind the back. Ding et al.<sup>9)</sup> also recommended that shoulder motion should be restricted until plate removal. Hackenbruch et al.<sup>8)</sup> restricted the range of movement until the plate is removed to prevent erosion and fracture of the acromion by reducing the stress on the acromion.

We experienced unusual cases of osteolysis and fracture of acromion after fixation, using a hook plate. Activity restriction was not possible in both of our cases after surgery. Therefore, although hook plate fixation is a useful method for acromioclavicular dislocation and distal clavicle fracture, we recommend not to use hook plates in patients who cannot follow a routine rehabilitation protocol before plate removal.

## References

1. Robinson CM. Fractures of the clavicle in the adult. Epidemiology and classification. *J Bone Joint Surg Br.* 1998;80(3):476-84.
2. Mazzocca AD, Arciero RA, Bicos J. Evaluation and treatment of acromioclavicular joint injuries. *Am J Sports Med.* 2007;35(2):316-29.
3. Chiang CL, Yang SW, Tsai MY, Kuen-Huang Chen C. Acromion osteolysis and fracture after hook plate fixation for acromioclavicular joint dislocation: a case report. *J Shoulder Elbow Surg.* 2010;19(4):e13-5.
4. Haidar SG, Krishnan KM, Deshmukh SC. Hook plate fixation for type II fractures of the lateral end of the clavicle. *J Shoulder Elbow Surg.* 2006;15(4):419-23.
5. Kashii M, Inui H, Yamamoto K. Surgical treatment of distal clavicle fractures using the clavicular hook plate. *Clin Orthop Relat Res.* 2006;447:158-64.
6. Nadarajah R, Mahaluxmivala J, Amin A, Goodier DW. Clavicular hook-plate: complications of retaining the implant. *Injury.* 2005;36:681-3.
7. Charity RM, Haidar SG, Ghosh S, Tillu AB. Fixation failure of the clavicular hook plate: a report of three cases. *J Orthop Surg (Hong Kong).* 2006;14(3):333-5.
8. Hackenbruch W, Regazzoni P, Schwyzer K. Surgical treatment of lateral clavicular fracture with the "clavicular hooked plate". *Z Unfallchir Versicherungsmed.* 1994;87(3):145-52.
9. Ding M, Ni J, Hu J, Song D. Rare complication of clavicular hook plate: clavicle fracture at the medial end of the plate. *J Shoulder Elbow Surg.* 2011;20(7):e18-20.
10. Odak S, Burton D. Early acromial erosion with the Synthes Hook Plate: an unusual complication and its treatment. *Shoulder Elbow.* 2010;2(3):182-4.