



Venous angioma may be associated with epilepsy in children

Bo Ryung Kim, MD¹, Yun Jin Lee, MD, PhD², Sang Ook Nam, MD, PhD², Kyung Hee Park, MD¹

¹Department of Pediatrics, Pusan National University Hospital, Pusan National University School of Medicine, Busan, ²Department of Pediatrics, Pusan National University Children's Hospital, Pusan National University School of Medicine, Yangsan, Korea

Purpose: Venous angioma (VA) is the most common congenital abnormality of the intracranial vasculature. This study aimed to investigate the relationship between VA and epilepsy and to identify the characteristics of children with VA and epilepsy.

Methods: The records of all patients aged less than 18 years who underwent brain magnetic resonance imaging (MRI) at Pusan National University Hospital were retrospectively reviewed. Patients with isolated VA and patients with normal MRI were compared in terms of the prevalence of epilepsy.

Results: In total, 2,385 pediatric patients who underwent brain MRI were enrolled. Isolated VA was identified in 26 patients (VA group). Among the patients with normal MRI findings, 225 age- and sex-matched patients to the VA-group were assigned to the control group. Nine patients in the VA group (9 of 26, 34.6%) and 27 patients in the control group (26 of 225, 11.5%; $P < 0.001$) had epilepsy. In the VA group, 20 patients (76.9%) had the VA in the cerebral hemispheres, and 6 patients (23.1%) had the VA in the brainstem and cerebellum. The latter showed a higher prevalence of epilepsy (5 of 6, 83.3%) than the former (4 of 20, 20.0%; $P = 0.004$). Among the nine patients who had epilepsy with VA, patients whose VA involved the brainstem and cerebellum showed a significantly higher frequency of abnormal Electroencephalographic findings than patients whose VA involved the cerebral hemispheres ($P = 0.016$).

Conclusion: VA, especially in the brainstem and cerebellum, might be associated with epilepsy.

Key words: Central nervous system venous angioma, Epilepsy, Brain stem, Cerebellum

Corresponding author: Kyung Hee Park, MD
Department of Pediatrics, Pusan National University Hospital, 179 Gudeok-ro, Seo-gu, Busan 49241, Korea

Tel: +82-51-240-7293

Fax: +82-51-248-6205

E-mail: kuma2002@hanmail.net

Received: 27 April, 2016

Revised: 18 July, 2016

Accepted: 20 July, 2016

Introduction

Venous angioma (VA) is a congenital anomaly of the medullary vein, the vessel that drains into the transparenchymal venous stem ("caput medusa" on the venous phase of angiography)^{1,2}. This is also referred to as a developmental venous anomaly³. VA is the most common intracranial vascular malformation in neuroimaging and autopsy series⁴. Magnetic resonance imaging (MRI) has detected VA in 0.7%–2.5% of all the studies⁵. The mechanism of VA is still unknown, but intrauterine accidents may be involved in the abnormal formation of the medullary veins or their tributaries⁶.

VA has been reported as an asymptomatic condition because it is often found incidentally during the evaluation of other different clinical features⁷. On the contrary, VA has been reported as a cause of seizures with incidence of seizures associated with symptomatic VA ranging from 8%–29%⁸. However several studies that utilized MRI demonstrated that these symptoms are related to other pathologies such as cavernous angioma and cortical dysplasia, which are highly epileptogenic lesion⁵. Controversy still exists in the literature regarding the epileptogenesis of VA. This study investigated whether VA is associated

Copyright © 2016 by The Korean Pediatric Society

This is an open-access article distributed under the terms of the Creative Commons Attribution Non-Commercial License (<http://creativecommons.org/licenses/by-nc/4.0/>) which permits unrestricted non-commercial use, distribution, and reproduction in any medium, provided the original work is properly cited.

with epilepsy by analyzing the prevalence and characteristics of epilepsy associated with intracranial VA in children.

Materials and methods

1. Materials

A retrospective study was conducted in children under 18 years old who underwent magnetic resonance (MR) brain between January 2009 and December 2013 in Pusan National University Hospital (n=2,385). The exclusion criteria were as follows: (1) presence of other pathologic brain lesion on MRI, (2) prior diagnosed central nervous system infection, genetic mutation, known syndromic disease, or inborn error of metabolism, (3) history of previous head trauma. The patients who had the appropriate finding of VA were designated as the VA group. Among the patients with normal MRI finding after excluding patients with MRI lesions other than VA, patients with age and sex matched to VA group was assigned to control group.

2. Methods

All children underwent MRI examination on a 1.5- or 3-Tesla Siemens Sonata (Magnetom symphony, Siemens Medical Solutions, Erlangen, Germany) using the standard circularly polarized head coil. Patients who could not undergo MRI test, were sedated with oral chloral hydrate (50 mg/kg), followed by intravenous midazolam (0.1 mg/kg; maximum, 5 mg). The MR protocol included scout pilot scans, followed by an axial 3-dimensional (3D) T1-weighted gradient-echo acquisition (TR/TE=20/5.6 msec; section thickness=2 mm; TR/TE, a basic pulse sequence parameters), an axial T2-weighted turbo spin-echo acquisition (TR/TE=5,020/106 msec; section thickness=4 mm), an axial velocity compensated 3D gradient echo susceptibility weighted imaging acquisition, and a postgadolinium T1-weighted acquisition (imaging parameters were the same as the noncontrast T1 sequence mentioned above). The contrast agent gadolinium-diethylenetriamine pentaacetic acid (Magnevist, Berlex, Wayne, NJ, USA) was bolus injected by a power injector (Medrad, Spectris MR injection system, Pittsburgh, PA, USA) with a dose of 0.1 mmol/kg of body weight at a rate of 3 mL/sec. The two neuroradiologists detected a presence of brain lesion.

Electroencephalograms (EEGs) were recorded using a Grass-Telefactor system (Telefactor Cop., Conshohocken, PA, USA) or Stellate Harmonie EEG (Stellate System Inc., Montreal, QC, Canada) with a high-cut filter 70 Hz for more than 40 minutes during sleep with or without the fully alert period. Patients with difficulty of the cooperation for the EEG examination were sedated with only chloral hydrate (50 mg/kg). The electrodes were applied in accordance to the international 10–20 system, referenced to both ears. A detailed interpretation of the interictal

features of the EEG records was performed by one of the board certified clinical epileptologist. A limited interrater agreement study was conducted by another epileptologists with no their clinical history. We reviewed the background and interictal activities of each EEG recording. The medical charts of both groups (VA and control groups) were investigated the mean age, gender, frequency and duration of seizures, seizure types, and final diagnosis. In the VA group, the location of VA, history of epilepsy, and EEG findings were investigated to analyze the relationship between location of VA and seizure activity.

3. Standard protocol approvals, registrations, and patient consents

Ethics permission for this study was granted by the Institutional Review Board of Pusan National University Hospital and fully informed written consent was obtained from each participant.

4. Statistical analysis

Data were stored in a dedicated access database and verified for accuracy. Statistical analyses were performed with SPSS ver. 15.0 (SPSS Inc., Chicago, IL, USA) using raw scores. Analyses presented here focus on the comparisons between the 2 groups (VA and control). Statistical comparison of the continuous and categorical variables was tested by means of t test and chi-square test as appropriate for the data. In addition to univariate nonparametric statistical tests, the results of the t test and chi-square tests were confirmed with the Mann-Whitney test and Fisher exact test. A *P* value <0.05 was regarded as statistically significant.

Results

Twenty-six patients with VA were identified. Among 1,239 patients with normal MRI finding, 225 patients with age and sex matched to VA group were included to control group. There were 9 epilepsy patients in the VA group (9 of 26, 34.6%) and 27 patients in the control group (26 of 225, 11.5%; *P*<0.001). The prevalence of epilepsy in the VA group was significantly higher than in control group (*P*<0.001) (Fig. 1). The chief complaints prompting MRI in the VA group were seizure (n=11), headache (n=8), developmental delay (n=1), and others (n=6).

In the 26 patients of the VA group, VA was located in the cerebral hemisphere in 20 patients (76.9%) and in the brainstem and cerebellum in six patients (23.1%) (Table 1). A prevalence of epilepsy was 4 patients with VA located in the cerebral hemisphere, 2 patients in the brainstem and 3 patients in the cerebellum. A significantly higher prevalence of epilepsy was found in patients with VA located in the cerebral hemisphere (83.3%, 5 of 6) than those in the brainstem and cerebellum (20%,

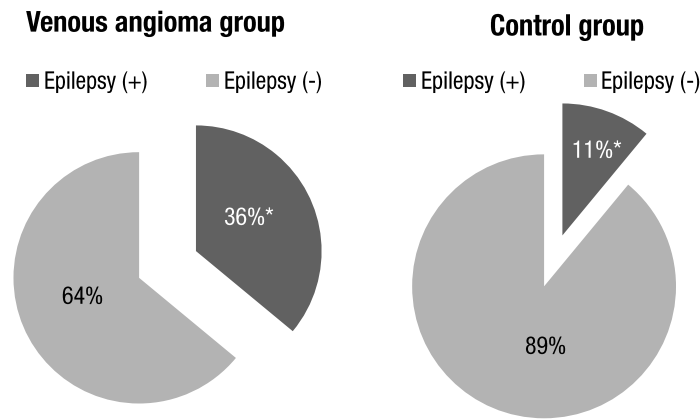


Fig. 1. Comparison of the prevalence of epilepsy between the venous angioma and control groups. * $P < 0.05$.

Table 1. Anatomical distribution of venous angioma (n=26)

Location	No of patients
Supratentorial	20 (76.9)
Frontal	9
Temporal	2
Parietal	5
Occipital	2
Basal ganglia	2
Infratentorial	6 (23.1)
Cerebellum	4
Brainstem	2

seizures (n=1) and partial seizure with secondary generation (n=1). Among the 9 patients diagnosed with epilepsy, abnormal EEG were exhibited in 4 cases. The location of VA of 4 patients with abnormal EEG were the brainstem in 1 patient (50%, 1 of 2) and the cerebellum in 3 patients (100%, 3 of 3) respectively. All patients with VA located in the cerebral hemisphere had normal EEG findings. The proportion of abnormal EEG finding was significantly higher in VA located in the brainstem and cerebellum (80%, 4 of 5) than in VA located in the cerebral hemispheres (0%, 0 of 4, $P=0.016$) (Fig. 3). Especially in VA located in the cerebellum, all patients showed abnormal EEG findings.

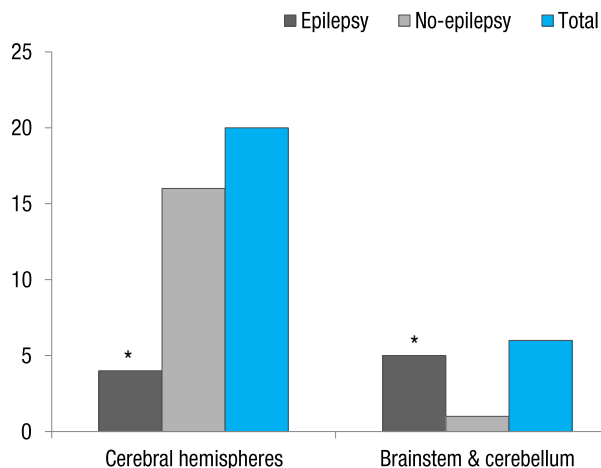


Fig. 2. Comparison of the prevalence of epilepsy according to the location of the venous angioma. * $P < 0.05$.

4 of 20, $P=0.004$) (Fig. 2).

The clinical characteristics of the nine patients with epilepsy in VA group are summarized in Table 2. The age at onset of epilepsy ranged from 5 months to 13 years. Seven patients had complex partial seizures. The remaining 2 patients had generalized tonic

Discussion

VA is the most common vascular malformation identified in neuroimaging studies. The detection rate of VA by MRI is variable, with reported rates between 0.7%–2.5%, and is in two third of the cases present supratentorially^{5,9}. The rates of VA and supratentorial involvement in our study are 0.9% (26 of 2,385) and 76.9% (20 of 26), which is similar proportion.

VA might manifest as an asymptomatic and benign condition. Garner et al.¹⁰ reviewed a series of 100 patients with radiologically identifiable VA and showed that seizures and focal neurological deficits were unusual associated findings and that the natural history of VA is relatively benign. Another study reported that epileptic seizures may actually originate from areas of cortical dysplasia which are occasionally located near a VA¹¹. On the other hand, VA has been reported as a seizure prone lesion. The relationship between VA and epilepsy has been widely reported in the previous studies, and it has been suggested that 8%–29% of patients with VA are epileptic⁸. However, there was no mention about the prevalence in the control group and the statistical significance.

Table 2. Clinical characteristics of patients with epilepsy in the venous angioma group

Patients	Sex	Age	Seizure type	Location	EEG finding
1	M	5 mo	CPS	Lt parietal	Normal
2	M	2 yr	PSSG	Lt temporal	Normal
3	F	7 yr	CPS	Lt parietal	Normal
4	F	7 yr	CPS	Rt frontal	Normal
5	M	6 yr	CPS	Brainstem	Normal
6	M	6 yr	CPS	Rt cerebellar hemisphere	OIRDA
7	F	13 yr	CPS	Rt pons	Generalized ED
8	M	13 yr	PSSG	Rt cerebellar hemisphere	Generalized and focal ED on Lt frontal and Rt central regions
9	F	17 yr	CPS	Lt cerebellar hemisphere	Focal theta on Rt temporoparietal region

EEG, electroencephalogram; Lt, left; Rt, right; CPS, complex partial seizure; PSSG, partial seizure with secondary generalization; OIRDA, occipital intermittent rhythmic delta activity; ED, epileptiform discharges.

Although VA is usually asymptomatic, when symptomatic, the most common symptoms are headaches, seizures, and hemorrhages, and we have occasionally treated the patients with VA associated with epilepsy. Presently, 36% of patients in the VA group and 11.5% of patients in the control group had epilepsy (Fig. 1); the difference was highly significant ($P<0.001$). This findings are contrary to the view the natural history of VA is a benign without significant clinical importance. Rather, our results support the view that VA is associated with epilepsy.

The anatomical distribution of VA has been reported as predominantly in the supratentorial location (two-thirds) more than in the infratentorial location (one-third)⁹. This was similar to our results. In 26 patients with VA, the cerebral hemispheres were involved in 20 patients (76.9%) and brainstem and cerebellum were involved in 6 patients (23.1%) (Table 1). Topper et al.⁹ reported that in patients presenting with seizures a supratentorial location of VA is more frequent than in the remaining patients. We documented that the prevalence of epilepsy was significantly higher in the patients with VA of the brainstem and cerebellum (83.3%, 5 of 6) than in them of the cerebral hemisphere (20%, 4 of 20, $P=0.004$) (Fig. 2). Our results differed from those of Topper et al.⁹, who included patients with other intracranial lesions as well as isolated VA. An important finding in our study was that predominance of infratentorial location can be found in patients with isolated VA and epilepsy.

Studies about the role of the brainstem and cerebellum in epileptogenesis are sparse. Traditionally, epileptic seizures have been thought of as cerebrocortical phenomena, but there have been reports of seizures that were thought to commence within the cerebellum¹²⁻¹⁴. Though no evidence exists to suggest that epileptic electrical activity occurs during these seizures, these reports postulate that at least in cases of cerebellar pathology such as cerebellar gangliogliomas, the cerebellum may be an epileptogenic lesion. In addition to its epileptogenic effects, the cerebellum has also been proposed to have a role in inhibition of seizures. Krauss and Koubeissi¹⁵ proposed that the cerebellar

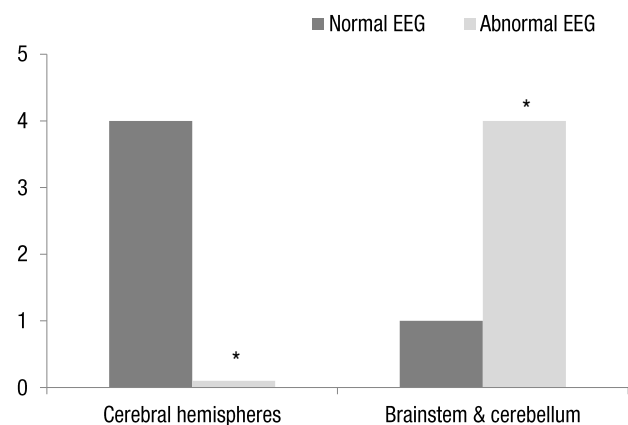


Fig. 3. Comparison of the electroencephalogram (EEG) abnormalities according to the location of the venous angioma. * $P<0.05$.

stimulation could reduce epileptogenic activity because of its gamma-aminobutyric acid-ergic Purkinje cell inhibitory output and widespread cortical projections. Together, nearly 70% of the patients who are reported with cerebellar stimulation in the published literature had reduction in seizures¹⁵. Blumenfeld et al.¹⁶ suggested the idea that increased cerebellar activity may contribute to seizure termination and/or to postictal suppression. From these results, we can speculate that VA may cause some degree of functional deficit in the cerebellum to inhibit seizure activity, rather than develop epileptogenic lesion by itself.

We examined 9 patients with VA and epilepsy to assess whether there was topographic concordance between the location of VA and ictogenesis in patients with epilepsy. In the interictal EEG, 5 patients had normal findings and 4 patients had abnormal findings. The proportion of abnormal EEG finding was significantly higher in VA located in the brainstem and cerebellum (80%, 4 of 5) than in VA located in the cerebral hemispheres (0%, 0 of 4, $P=0.016$) (Fig. 3). Especially in VA located in the cerebellum, all patients showed abnormal EEG findings. Thus we founded that convulsion with abnormal EEG finding was frequently

associated with VA of the brainstem and cerebellum. However, we cannot know whether abnormal EEG findings in VA located in the brainstem and cerebellum might be due to suppression of the inhibitory role of the cerebellum. Also, this study has some limitations as this study was conducted retrospectively. The number of VA group and control group was quite different, and the number of VA patients was too small compared with control group, limiting the statistical power.

However, our study has important clinical implications. We can suggest that VA might be associated with epilepsy. In addition, seizures were more frequently observed in the VA of the brainstem and cerebellum than in them of the cerebral hemispheres. Abnormal findings in EEG were also more often associated with VA located in the brainstem and cerebellum. The present results can indicate that special attention may be required for patients with VA especially located in the brainstem and cerebellum. Further studies with adequate sample size, and preferably multicenter are needed to investigate the relationship between the location of VA and developing epilepsy.

Conflict of interest

No potential conflict of interest relevant to this article was reported.

Acknowledgments

This study was supported by a clinical research grant from Pusan National University Hospital 2015.

References

1. Kraemer DL, Awad IA. Vascular malformations and epilepsy: clinical considerations and basic mechanisms. *Epilepsia* 1994;35 Suppl 6:S30-43.
2. Lasjaunias P. Vascular diseases in neonates, infants and children: interventional neuroradiology management. New York: Springer-Verlag; 1997.
3. Truwit CL. Venous angioma of the brain: history, significance, and imaging findings. *AJR Am J Roentgenol* 1992;159:1299-307.
4. Sarwar M, McCormick WF. Intracerebral venous angioma. Case report and review. *Arch Neurol* 1978;35:323-5.
5. Striano S, Nocerino C, Striano P, Boccella P, Meo R, Bilo L, et al. Venous angiomas and epilepsy. *Neurol Sci* 2000;21:151-5.
6. Lasjaunias P, Burrows P, Planet C. Developmental venous anomalies (DVA): the so-called venous angioma. *Neurosurg Rev* 1986;9:233-42.
7. Pereira VM, Geibprasert S, Krings T, Aurboonyawat T, Ozanne A, Toulgoat F, et al. Pathomechanisms of symptomatic developmental venous anomalies. *Stroke* 2008;39:3201-15.
8. Fujii M, Kitahara T, Moroi J, Kato S, Ito H. Temporal lobe epilepsy associated with cerebral venous angioma: case report. *Neurol Med Chir (Tokyo)* 1998;38:413-6.
9. Topper R, Jurgens E, Reul J, Thron A. Clinical significance of intracranial developmental venous anomalies. *J Neurol Neurosurg Psychiatry* 1999;67:234-8.
10. Garner TB, Del Curling O Jr, Kelly DL Jr, Laster DW. The natural history of intracranial venous angiomas. *J Neurosurg* 1991;75:715-22.
11. Gumus A, Yildirim SV, Kizilkilic O, Cengiz N, Cemil T. Case report: seizures in a child caused by a large venous angioma. *J Child Neurol* 2007;22:787-9.
12. Harvey AS, Jayakar P, Duchowny M, Resnick T, Prats A, Altman N, et al. Hemifacial seizures and cerebellar ganglioglioma: an epilepsy syndrome of infancy with seizures of cerebellar origin. *Ann Neurol* 1996;40:91-8.
13. Chae JH, Kim SK, Wang KC, Kim KJ, Hwang YS, Cho BK. Hemifacial seizure of cerebellar ganglioglioma origin: seizure control by tumor resection. *Epilepsia* 2001;42:1204-7.
14. Norden AD, Blumenfeld H. The role of subcortical structures in human epilepsy. *Epilepsy Behav* 2002;3:219-31.
15. Krauss GL, Koubeissi MZ. Cerebellar and thalamic stimulation treatment for epilepsy. *Acta Neurochir Suppl* 2007;97(Pt 2):347-56.
16. Blumenfeld H, Varghese GI, Purcaro MJ, Motelow JE, Enev M, McNally KA, et al. Cortical and subcortical networks in human secondarily generalized tonic-clonic seizures. *Brain* 2009;132(Pt 4):999-1012.