

# Proximity of the mandibular molar root apex from the buccal bone surface: a cone-beam computed tomographic study

Dokyung Kim, Jung-Hong Ha, Myoung-Uk Jin, Young-Kyung Kim, Sung Kyo Kim\*

Department of Conservative Dentistry, Kyungpook National University School of Dentistry, Daegu, Korea

**Objectives:** The purpose of this study was to evaluate the proximity of the mandibular molar apex to the buccal bone surface in order to provide anatomic information for apical surgery. **Materials and Methods:** Cone-beam computed tomography (CBCT) images of 127 mandibular first molars and 153 mandibular second molars were analyzed from 160 patients' records. The distance was measured from the buccal bone surface to the root apex and the apical 3.0 mm on the cross-sectional view of CBCT. **Results:** The second molar apex and apical 3 mm were located significantly deeper relative to the buccal bone surface compared with the first molar ( $p < 0.01$ ). For the mandibular second molars, the distance from the buccal bone surface to the root apex was significantly shorter in patients over 70 years of age ( $p < 0.05$ ). Furthermore, this distance was significantly shorter when the first molar was missing compared to non-missing cases ( $p < 0.05$ ). For the mandibular first molars, the distance to the distal root apex of one distal-rooted tooth was significantly greater than the distance to the disto-buccal root apex ( $p < 0.01$ ). In mandibular second molar, the distance to the apex of C-shaped roots was significantly greater than the distance to the mesial root apex of non-C-shaped roots ( $p < 0.01$ ). **Conclusions:** For apical surgery in mandibular molars, the distance from the buccal bone surface to the apex and apical 3 mm is significantly affected by the location, patient age, an adjacent missing anterior tooth, and root configuration. (*Restor Dent Endod* 2016;41(3):182-188)

**Key words:** Apical surgery; Apicoectomy; Buccal bone thickness; Cone-beam computed tomography; Mandibular molar; Root apex

Received November 3, 2015;  
 Accepted May 17, 2016

Kim D, Ha JH, Jin MU, Kim YK, Kim SK

\*Correspondence to  
 Sung Kyo Kim, DDS, MSD, PhD.  
 Professor, Department of Conservative Dentistry, Kyungpook National University School of Dentistry, 2177 Dalgubeol-daero, Jung-gu, Daegu, Korea 41940  
 TEL, +82-53-600-7621; FAX, +82-53-426-8958; E-mail: skykim@knu.ac.kr

## Introduction

Information regarding anatomical structures is essential for endodontic surgery because visualization and access to the surgical field may be compromised when this information is lacking.<sup>1</sup> When performing apical surgery in mandibular molars, the dentist's greatest concern is the position of the root apices within the mandible<sup>2</sup> and the thickness of the buccal bone plate,<sup>3</sup> *i.e.*, the distance from the outer surface of the buccal cortical plate to the root.

Frankel *et al.* reported that the bone thickness of the buccal side in anatomic sections of 33 human cadaver mandible halves were 4.2 mm and 7.4 mm in the first and second molars, respectively.<sup>2</sup> The width of the alveolar process significantly increases with posterior progression in the mandible. The buccal bone is thicker in the posterior region of the mandibular arch that forms the external oblique ridge. The root tips of

the premolars and first molars are usually close to the buccal bone plate, while those of second and third molars are close to the lingual plate. For this reason, the approach becomes more difficult as one progresses further into the posterior region. In some cases, apical access is very difficult through both cortical and medullary bones.<sup>1</sup>

Generally, apical surgery on the mandibular second molar is challenging because the thick buccal bone and tooth location in the arch make accessibility difficult.<sup>4</sup> Therefore, knowledge regarding the depth of the root apex and the apical 3 mm from the buccal bony surface, which is the level of root end resection, is of major importance when planning periapical surgery.

When planning endodontic surgery, cone-beam computed tomography (CBCT) may provide three-dimensional information on the anatomy of the jawbone and root configuration. Three-dimensional imaging allows clear identification of the anatomical relationship of the root apices to the adjacent anatomical structures in various directions.<sup>5-7</sup>

Presently, data are not available on the distance of the root apex from the buccal bone surface in relation to factors such as age, sex, adjacent teeth, and root configuration, and these factors need to be evaluated when planning apical surgery. Therefore, the aims of this study were to analyze the distance from the buccal bone surface to the root apex in the mandibular molar teeth by using CBCT images and to evaluate the differences according to various influencing factors.

## Materials and Methods

### Subjects

The CBCT images utilized in this study were for 127 mandibular first molars and 153 mandibular second molars from 160 patients (70 male and 90 female patients; age range, 16 - 78 years). These patient records were selected retrospectively from the database of the Kyungpook National University Dental Hospital. The inclusion criteria were completion of growth and clear CBCT images.

### CBCT data collection

CBCT images were obtained by using a PaX-Flex3D imaging system (VATECH America Inc., Fort Lee, NJ, USA) at the Department of Oral and Maxillofacial Radiology of the Kyungpook National University Dental Hospital. The images were created by taking a series of 0.8 mm thick cross-sectional slice images under a high-resolution bone algorithm with a 5 cm field of view, at 5 mA and 89 kV, for 24 seconds. The reconstruction matrix contained 416 x 416 pixels. When obtaining the CBCT images, the occlusal plane of each subject was perpendicular to the floor and each

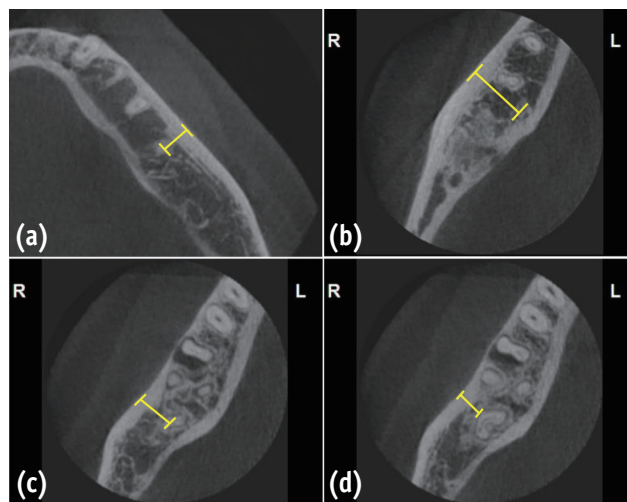
subject bit a tongue blade placed in the premolar region. The images were reconstructed by using Ez3Dplus software (VATECH America Inc.) and were saved in the Picture Archiving Communication System (PACS) at Kyungpook National University Hospital.

### Radiographic measurement

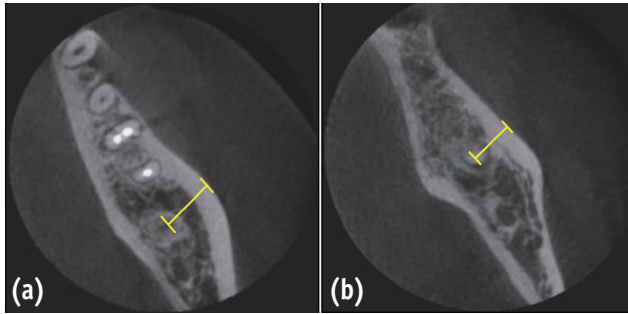
The distances were measured from the buccal bone surface to the root at apex and at a 3.0 mm level from the apex. The distance between the buccal or lingual surface of the root and the buccal bone surface was measured on the axial view of the CBCT images by using INFINITT PACS (INFINITT, Seoul, Korea) in mm (Figures 1 and 2). When a C-shaped root was involved, the measurement was obtained at the most convex point on the root surface (Figures 1c and 1d). After taking the measurements, the subjects were divided into groups according to age (11 - 20, 21 - 30, 31 - 40, 41 - 50, 51 - 60, 61 - 70, or 71 - 80 years), gender, presence of mandibular first and/or third molar teeth, and root configuration.

### Statistical analysis

The means and standard deviations of the distance from the buccal bone surface to the root were calculated. To determine the differences in distance according to age,



**Figure 1.** Mandibular axial cone beam computed tomography (CBCT) images for measurement. (a) The distance from the first molar apex to the buccal bone surface; (b) The distance from the disto-lingual root apex of the first molar to the buccal bone surface; (c) The distance from the C-shaped second molar apex to the buccal bone surface; (d) The distance from the buccal root surface at the apical 3 mm to the buccal bone surface with a C-shaped root.



**Figure 2.** Mandibular axial cone beam computed tomography (CBCT) images for mandibular second molars. (a) The distance between the second molar apex and the buccal bone surface, when the first molar is present; (b) The distance between the second molar apex and the buccal bone surface, when the first molar is absent.

gender, presence of adjacent teeth, and root configuration, one-way analysis of variance followed by Scheffe’s *post hoc* test was used. The significance level was set at  $p < 0.05$ . All statistical analyses were performed by using the SPSS software program (version 21.0, SPSS Inc., Chicago, IL, USA).

## Results

### Influence of tooth location

The distances of the apex of the mandibular first and second molars from the buccal bone surface are shown in Table 1. For both the mesial and distal roots, the second molar apex was located significantly deeper relative to the buccal bone surface compared with the first molar apex ( $p < 0.01$ ). The mean distances of the apical 3 mm levels of the mandibular first and second molars from the buccal bone surface are shown in Table 1. The buccal surface of the apical 3 mm of the second molar was located significantly deeper relative to the buccal bone surface compared with that of the first molar ( $p < 0.05$ ).

### The influence of gender

No significant difference was observed between genders in the distance of the root apex from the buccal bone surface for both the mandibular first and second molars (Table 2).

**Table 1.** Distance from the buccal bone surface to the root apex and root surfaces (mean  $\pm$  SD in mm)

	Mandibular first molar				Mandibular second molar			
	with one distal root (n = 89)		with two distal roots (n = 38)		with two roots (n = 88)		with one fused root (n = 65)	
	Mesial	Distal	Mesial	Disto-buccal	Disto-lingual	Mesial	Distal	C shape
Apex	4.87 $\pm$ 1.45 <sup>b</sup>	5.95 $\pm$ 1.7 <sup>c</sup>	4.38 $\pm$ 1.76 <sup>ab</sup>	3.94 $\pm$ 1.63 <sup>a</sup>	10.34 $\pm$ 2.03 <sup>e</sup>	8.78 $\pm$ 1.65 <sup>d</sup>	9.60 $\pm$ 1.96 <sup>e</sup>	9.45 $\pm$ 1.74 <sup>e</sup>
3 mm (B)	1.91 $\pm$ 1.37 <sup>a</sup>	2.80 $\pm$ 1.68 <sup>b</sup>	1.64 $\pm$ 1.42 <sup>a</sup>	1.86 $\pm$ 2.31 <sup>a</sup>	8.24 $\pm$ 2.06 <sup>d</sup>	5.04 $\pm$ 1.97 <sup>c</sup>	6.02 $\pm$ 2.45 <sup>c</sup>	6.09 $\pm$ 2.29 <sup>c</sup>
3 mm (L)	7.95 $\pm$ 1.25 <sup>b</sup>	8.26 $\pm$ 1.51 <sup>b</sup>	7.65 $\pm$ 1.24 <sup>b</sup>	6.30 $\pm$ 1.85 <sup>a</sup>	11.38 $\pm$ 1.87 <sup>c</sup>	10.14 $\pm$ 1.62 <sup>c</sup>	10.75 $\pm$ 2.03 <sup>c</sup>	10.69 $\pm$ 1.87 <sup>c</sup>

The same superscript letter indicates no significant difference in the distances from buccal bone surface to apex, 3 mm (B), and 3 mm (L) within each row.

B, to the buccal surface of the root; L, to the lingual surface of the root; SD, standard deviation.

**Table 2.** Distance from the buccal bone surface to the root apex in relation to gender (mean  $\pm$  SD in mm)

	Mandibular first molar				Mandibular second molar							
	n	MR	DR	n	MR	DBR	DLR	n	MR	DR	n	C-shape
p value		0.681	0.154		0.391	0.524	0.645		0.488	0.793		0.312
Male	41	4.80 $\pm$ 1.44	5.67 $\pm$ 1.73	17	4.16 $\pm$ 1.13	3.75 $\pm$ 1.44	10.23 $\pm$ 1.07	42	8.65 $\pm$ 1.71	9.54 $\pm$ 2.20	24	9.17 $\pm$ 1.78
Female	48	4.93 $\pm$ 1.47	6.19 $\pm$ 1.67	21	4.55 $\pm$ 1.54	4.09 $\pm$ 1.78	10.43 $\pm$ 1.47	46	8.89 $\pm$ 1.60	9.65 $\pm$ 1.73	41	9.62 $\pm$ 1.71

MR, mesial root; DR, distal root; DBR, disto-buccal root; DLR, disto-lingual root; SD, standard deviation.

**The influence of age**

The depth of the second molar apex from the buccal bone surface was significantly less in subjects over 70 years of age compared with those less than 70 years of age ( $p < 0.05$ , Table 3).

**The influence of the adjacent teeth**

The distance to the root apex of the second molar from the buccal bone surface was significantly shorter in cases missing the first molar compared with cases not missing the first molar ( $p < 0.05$ , Table 4). However, no difference was observed with regard to the presence or absence of the third molar (Table 5).

**Table 3.** Distance from the buccal bone surface to the root apex in relation to age (mean  $\pm$  SD in mm)

Age (yr)	Mandibular first molar							Mandibular second molar				
	n	MR	DR	n	MR	DBR	DLR	n	MR	DR	n	C-shape
11 - 20	4	4.97 $\pm$ 2.61 <sup>a</sup>	5.68 $\pm$ 2.59 <sup>a</sup>	4	4.47 $\pm$ 2.32 <sup>a</sup>	4.68 $\pm$ 1.48 <sup>a</sup>	10.19 $\pm$ 1.94 <sup>a</sup>	2	9.56 $\pm$ 0.71 <sup>b</sup>	9.95 $\pm$ 0.71 <sup>b</sup>	6	9.91 $\pm$ 0.54 <sup>a</sup>
21 - 30	21	4.97 $\pm$ 1.38 <sup>a</sup>	5.89 $\pm$ 1.92 <sup>a</sup>	6	4.15 $\pm$ 1.05 <sup>a</sup>	4.22 $\pm$ 1.82 <sup>a</sup>	9.88 $\pm$ 0.94 <sup>a</sup>	14	8.14 $\pm$ 1.58 <sup>b</sup>	8.99 $\pm$ 1.73 <sup>b</sup>	14	9.29 $\pm$ 1.27 <sup>a</sup>
31 - 40	27	5.07 $\pm$ 1.45 <sup>a</sup>	6.18 $\pm$ 1.77 <sup>a</sup>	10	4.47 $\pm$ 2.35 <sup>a</sup>	4.06 $\pm$ 1.97 <sup>a</sup>	10.73 $\pm$ 1.56 <sup>a</sup>	31	8.95 $\pm$ 1.80 <sup>b</sup>	9.78 $\pm$ 2.12 <sup>b</sup>	15	9.94 $\pm$ 1.38 <sup>a</sup>
41 - 50	15	4.93 $\pm$ 1.39 <sup>a</sup>	6.07 $\pm$ 1.66 <sup>a</sup>	7	4.45 $\pm$ 0.90 <sup>a</sup>	3.27 $\pm$ 1.11 <sup>a</sup>	10.29 $\pm$ 0.97 <sup>a</sup>	16	8.81 $\pm$ 1.59 <sup>b</sup>	9.51 $\pm$ 2.24 <sup>b</sup>	13	9.70 $\pm$ 2.42 <sup>a</sup>
51 - 60	6	4.38 $\pm$ 1.56 <sup>a</sup>	5.75 $\pm$ 1.53 <sup>a</sup>	7	3.82 $\pm$ 0.75 <sup>a</sup>	3.22 $\pm$ 0.62 <sup>a</sup>	9.97 $\pm$ 1.26 <sup>a</sup>	10	8.65 $\pm$ 1.39 <sup>b</sup>	9.73 $\pm$ 1.54 <sup>b</sup>	12	8.93 $\pm$ 2.04 <sup>a</sup>
61 - 70	4	4.67 $\pm$ 1.24 <sup>a</sup>	5.33 $\pm$ 1.11 <sup>a</sup>	4	4.07 $\pm$ 1.12 <sup>a</sup>	2.45 $\pm$ 0.75 <sup>a</sup>	10.24 $\pm$ 1.31 <sup>a</sup>	12	8.49 $\pm$ 1.55 <sup>b</sup>	9.30 $\pm$ 1.87 <sup>b</sup>	4	8.56 $\pm$ 0.53 <sup>a</sup>
71 - 80	4	4.29 $\pm$ 1.30 <sup>a</sup>	6.03 $\pm$ 1.37 <sup>a</sup>					3	6.58 $\pm$ 1.01 <sup>a</sup>	7.12 $\pm$ 0.38 <sup>a</sup>	2	9.39 $\pm$ 2.38 <sup>a</sup>

The same letter within columns indicates no significant difference.

MR, mesial root; DR, distal root; DBR, disto-buccal root; DLR, disto-lingual root; Yr, years; SD, standard deviation.

**Table 4.** Distance from the buccal bone surface to the mandibular second molar root apex in relation to the presence or absence of the first molar (mean  $\pm$  SD in mm)

	n	Mesial Root	Distal Root	n	C-shape
p value		0.046	0.022		0.210
Presence of first molar	69	8.96 $\pm$ 1.56	9.85 $\pm$ 1.87	51	9.66 $\pm$ 1.80
Absence of first molar	19	8.11 $\pm$ 1.83	8.69 $\pm$ 2.05	14	8.69 $\pm$ 1.27

SD, standard deviation.

**Table 5.** Distance from the buccal bone surface to the mandibular second molar root apex in relation to the presence or absence of the third molar (mean  $\pm$  SD in mm)

	n	Mesial Root	Distal Root	n	C-shape
p value		0.457	0.675		0.710
Presence of first molar	20	9.01 $\pm$ 1.68	9.76 $\pm$ 1.84	20	9.33 $\pm$ 1.65
Absence of first molar	67	8.70 $\pm$ 1.64	9.55 $\pm$ 2.01	45	9.51 $\pm$ 1.79

SD, standard deviation.

**Table 6.** Distance from the buccal bone surface to the mandibular second molar root apex in relation to root configuration (mean  $\pm$  SD in mm)

	<i>n</i>	Mesial Root	Distal Root
C-shape	65		9.45 $\pm$ 1.74 <sup>b</sup>
Non-C-shape	88	8.78 $\pm$ 1.65 <sup>a</sup>	9.60 $\pm$ 1.96 <sup>b</sup>

The same lowercase superscript letter indicates no significant difference. SD, standard deviation.

### The influence of root configuration

For the first molars, the depths of the distal root apex and the apical 3 mm of one distal-rooted tooth were significantly greater than those of the disto-buccal root apex and the apical 3 mm ( $p < 0.01$ ) and were significantly less than the depths of the disto-lingual root apex and the apical 3 mm in two distal-rooted teeth ( $p < 0.01$ , Table 1). For the mandibular second molar, the depth of the apex of C-shaped roots was significantly greater than that of the mesial root apex of non-C-shaped roots ( $p < 0.01$ , Table 6).

### Discussion

Apical surgery is often indicated when nonsurgical endodontic treatment fails to remove the etiology of the apical pathosis.<sup>8</sup> The rationale of surgical endodontic treatment, especially apicoectomy, is based on removing the etiology of the apical pathosis by using surgical means.<sup>9</sup> In apical surgery, osteotomy entails removal of the buccal bone to expose the root end; the approach for osteotomy must be deliberate and precise so that the osteotomy is performed exactly on the apices.<sup>10</sup> In terms of approaching the apex and obtaining the operating field, the thickness of the buccal bone is a crucial factor, especially in the molar area.

For the mandibular first molar, the mean distances from the root apices to the buccal bone surface for the mesio-buccal and disto-buccal roots were 4.38 mm and 3.94 mm, respectively, in the present study and were similar with those of another study.<sup>3</sup> These values indicate that the mesio-buccal and disto-buccal root apices of the mandibular first molar are relatively easy to access with surgical burs.<sup>9</sup> However, the mean dimension from the disto-lingual root apex to the buccal bone surface for the mandibular first molar is much deeper than that from the buccal root apices (10.34 mm in the present study). Given these values, long surgical burs and careful attention to access the disto-lingual root apex may be required for the mandibular first molar.

For the mandibular second molar, the mean distances between the buccal bone surface and root apices for the mesial and distal roots were 8.78 mm and 9.60 mm, respectively. These values indicate that the mandibular second molar root apex is located much deeper than the buccal root of the first molar. The external oblique ridge is present in the second molar region, and this would account for the greater distance of the second molar apex to the buccal bone surface compared to that of the buccal root of the first molar.<sup>2</sup> Given these values and the buccal muscle tension at the corner of the mouth, a routine apicoectomy procedure via the buccal approach may not provide successful outcome in these cases; therefore, different surgical techniques, such as intentional replantation, may be considered.<sup>4</sup> The bony lid technique is an option if the operator is going to conserve the buccal bone from destructively creating a bony window; this procedure involves placing the buccal plate back into its initial position after it has been separated into blocks.<sup>11,12</sup>

The thickness of the buccal bone over the root has been investigated in several studies.<sup>3,9,13</sup> The bone thickness was measured from the root apex in most of these reports. However, in this study, in addition to the apex, the 3 mm level from the apex was measured from the buccal bone surface. Morphology studies revealed that the apical 3 mm of the root contains canal irregularities, such as accessory or lateral canals, in most teeth.<sup>14-16</sup> Other studies showed that root resection of the apical 3 mm at a 0 degree bevel angle removes the majority of anatomical entities, which are potential causes of failure. Any remaining ramifications and lateral canals are sealed during retrograde filling of the canal, which extends 3 mm coronally.<sup>9,10,17</sup> Therefore, root end resection by 3 mm has become a standard procedure in apical surgery. The data regarding the distance between the buccal bone surface and the apical 3 mm level of the root in the present study may provide valuable clinical information for surgical endodontics.

In this study, we did not find statistically significant differences in buccal bone thickness with regard to gender or the presence/absence of mandibular third molar.

Therefore, recommending or planning different apical surgery protocols based on these factors appears to be unnecessary.

The distance from the buccal bone surface to the mesial root of the mandibular second molar was significantly different based on the presence or absence of the mandibular first molar. The buccal bone thickness was significantly less when the first molar was missing compared with when the first molar was present. At least two factors may explain this observation. First, the teeth in the buccal segments of the dental arches may have a tendency to migrate anteriorly, *i.e.*, possible mesial drift of the second molar when the first molar is missing.<sup>18</sup> Second, the alveolar bone volume decreases after the first molar is extracted.<sup>19,20</sup>

On the other hand, we found no difference in the thickness of the buccal bone over the second molar based on the presence or absence of the third molar in the present study. A previous study suggested that minimal changes occur in the mylohyoid and external oblique ridges area, which becomes increasingly prominent.<sup>21</sup> This may explain why the absence of the mandibular third molar did not affect the buccal bone thickness of the adjacent second molar teeth compared with the absence of the mandibular first molar.

In the present study, the distance from the root apex to the buccal bone surface was significantly shorter in patients older than age 70. This decreased dimension may be explained by age-related bone loss in women and men, which is largely due to gonadal steroid deficiency and physiological secondary hyperparathyroidism later in life.<sup>22,23</sup> Other factors also play key roles, including vitamin D deficiency, intrinsic defects in osteoblast function, impairment of the growth hormone/insulin-like growth factor level, reduced peak bone mass, age-associated sarcopenia, and various sporadic secondary causes.<sup>22,23</sup> However, more investigation may be necessary to generalize this finding of reduced dimension in patients older than 70 because of the limited number of the sample size in the present study.

For CBCT measurements, some discrepancies may exist between the values calculated on the CBCT images and the actual values of the subjects. In a previous study, the mean absolute errors between CBCT and direct measurements were small (0.30 and 0.13 mm for buccal bone height and buccal bone thickness, respectively), and the values obtained from the different measurements were not significantly different.<sup>13</sup> These studies suggest that, although CBCT measurements are not identical to the actual measurements, the CBCT values are acceptable and would not have a significant effect on data interpretation.<sup>13</sup>

## Conclusions

For apical surgery in mandibular molars, the distance from the buccal bone surface to the apex and apical 3 mm is significantly affected by the location, patient age, an adjacent missing anterior tooth, and root configuration.

## Acknowledgement

This research was supported by Kyungpook National University Research Fund 2012 (2013, 2014).

Orcid number

Jung-Hong Ha, 0000-0002-0469-4324

Young-Kyung Kim, 0000-0002-2534-9028

Sung Kyo Kim, 0000-0002-9160-7187

Conflict of Interest: No potential conflict of interest relevant to this article was reported.

## References

1. Ingle JI, Bakland LK, Baumgartner JC. Ingle's endodontics. 6th ed. Hamilton: BC Decker Inc.; 2008. p705-706.
2. Frankle KT, Seibel W, Dumsha TC. Anatomical study of the position of the mesial roots of mandibular molars. *J Endod* 1990;16:480-485.
3. Jin GC, Kim KD, Roh BD, Lee CY, Lee SJ. Buccal bone plate thickness of the Asian people. *J Endod* 2005;31:430-434.
4. Kratchman S. Intentional replantation. *Dent Clin North Am* 1997;41:603-617.
5. Patel S, Horner K. The use of cone beam computed tomography in endodontics. *Int Endod J* 2009;42:755-756.
6. Rigolone M, Pasqualini D, Bianchi L, Berutti E, Bianchi SD. Vestibular surgical access to the palatine root of the superior first molar: 'low-dose cone-beam' CT analysis of the pathway and its anatomic variations. *J Endod* 2003;29:773-775.
7. Blattner TC, George N, Lee CC, Kumar V, Yelton CD. Efficacy of cone-beam computed tomography as a modality to accurately identify the presence of second mesiobuccal canals in maxillary first and second molars: a pilot study. *J Endod* 2010;36:867-870.
8. Siqueira JF Jr. Aetiology of root canal treatment failure: why well-treated teeth can fail. *Int Endod J* 2001;34:1-10.
9. Johnson BR, Fayad M. Periradicular surgery. In: Hargreaves KM, Berman LH. Cohen's pathways of the pulp. 11th ed. Philadelphia: Elsevier Inc.; 2016. Chapter 9.
10. Kim, S. Osteotomy and apical root resection. In: Color

- atlas of microsurgery in endodontics. Philadelphia: Saunders; 2000. Chapter 9.
11. Khoury F, Hensher R. The bony lid approach for the apical root resection of lower molars. *Int J Oral Maxillofac Surg* 1987;16:166-170.
  12. Lasaridis N, Zouloumis L, Antoniadis K. Bony lid approach for apicoectomy of mandibular molars. *Aust Dent J* 1991;36:366-368.
  13. Timock AM, Cook V, McDonald T, Leo MC, Crowe J, Benninger BL, Covell DA Jr. Accuracy and reliability of buccal bone height and thickness measurements from cone-beam computed tomography imaging. *Am J Orthod Dentofacial Orthop* 2011;140:734-744.
  14. De Deus QD. Frequency, location, and direction of the lateral, secondary, and accessory canals. *J Endod* 1975;1:361-366.
  15. Seltzer S, Soltanoff W, Bender IB, Ziontz M. Biologic aspects of endodontics, I. Histologic observations of the anatomy and morphology of root apices and surrounding structures. *Oral Surg Oral Med Oral Pathol Oral Radiol* 1966;22:375-385.
  16. Wada M, Takase T, Nakanuma K, Arisue K, Nagahama F, Yamazaki M. Clinical study of refractory apical periodontitis treated by apicoectomy. Part 1. root canal morphology of resected apex. *Int Endod J* 1998;31:53-56.
  17. Kim S. Principles of endodontic microsurgery. *Dent Clin North Am* 1997;41:481-497.
  18. Noyes HJ. Mesial drift. *Angle Orthod* 1941;11:199-200.
  19. Schropp L, Wenzel A, Kostopoulos L, Karring T. Bone healing and soft tissue contour changes following single-tooth extraction: a clinical and radiographic 12-month prospective study. *Int J Periodontics Restor Dent* 2003;23:313-323.
  20. Kingsmill VJ, Boyde A. Variation in the apparent density of human mandibular bone with age and dental status. *J Anat* 1998;192:233-244.
  21. Kingsmill VJ. Post-extraction remodeling of the adult mandible. *Crit Rev Oral Biol Med* 1999;10:384-404.
  22. Khosla S, Melton LJ 3rd, Atkinson EJ, O'Fallon WM. Relationship of serum sex steroid levels to longitudinal changes in bone density in young versus elderly men. *J Clin Endocrinol Metab* 2001;86:3556-3561.
  23. Clarke BL, Khosla S. Physiology of bone loss. *Radiol Clin North Am* 2010;48:483-495.