

급성 입인두 감염 후에 발열과 경부 강직을 주소로 내원한 Lemierre 증후군 1례

이예나 · 홍예슬 · 김성수

순천향대학교 구미병원 소아청소년과

A Case of Lemierre Syndrome Manifests with Persistent Fever and Neck Stiffness Following Acute Oropharyngeal Infection

Yena Lee, Ye-Seul Hong, Sung Soo Kim

Department of Pediatrics, Soonchunhyang University Hospital, Gumi, Korea

Lemierre syndrome is a rare disease involving multiple organs affected by septic emboli following oropharyngeal infection. After the introduction of penicillin in the 1940s, it became a "forgotten" disease. However, due to the development of diagnostic image modalities including neck computed tomography (CT) scan, the number of published reports of Lemierre syndrome and diagnosis has been increasing since the 1990s. In this report, we describe a case of Lemierre syndrome, following oropharyngeal infection in a 16-year-old patient, who manifested with persistent fever and neck stiffness. Neck ultrasonography confirmed thrombus formation in the right internal jugular vein without definite evidence of septic emboli to other organs. After the three-week-long antibiotics therapy was completed, the thrombus in the right internal jugular vein finally disappeared.

Key Words: Lemierre syndrome, Thrombophlebitis

Introduction

Lemierre syndrome, also known as postanginal septicemia, is a rare disease that often affects healthy adolescents and young adults. In 1936, the French microbiologist Dr. Andre Lemierre described 20 patients with

septic thrombophlebitis secondary to pharyngitis and peritonsillar abscess¹⁾.

The main causative microorganism of Lemierre syndrome is *Fusobacterium necrophorum*²⁾. In the pre-antibiotic era, Lemierre syndrome was a complication of head and neck infection, which can cause fulminant disease with septicemia followed by death within 14 days. During the 1960s and 1970s, the syndrome was rarely reported because penicillin was widely prescribed for the treatment of oropharyngeal infection. However, the diagnosis rate for Lemierre syndrome has increased since the 1990s, possibly due to increased antibiotics resistance or change of antibiotics usage patterns, and development of image modalities³⁾.

Considering the risk of systemic septic emboli, it is

Received: 5 November 2015

Revised: 7 January 2016

Accepted: 9 January 2016

Correspondence: Sung Soo Kim

Department of Pediatrics, Soonchunhyang University Hospital, Gumi, Korea

Tel: +82-054-468-9232, Fax: +82-054-463-7504

E-mail: schroot@hanmail.net

important to consider this condition very early in examination of individuals with oropharyngeal infection. Physicians should be aware of this disease and consider it as a differential diagnosis in any adolescent patient suffering from pulmonary embolism or neurologic symptoms after oropharyngeal infection.

In South Korea, there were a total of 25 published reports of Lemierre syndrome, including a few teenagers^{4,5)}. We present another teenager case of Lemierre syndrome in a 16-year-old boy with initial manifestations of persistent fever and severe neck stiffness.

Case Report

A 16-year-old, previously healthy, male patient visited the emergency department with persistent fever, headache and neck stiffness. He was examined by a pediatrician in the out-patient clinic and was diagnosed with pharyngitis. However, his fever did not subside after four days, and his headache got worse.

His physical examination revealed pharyngeal erythema and neck stiffness. His initial blood pressure was 115/66 mmHg; pulse rate, 96 per minute; respiration rate, 20 per minute; and body temperature, 38.4°C.

His complete blood cell count showed a total white blood cell (WBC) of 16,200 cells/mm³, with a differential count of 90.9% granulocytes. His C-reactive protein (CRP) and erythrocyte sediment rate (ESR) were 36.13 mg/dL and 72 mm/hr, respectively. His initial chest radiograph did not show any infiltration in both lung fields.

Since he complained of severe neck pain and headache with persistent fever, our first consideration was meningitis. Spinal tapping and measurement of the intracranial pressure were performed. The intracranial pressure was 21 cmH₂O. The cerebrospinal fluid (CSF) cell differential count revealed a red blood cell (RBC) count of 0/μL; WBC count of 6/μL; CSF protein level of 23.3 mg/dL; and glucose level of 69 mg/dL. Due to the patient's elevated intracranial pressure and WBC count, we could not exclude meningitis as a possible diagnosis. Therefore, parenteral antibiotics were administered to him.

On the second day after admission, he complained of sudden onset of diplopia and limited neck motion. Computed tomography (CT) of the head and neck was performed and it suggested thrombus in the right internal jugular vein (Fig. 1). There were no abnormal findings in the brain parenchyma. In the evening of that day, his diplopia symptom disappeared without any sequelae. On third day after admission, the neck ultrasonography confirmed thrombus in the right internal jugular vein, which was 3.0×0.36 cm (Fig. 2A). On the doppler image, the blood flow of the right internal jugular vein was preserved. We determined this to be a case of Lemierre syndrome with septic thrombophlebitis secondary to oropharyngeal infection. Intravenous treatment with cefotaxime, clindamycin, and metronidazole was initiated.

Fever subsided on the sixth day after admission, which meant he had maintained a ten-day-long fever. On the

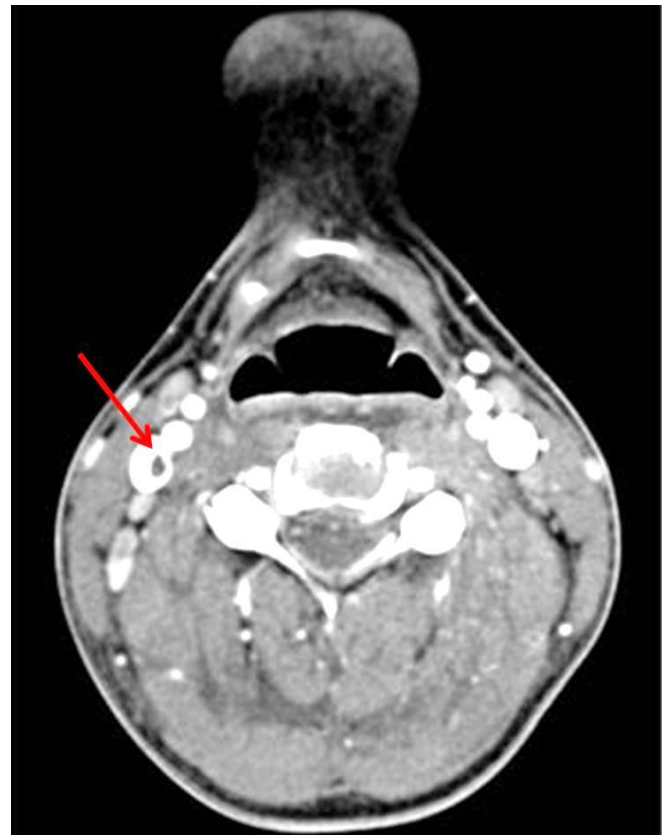

Fig. 1. Right jugular vein thrombus (arrow) was observed from the intracranial portion to the fourth C-spine level with patent blood flow.

10th day of the patient's admission, the thrombus had shrunk to 2.21×0.32 cm (Fig. 2B). On the 17th day, the C-reactive protein had decreased to 0.29 mg/dL. On the 18th day, the neck ultrasonography confirmed shrinkage of the thrombus to 1.03×0.16 cm (Fig. 2C). On the 20th day, the patient was discharged from the hospital with a prescription to continue six days of oral antibiotics.

The results of the blood cultures on the four, six, nine, and 11 days after his admission were all negative. The result of the CSF culture on the day of the patient's admission was also negative. A week after the patient's discharge, neck ultrasonography was performed and finally confirmed resolution of the thrombosis in the right internal jugular vein (Fig. 2D).

Discussion

Lemierre syndrome is a disease characterized by a recent oropharyngeal infection followed by internal jugular vein thrombosis and metastatic emboli to an end-organ such as the brain or lung. It is often caused

by anaerobic bacteria, mainly *Fusobacterium necrophorum*¹⁾.

Not all cases of *F. necrophorum* bacteremia advance to Lemierre syndrome. Some patients with *F. necrophorum* bacteremia will suffer from mild pharyngitis and then recover with oral antibiotics. However, others with *F. necrophorum* infection can develop life-threatening diseases such as Lemierre syndrome or peritonsillar abscess³⁾. Even with adequate parenteral antibiotics treatment, this syndrome can follow a fulminant course⁶⁾.

In the pre-antibiotics era, Lemierre syndrome was a common complication of head and neck infection. After the introduction of antibiotics in the 1940s, it was considered a "forgotten disease"⁷⁾. Recently, however, an increasing number of journals have been reporting Lemierre syndrome in young adults. According to the review journal by Karkos et al.⁸⁾, a MEDLINE search, using the term "Lemierre syndrome" as the only keyword, identified six published reports between 1980 and 1990, 50 articles from 1991 to 2000, and 121 articles in the eight years from 2001–2008. Whether this represents a true increase in the incidence of Lemierre syndrome or reflects a higher diagnosis rate due to the

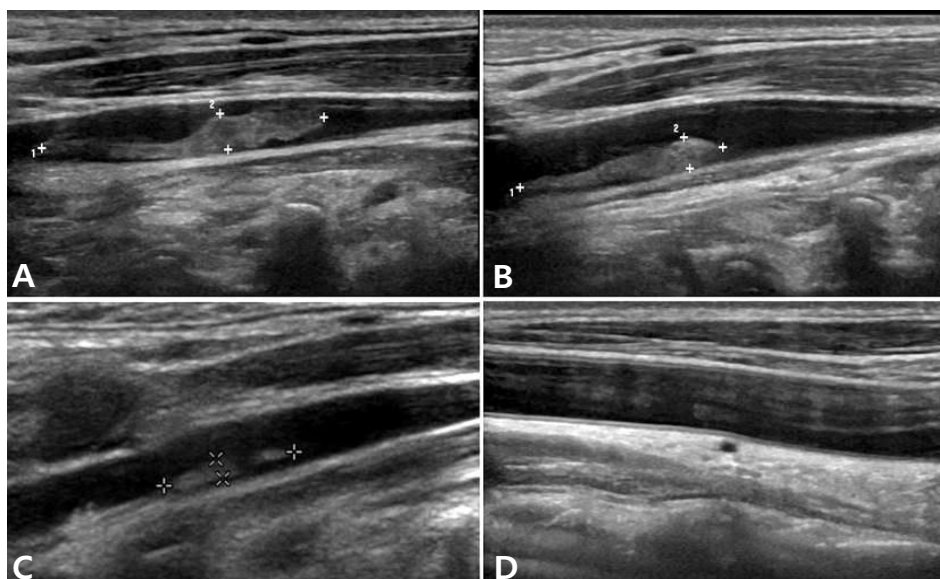


Fig. 2. Shrinkage of thrombosis in the right jugular vein after parenteral antibiotics therapy. (A) A 3.0×0.36 cm elongated solid mass was observed. (B) Intraluminal thrombus was measured approximately 2.21×0.32 cm. (C) Intraluminal thrombus was measured approximately 1.03×0.16 cm. (D) Follow up ultrasonography was done on sixth day after discharge. The resolution of thrombus was confirmed.

introduction of advanced radiologic methods, especially the use of neck computed tomography (CT) scan, remains to be seen⁸⁾.

According to the article by Ramirez et al.³⁾, authors hypothesized the reason for an increased incidence of Lemierre syndrome is the judicious use of antibiotics after a health campaign about appropriate antibiotic use for upper respiratory infections. As a result, even if the initial diagnosis was uncomplicated pharyngitis, it could progress to Lemierre syndrome. On the other hand, others pointed out the reason for the increased incidence could be due to improved anaerobic blood culture techniques and better identification of *Fusobacterium* spp⁹⁾. Considering the high prescription rate of oral antibiotics for upper respiratory infections, we can attribute the higher incidence of Lemierre syndrome in Korea to an increasing number of antibiotics-resistant bacteria.

Approximately 80% of the cases of Lemierre syndrome are caused by anaerobic bacteria called *F. necrophorum*²⁾. It is a gram-negative bacillus commonly found in the oral cavity, gastrointestinal tract, and female genital tract. *F. necrophorum* is the most common bacterial agent of pharyngitis in young adults aged 15 to 30 years and can cause persistent sore throat syndrome^{10,11)}. Therefore, in this age group, clinicians should be more aware of *F. necrophorum* as a causative organism for pharyngitis than *Streptococcus pyogenes*¹¹⁾. However, the fact that *F. necrophorum* is an anaerobe makes it difficult to identify this organism through routine blood culture or a throat culture.

In the case reported herein, all blood cultures were negative and bacteremia was not confirmed. We assumed that this might be due to the fact that blood culture was done on the fourth day after admission. Intravenous antibiotics were started on the first day of admission after CSF tapping. Furthermore, before noticing thrombosis in the internal jugular vein, we could not assume *F. necrophorum* as a causative organism and anaerobic bacterial blood culture was not included as an initial evaluation.

The pathogenesis of Lemierre syndrome requires several stages. *F. necrophorum* initially invades the

palatine tonsils and the peritonsillar tissue in approximately 87% of cases²⁾. The remaining 13% of cases involve primary pharyngitis, parotitis, sinusitis, mastoiditis, otitis media, and odontogenic infections¹²⁾. Then the infection spreads to the parapharyngeal space with subsequent invasion of the posterior compartment along the carotid sheath, causing thrombophlebitis of the internal jugular vein. A less common route is direct extension of the thrombophlebitis from the peritonsillar veins²⁾.

Once thrombophlebitis develops in the internal jugular veins, the infection can spread to multiple organs via septic emboli, and lead to metastatic complications. The most frequently involved organs are the lungs and joints. Other sites involved in septic emboli and abscess formation includes muscles, soft tissues, liver, spleen, and central nervous system⁸⁾. In the case reported herein, the patient did not show any metastatic emboli to other organs. Although thromboembolism was not detected by brain CT scan, we suspect that the patient's diplopia could be a sign of metastatic emboli in the central nervous system. Had the diplopia persisted, we would have investigated a brain lesion via a brain magnetic resonance image (MRI).

Hypercoagulability usually accompanies Lemierre syndrome, and it plays a major role in the formation of a septic thrombus. The exact mechanism of hypercoagulability is not yet fully understood. In vitro studies of *F. necrophorum* infection suggested that cell-to-cell contact of virulent strains of *F. necrophorum* with platelets leads to platelet aggregation. Also, endothelial damage caused by *F. necrophorum* may be attributed to clot formation in Lemierre syndrome¹³⁾. However, it is unclear if thrombosis in Lemierre syndrome is attributable to a transient hyperthrombotic state or is a manifestation of thrombophilia triggered by the acute bacterial infection.

According to a study¹⁴⁾ of thromboembolic outcomes in Lemierre syndrome, all seven subjects presented thrombophilia at their diagnosis. Three patients were positive for plasma antiphospholipid antibodies, and the other four showed elevated factor VIII activity. Six months later, factor VIII normalized in all cases, and

the lupus anticoagulant became negative in two (67%) of three cases. This suggests that thrombophilia is a transient phenomenon caused by an inflammatory process rather than intrinsic hypercoagulability of the patients¹⁴⁾.

The main treatment for Lemierre syndrome is parenteral antibiotics. In fact, there is no randomized study to determine optimal agents for the treatment of *F. necrophorum* infection. Based on several studies, penicillin or clindamycin are not recommended as a monotherapy, because β -lactamase producing strains of *F. necrophorum* have been reported, and co-infecting pathogens can produce β -lactamase. Additionally, clindamycin is known to have weaker bactericidal activity¹⁵⁾.

According to a journal article by Kuppalli et al.¹⁶⁾, a combination of ceftriaxone and metronidazole are recommended as they can cover both *F. necrophorum* and oral streptococci. Another journal¹⁷⁾ mentioned that β -lactamase-resistant antibiotics with anaerobic activity are recommended agents, such as ticarcillin-clavulanate, ampicillin-sulbactam, ceftiofex, metronidazole, and amoxicillin-clavulanate. Even though there are differences between these reports, it is certain that clindamycin and penicillin monotherapy should be avoided. Metronidazole is believed to have excellent activity against *Fusobacterium* spp¹⁶⁾. Therefore, we carefully recommend the combination therapy of penicillin/ β -lactamase inhibitor or second or third generation cephalosporin with metronidazole. However, the choice of antibiotics can be altered following clinical response.

A typical course of antibiotic therapy ranges from three to six weeks. According to previous reports, the treatment duration can vary from nine to 128 days¹⁸⁾. The response to the treatment can be slow, because *F. necrophorum* is believed to remain viable inside the necrotic tissue for days to a few weeks even after the start of intravenous antibiotic therapy¹⁸⁾. Once the clinical symptoms are settled, intravenous treatment can be switched to oral antibiotics. Total treatment duration can be shortened if the clinical progress is favorable. However, less than two weeks of therapy would not

be recommended given the fact that relapses have been documented¹⁵⁾.

In the case reported herein, we administered the triple antibiotics therapy of cefotaxime, clindamycin, and metronidazole for 19 days, 14 days, and 12 days, respectively. After the patient's discharge, he was prescribed oral third-generation cephalosporin antibiotics for six days and completed three-week antibiotics therapy.

Anticoagulation for treating Lemierre syndrome is still controversial. Some researchers recommend anticoagulation therapy to prevent further progression of thrombus and to decrease the possibility of septic emboli^{3,6)}. Others are concerned with the risk of hemorrhage¹⁹⁾. In the case reported herein, the patient was not prescribed anticoagulation therapy. Instead, we performed neck ultrasonography every four to five days to ascertain the status, an eventual shrinkage, of the thrombus.

In conclusion, pediatricians should consider Lemierre syndrome a possible diagnosis if the patient develops severe neck pain with limitation of neck motion, neurologic symptoms, respiratory symptoms that may suggest metastatic thromboemboli after head and neck infection. Also, clinicians should remember *F. necrophorum* as an important organism causing pharyngotonsillitis in young adults aged 15 to 30 years.

References

1. Lemierre A. On certain septicaemia due to anaerobic organisms. *Lancet* 1936;227:701-3.
2. Chirinos JA, Lichtstein DM, Garcia J, Tamariz LJ. The evolution of Lemierre syndrome: report of 2 cases and review of the literature. *Medicine (Baltimore)* 2002;81:458-65.
3. Ramirez S, Hild TG, Rudolph CN, Sty JR, Kehl SC, Havens P, et al. Increased diagnosis of Lemierre syndrome and other *Fusobacterium necrophorum* infections at a children's hospital. *Pediatrics* 2003;112:e380-5.
4. Bae YA, Lee JJ, Kim HB, Hong MS, Lee K, Lee Y, et al. Lemierre syndrome: a case report. *J Korean Radiol Soc* 2006; 54:7-10.

5. Kim EJ, Park JH, Kim CH, Park JY, Jung TH, Cha SI. A case of Lemierre syndrome associated with septic pulmonary emboli. *Tuberc Respir Dis* 2005;58:73-7.
6. Venglarcik J. Lemierre's syndrome. *Pediatr Infect Dis J* 2003; 22:921-3.
7. Screatton NJ, Ravenel JG, Lehner PJ, Heitzman ER, Flower CD. Lemierre syndrome: forgotten but not extinct--report of four cases. *Radiology* 1999;213:369-74.
8. Karkos PD, Asrani S, Karkos CD, Leong SC, Theochari EG, Alexopoulou TD, et al. Lemierre's syndrome: a systematic review. *Laryngoscope* 2009;119:1552-9.
9. Hagelskjaer LH, Prag J, Malczynski J, Kristensen JH. Incidence and clinical epidemiology of necrobacillosis, including Lemierre's syndrome, in Denmark 1990-1995. *Eur J Clin Microbiol Infect Dis* 1998;17:561-5.
10. Batty A, Wren MW, Gal M. *Fusobacterium necrophorum* as the cause of recurrent sore throat: comparison of isolates from persistent sore throat syndrome and Lemierre's disease. *J Infect* 2005;51:299-306.
11. Centor RM, Atkinson TP, Ratliff AE, Xiao L, Crabb DM, Estrada CA, et al. The clinical presentation of *Fusobacterium*-positive and streptococcal-positive pharyngitis in a university health clinic: a cross-sectional study. *Ann Intern Med* 2015; 162:241-7.
12. Golpe R, Marin B, Alonso M. Lemierre's syndrome (necrobacillosis). *Postgrad Med J* 1999;75:141-4.
13. Forrester LJ, Campbell BJ, Berg JN, Barrett JT. Aggregation of platelets by *Fusobacterium necrophorum*. *J Clin Microbiol* 1985;22:245-9.
14. Goldenberg NA, Knapp-Clevenger R, Hays T, Manco-Johnson MJ. Lemierre's and Lemierre's-like syndromes in children: survival and thromboembolic outcomes. *Pediatrics* 2005;116:e543-8.
15. Riordan T. Human infection with *Fusobacterium necrophorum* (Necrobacillosis), with a focus on Lemierre's syndrome. *Clin Microbiol Rev* 2007;20:622-59.
16. Kuppalli K, Livorsi D, Talati NJ, Osborn M. Lemierre's syndrome due to *Fusobacterium necrophorum*. *Lancet Infect Dis* 2012;12:808-15.
17. Bondy P, Grant T. Lemierre's syndrome: what are the roles for anticoagulation and long-term antibiotic therapy? *Ann Otol Rhinol Laryngol* 2008;117:679-83.
18. Syed MI, Baring D, Addidle M, Murray C, Adams C. Lemierre syndrome: two cases and a review. *Laryngoscope* 2007;117:1605-10.
19. Hagelskjaer KL, Prag J. Human necrobacillosis, with emphasis on Lemierre's syndrome. *Clin Infect Dis* 2000;31:524-32.

요약

Lemierre 증후군은 급성 입인두 감염의 합병증으로 생기는 질환으로, 이차적인 혈전 정맥염과 여러 장기를 침범하는 전이성 색전이 특징이다. 1940년대 이후 항생제가 도입되면서 “잊혀진” 질환이었지만, 영상의학 검사가 발달하면서 Lemierre 증후군의 보고가 많아지고 있다. 건강한 16세 남자 환자가 입인두 감염 후에 5일간 지속된 발열과 경부 강직으로 응급실에 내원하였다. 입원 초기에는 뇌수막염에 준하여 치료를 시작하였으나 추후 경부 전산화 단층촬영에서 오른쪽 속목정맥 안의 혈전이 발견되어 Lemierre 증후군으로 진단하였다. 환자는 입원 2일째 갑자기 복시를 호소하였으나 곧 증상이 호전되었으며, 그 외 전이성 색전에 의한 증상은 발견되지 않았다. 총 3주간의 항생제 치료 후 정맥 내 혈전이 소실된 것을 경부 초음파로 확인하고 치료를 종료하였다.