



Fabrication of a CAD/CAM monolithic zirconia crown to fit an existing partial removable dental prosthesis

Janghyun Paek¹, Kwantae Noh¹, Ahran Pae¹, Hyeonjong Lee², Hyeong-Seob Kim^{1*}

¹Department of Prosthodontics, School of Dentistry, Kyung Hee University, Seoul, Republic of Korea

²Department of Prosthodontics, Graduate School, Kyung Hee University, Seoul, Republic of Korea

Fabricating a surveyed prosthesis beneath an existing partial removable dental prosthesis (PRDP) is a challenging and time-consuming procedure. The computer-aided design/computer-assisted manufacturing (CAD/CAM) technology was applied to fabricate a retrofitted, surveyed zirconia prosthesis to an existing PRDP. CAD/CAM technology enabled precise and easy replication of the contour of the planned surveyed crown on the existing abutment tooth. This technology ensured excellent adaptation and fit of newly fabricated crown to the existing PRDP with minimal adjustments. In this case report, a seventy-year-old male patient presented with fractured existing surveyed crown. Because the existing PRDP was serviceable, new crown was fabricated to the existing PRDP. [*J Adv Prosthodont* 2016;8:329-32]

KEYWORDS: Computer-aided design/computer-assisted manufacturing (CAD/CAM); Monolithic zirconia crown; Retrofitting; Surveyed crown; Replication

INTRODUCTION

Dental caries are commonly found under existing fixed partial dentures, and the occurrence of recurrent carries necessitates installation of a new crown. However, when an existing partial removable dental prosthesis (PRDP) is clinically acceptable, retrofitting a new prosthesis to the existing PRDP is required. Various techniques have been introduced to make a restoration conform to the existing PRDP.¹⁻⁵ Silberman utilized mini impression technique with metal clasp assembly to make a crown under existing PRDP. Additional impression around abutment and clasp assembly was performed to make metal clasp assembly used as a guide for new crown.³ Helvey used a ceramic material with Pyrex glass filler and a template to fabricate a new crown on the existing abutment tooth for a removable partial denture.⁵

Corresponding author:
Hyeong-Seob Kim
Department of Prosthodontics, School of Dentistry, Kyung Hee University
26 Kyunghye-daero, Dongdaemun-gu, Seoul 02447, Republic of Korea
Tel. +8229589340; e-mail, odontopia@khu.ac.kr
Received September 14, 2015 / Last Revision May 23, 2016 / Accepted
May 30, 2016

© 2016 The Korean Academy of Prosthodontics
This is an Open Access article distributed under the terms of the Creative Commons Attribution Non-Commercial License (<http://creativecommons.org/licenses/by-nc/3.0>) which permits unrestricted non-commercial use, distribution, and reproduction in any medium, provided the original work is properly cited.

Fabricating a surveyed prosthesis for an existing PRDP is a complicated and laborious procedure. The process can become more complicated when the tooth is located anteriorly and the patient requests a tooth-colored restoration. Metal ceramic crown fabrication is difficult and time-consuming, as repeated surveying in the laboratory is required to plan and establish the correct contours in the definitive restoration.^{6,7} By scanning and duplicating the planned shape and contour, computer-aided designs/computer-assisted manufacturing (CAD/CAM) technology can be useful when fabricating a surveyed crown.^{7,8} In this case report, a seventy-year-old male patient presented with fractured surveyed crown. Because the existing PRDP was serviceable, new crown was to be fabricated to the existing PRDP. The purpose of the present article was to describe a dental technique for fabricating and retrofitting a monolithic zirconia surveyed prosthesis to an existing PRDP by utilizing CAD/CAM technology.

CASE REPORT

1. Prepare the left central incisor for the monolithic zirconia crown with a deep chamfer margin and appropriate reduction (Fig. 1). Uniform and circumferential tooth reduction was performed by 1.5 mm and the incisal reduction of 2 mm was conducted. All preparations were rounded.

2. Ensure adequate reduction of the crown and recheck the stability of the framework by reseating the framework intraorally.
3. Make a definitive impression of prepared left central incisor with vinyl polysiloxane impression material (Imprint; 3M ESPE, St. Paul, MN, USA).
4. In the laboratory, fabricate the working cast with a Type V dental stone (Die-Keen; Heraeus Kulzer LLC, South Bend, Ind) and make the abutment die.
5. With the framework in the patient's mouth, add auto polymerizing acrylic resin (Pattern Resin LS; GC America, Alsip, IL, USA) to the abutment tooth underneath the framework. As the pattern resin is added, ensure that the cingulum rest seat, labial retentive area, and guiding plane are properly registered. Wipe the excess material from the PRDP framework before it polymerizes (Fig. 2).

6. Remove the registered resin pattern from the mouth. After trimming the excess material and ensuring registration of the cingulum rest seat, labial retentive area, and guiding plane, set aside the resin pattern for the next laboratory procedures (Fig. 3).
7. Scan the die with a digital scanner (D800; 3Shape, Copenhagen, Denmark). The first scan is performed to fabricate the digitized die.
8. Place the resin pattern on the die to verify proper seating.
9. Proceed with the second scan with the resin pattern placed on the die (Fig. 4). Merge the computer data of the digitized die and the planned crown for dual scan procedure.
10. Design the definitive zirconia crown to duplicate the resin pattern in the software (Dental System; 3Shape, Copenhagen, Denmark).
11. Transfer the finished design of the definitive crown and

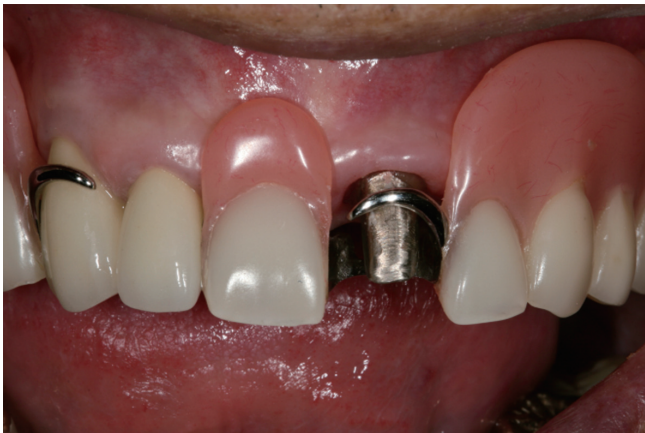

Fig. 1. Buccal view of abutment preparation for the existing PRDP. Tooth preparation finalized for impression. PRDP framework evaluated intraorally to ensure adequate reduction for the monolithic zirconia crown.

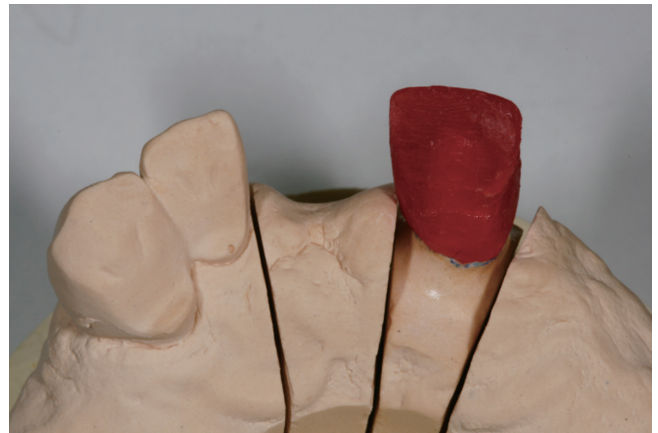

Fig. 3. Resin pattern evaluated on the working cast die to verify the fit (lingual view).

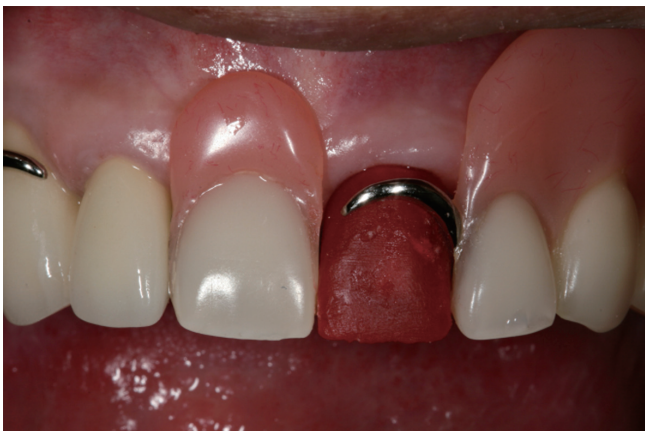

Fig. 2. Resin pattern fabricated and placed under the framework for the monolithic zirconia crown. Cingulum rest seat, labial retentive undercut, and guiding plane are captured in the resin pattern.

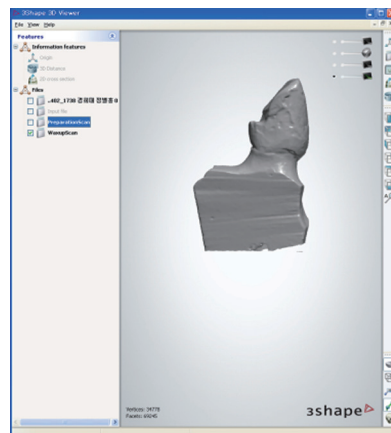


Fig. 4. Image of digitized crown after being scanned. Duplicated image of maxillary left central incisor on the prepared tooth of the definitive cast.

mill the crown from a monolithic zirconia A2 shade block (Prettau; Zirkozahn GmbH) (Fig. 5).

12. After the milling procedure is complete, apply coloring liquid to reproduce the A2 shade and natural look. Apply gray violet stain to the incisal area, brown stain in body, and white stain in internal surface to mask the metal post. Dry the stains for 30 minutes.
13. After custom staining, place the crown in Zirkozhan sintering furnace (Zirkonofen 600; Zirkozahn GmbH) at 1600°C, according to the manufacturer's instructions.
14. Adjust the contour of the sintered zirconia crown and characterize the crown with a staining kit for a natural look (Fig. 6).
15. Evaluate the definitive crown intraorally to verify the fit. Ensure the fit of the cingulum rest, guiding plane, proper contact of the labial clasp, marginal adaptation, and the fit to the PRDP framework (Fig. 7, Fig. 8).

16. After verification of the fit, trial placement, and patient's approval, lute the monolithic zirconia crown using a resin cement (Rely X Unicem; 3M, St. Paul, MN, USA), according to the manufacturer's instructions.

DISCUSSION

Numerous techniques have been described in the literatures for cast metal and ceramometal restorations. However, problems were encountered in an attempt to replicate ideal contours, rest seats, guiding planes, and undercuts of the surveyed crown, especially in metal-ceramic restorations when applying porcelain.⁹ Due to shrinkage of porcelain after firing in the furnace, it is hard to obtain precise fit between retentive clasp and buccal contour of retrofitted surveyed crown. These procedures require a considerable amount of time for chairside adjustment. In the present

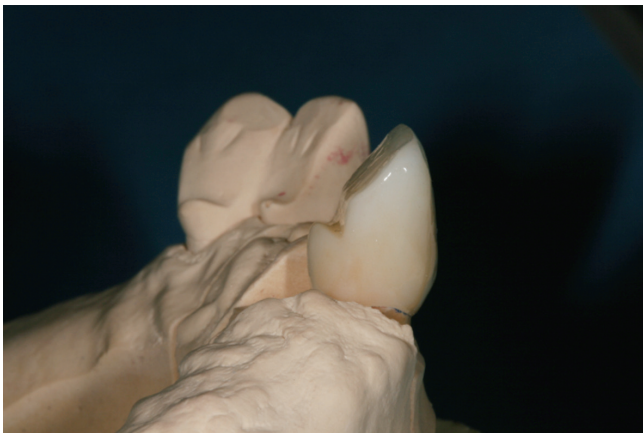


Fig. 5. Distal view of the monolithic zirconia crown.

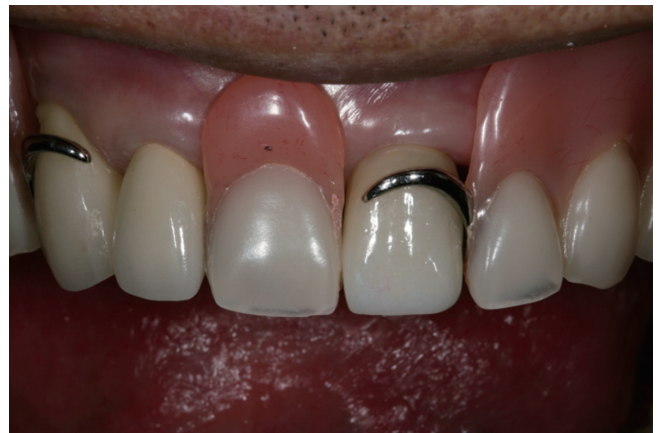

Fig. 7. Framework with definitive zirconia restoration (buccal view). The monolithic zirconia crown was adjusted and cemented.

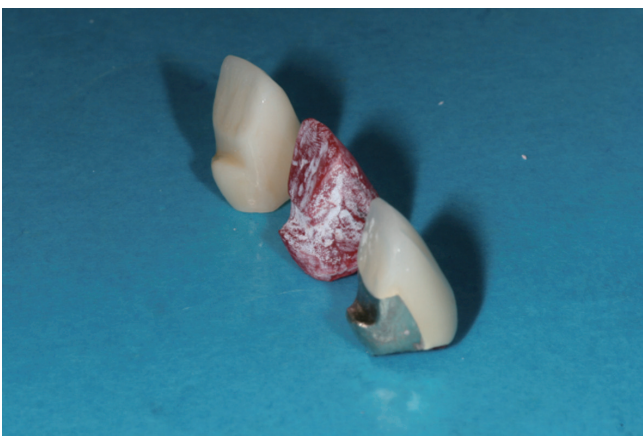

Fig. 6. Comparing the contours of the previous crown and resin pattern with the newly fabricated zirconia crown.

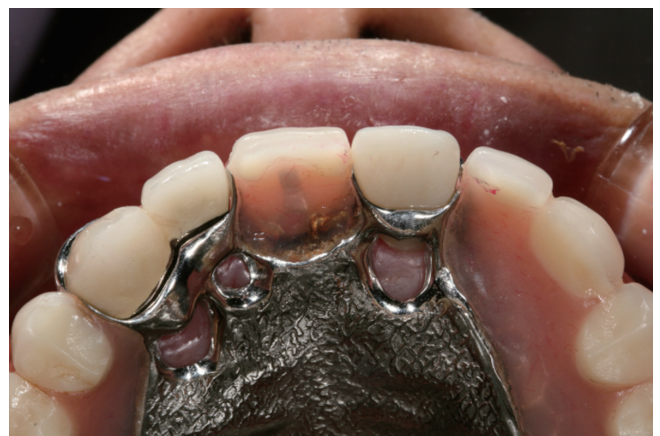

Fig. 8. Framework with definitive restoration (occlusal view). The retrofitted zirconia crown is well adapted under the existing PRDP.

article, a simplified technique that makes use of a full-contour monolithic zirconia crown was introduced. Due to CAD/CAM technology, the adjustments were minimal, thus eliminating the considerable amount of time for chair-side adjustment.

The advantage of CAD/CAM technology includes the ease and accuracy of replicating details such as guiding planes, rest seats, and retentive undercuts. The accuracy of dental CAD/CAM systems has been progressively advanced over the past 50 years.¹⁰ The precise scanning technique facilitates accurate replication of the contour with minimal adjustment. Moreover, the digital data of newly designed crown can be shown to the patient, which will enhance the communication between the clinician and the patient. Not only easy communication but also easy storage of digital data is another important advantage of CAD/CAM technology. The existing PRDP and newly fabricated surveyed crown function satisfactorily and show a favorable prognosis.

Due to the limitation of subgingival intraoral scanning, a definitive impression was taken with a conventional gingival cord and elastomeric impression material to make a working cast. Further development is expected to overcome this limitation of subgingival scanning. If margin could had been fully exposed by using gingival retraction cord, abutment tooth could be scanned using an intraoral scanner without definitive stone cast. Another potential limitation is the opacity of the monolithic zirconia crown; however, various staining methods have been applied to mask the limitation. In this certain case, the esthetics was not of a big importance, since the clasp was located on top of zirconia crown. However, in esthetically demanding cases, the esthetic limitation of full contour zirconia crown should be addressed and considered thoroughly.

CONCLUSION

Retrofitting surveyed crown could be fabricated with various methods. In this case, pattern resin and CAD-CAM technique were used to fabricate retrofitted monolithic zirconia crown that is suitable to pre-existing PRDP. Monolithic zirconia crown has high flexural strength, appropriate esthetic property, and accuracy. CAD-CAM technique could be considered as a novel method to fabricate retrofitted surveyed crown.

ORCID

Janghyun Paek <http://orcid.org/0000-0002-1286-3140>

Kwantae Noh <http://orcid.org/0000-0003-3480-7737>

Ahran Pae <http://orcid.org/0000-0001-8758-0754>

Hyeonjong Lee <http://orcid.org/0000-0002-5660-9515>

Hyeong-Seob Kim <http://orcid.org/0000-0002-0964-0288>

REFERENCES

1. Samani S, Mullick SC. A new crown for an existing removable partial prosthesis. *Quintessence Int* 1979;10:35-40.
2. Macpherson JR, Evans DB. Fabricating crowns to fit existing removable partial dentures: an illustration of two techniques. *J Prosthodont* 1993;2:199-205.
3. Silberman DM. An indirect procedure for making a crown under an existing partial denture. *J Prosthet Dent* 1993;69:631-3.
4. Hansen CA, Russell MM. Making a crown to fit accurately under an existing removable partial denture clasp assembly. *J Prosthet Dent* 1994;71:206-8.
5. Helvey GA. Retrofitting crowns to an existing removable partial denture clasp: a simple technique. *J Prosthet Dent* 2002;87:399-402.
6. Seals RR Jr, Stratton RJ. Surveyed crowns: a key for integrating fixed and removable prosthodontics. *Quintessence Dent Technol* 1987;11:43-9.
7. Marchack BW, Chen LB, Marchack CB, Futatsuki Y. Fabrication of an all-ceramic abutment crown under an existing removable partial denture using CAD/CAM technology. *J Prosthet Dent* 2007;98:478-82.
8. Yoon TH, Chang WG. The fabrication of a CAD/CAM ceramic crown to fit an existing partial removable dental prosthesis: a clinical report. *J Prosthet Dent* 2012;108:143-6.
9. Warnick ME. Cast crown restoration of a badly involved abutment to fit an existing removable partial denture. *Dent Clin North Am* 1970;14:631-44.
10. Rudolph H, Salmen H, Moldan M, Kuhn K, Siewhardt V, Wöstmann B, Luthardt RG. Accuracy of intraoral and extraoral digital data acquisition for dental restorations. *J Appl Oral Sci* 2016;24:85-94.