

IMAGES

Split-Rib Cranioplasty Using a Patient-Specific Three-Dimensional Printing Model

Jong Chan Kim¹, In Pyo Hong²

¹Department of Plastic and Reconstructive Surgery, National Medical Center, Seoul; ²Department of Plastic and Reconstructive Surgery, Eulji University Hospital, Eulji University School of Medicine, Daejeon, Korea

Correspondence: In Pyo Hong
Department of Plastic and Reconstructive Surgery, Eulji University Hospital, Eulji University School of Medicine, 95 Dunsanse-ro, Seo-gu, Daejeon 35233, Korea
Tel: +82-42-611-3029, Fax: +82-42-259-1111, E-mail: nmcp@unitel.co.kr

No potential conflict of interest relevant to this article was reported.

Received: 18 Nov 2015 • Revised: 10 May 2016 • Accepted: 24 May 2016
pISSN: 2234-6163 • eISSN: 2234-6171
<http://dx.doi.org/10.5999/aps.2016.43.4.379>
Arch Plast Surg 2016;43:379-381



Copyright © 2016 The Korean Society of Plastic and Reconstructive Surgeons
This is an Open Access article distributed under the terms of the Creative Commons Attribution Non-Commercial License (<http://creativecommons.org/licenses/by-nc/4.0/>) which permits unrestricted non-commercial use, distribution, and reproduction in any medium, provided the original work is properly cited.

The reconstruction of cranial bone defects is necessary not just for the protection of the brain, but also for aesthetics. Cranial bone reconstruction may be conducted using autologous or synthetic bone tissue [1]. When synthetic bone is utilized, the reconstruction of large defects is possible, and problems with the donor area are eliminated. However, other possible problems include allergic reaction, infection, and implant exposure [2]. The reconstruction of cranial bone defects using autologous bone tissue has the advantages of avoiding both allergic reaction and implant exposure, but potential problems include donor site morbidity, prolonged surgical time, unpredictable resorption, and asymmetrical bone shape [3,4]. The advantages and disadvantages of these two methods complement each other.

With the development of three-dimensional printing (3D printing) technology, the prefabrication of patient-specific implants is now helping to achieve a symmetrical cranial shape, and minimize tissue damage [5]. While surgical methods utilizing the latest in 3D printing technology have proven to be a great help in producing alloplastic material for cranioplasty, to the author's knowledge, there have been no reports of surgery using 3D printing for methods of grafting autologous bone tissue.

Accordingly, by conducting autologous cranioplasty using 3D printing, the authors obtained favorable results both functionally and aesthetically, which are presented here.

A sixteen-year-old patient who had suffered cerebral hemorrhage after being injured in a traffic accident underwent a two-stage extensive decompressive craniectomy. One area was reconstructed using preserved bone fragments, but in another area, in which the bone fragments had not been preserved, a 14 cm × 12 cm skull defect remained (Fig. 1). Considering the fact that the patient was very active and was comparatively young,

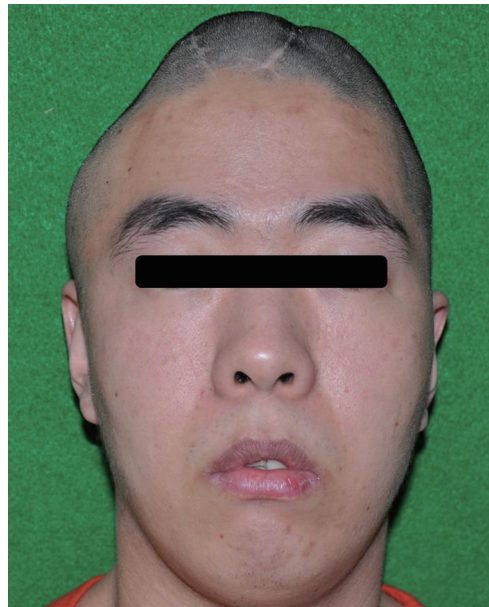


Fig. 1. Preoperative view. There is a large skull defect 14 × 12 cm in size.

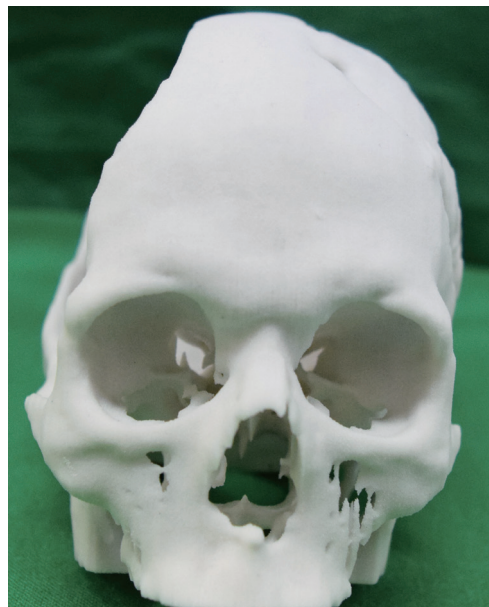

Fig. 2. Three-dimensional (3D) printing model of the patient was made using a 3D computed tomography scan.

a plan was devised to perform a split-rib autologous graft. In order to harvest the portion of rib bone with precisely matching curvature, a rib and skull model was printed from preoperative 3D-computed tomography (CT) scans of the patient using 3D printing technology (Fig. 2). The machine used for 3D printing in this study's case was 3D Systems ProJet 660Pro. This is not a model constructed for medical use, but rather a machine used mainly for the making of ordinary commercial test products. After

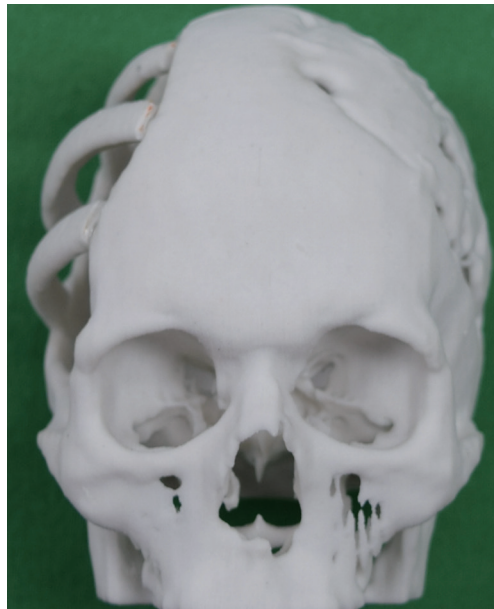

Fig. 3.

Three-dimensional (3D) model was used to determine the minimum amount and portion of rib that would also be the most ideal aesthetically. After determining the ideal portion, a cranioplasty simulation was conducted using the 3D model.

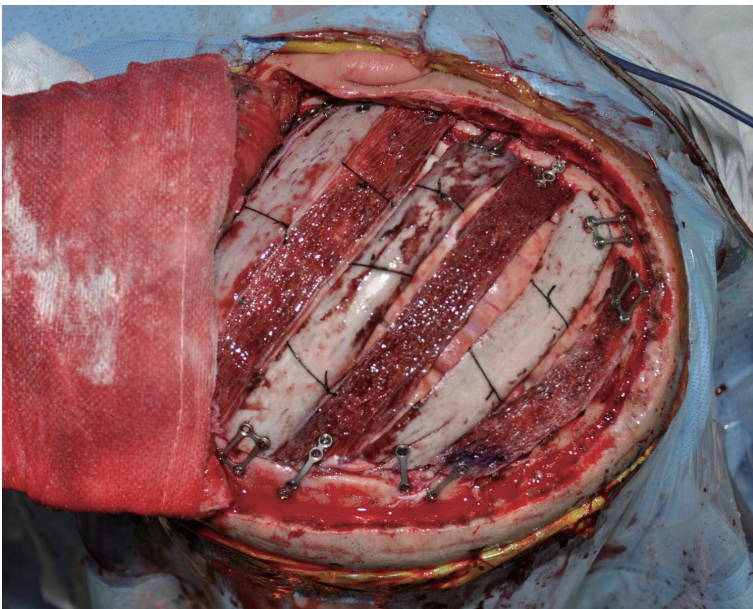


Fig. 4.

Simulation was used to locate the rib portions that would make ideal bone grafts, and after these were excised, cranioplasty was performed.

simple conversion of the filename extension of the CT image file, a patient-specific 3D model was printed. The printed model was used to compare the skull defect with the shape of the ribs, and a design was preoperatively marked on a portion of the right seventh and ninth ribs, the most ideal graft candidates (Fig. 3). Afterwards, there was a need to select a landmark in order to excise a portion of rib bone that precisely matched the bone portion simulated in the operating room. While the sternocostal joint and costochondral junction are commonly used as landmarks for rib bones, we could not use them as landmarks because cartilage is not printed in a bone 3D printing model.

However, the seventh and ninth ribs have considerably long cartilage, so it is impossible to find this part in the patient's body by exploration with the fingers. An important landmark that we used was the highest point of the seventh and ninth ribs in a lateral position. We calculated the distance from this point to the front and back side of the rib bone to be excised, and after marking the area to be excised on the skin. Then, we performed infiltration with an ink-filled syringe and marked the precise excision area up to the area adjacent to the bone. After this, the periosteal layer on the rib was elevated, exposing the bony portions of the rib as designed, and minimal bone harvesting was accomplished. The harvested ribs were split in two. Reconstruction of the skull bone defect was then conducted using the split-rib bone graft as simulated (Fig. 4). After surgery, the cranioplasty was successful, and none of the cases experienced respiratory problems. The patients nearly reached aesthetic symmetry (Fig. 5).

In cases such as the one in this study where the defect size is large, the precise amount and portion of the rib to be resected must be determined. The current method of only using 3D-CT images has the limitation of depending on a visual estimation, and thus the amount of rib to be resected must be larger than the size of the defect, which can lead to donor site complications, and pneumothorax is also a risk. Besides, there is also a great possibility that reconstruction will not be aesthetically satisfactory due to a difference in the curvature of the rib and the skull. Cranioplasty utilizing synthetic materials has the advantage of not causing donor site complications, as well as being able to achieve perfect symmetry through the creation of patient-specific implants using 3D printing. However, there are potential complications with this procedure,

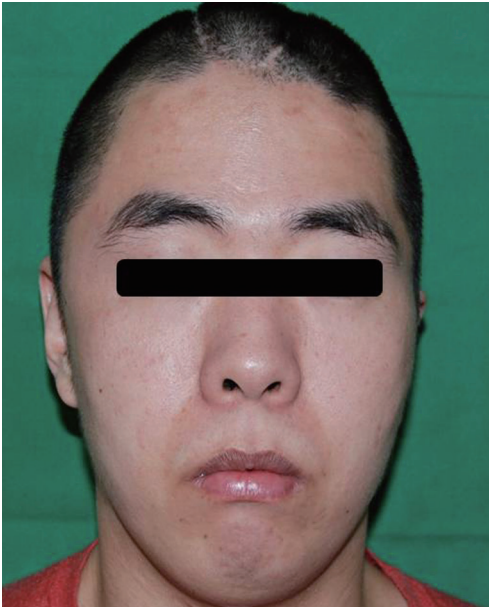

Fig. 5.
Postoperative view after one month.

including infection and allergic reaction, and its use should definitely be avoided in the case of children, whose bones have not yet stopped growing. In the case of the sixteen-year-old patient in this study, while alloplastic cranioplasty was possible, as the growth of the skull bone was nearly complete, the patient and his guardian decided upon autologous cranioplasty. In cases of large autologous cranioplasty, such as the one reported in this study, using a patient-specific 3D model as a preoperative procedure can have several advantages. First, donor site complications can be reduced by performing a simulated operation using the 3D model in advance. Respiratory complications that can occur in split-rib cranioplasty can also be reduced with minimal rib resection. Second, aesthetically satisfactory results can be achieved. If resection is performed after preoperatively determining the ideal rib portion that best matches the defect's curvature through a 3D model, the surgeon can find the ideal portion of rib bone that will cover the skull defect.

Medical limitations can be overcome when new technology is introduced. Rapid advances in 3D printing technology have positively affected its application in the field of cosmetic surgery. Using various patient-specific 3D models in alloplastic cranioplasty addresses a number of limitations for various procedures. However, the application of 3D printing technology in autologous cranioplasty is limited. This study reports notable results when a 3D

printing model is utilized in autologous cranioplasty. Further studies are needed to verify the effectiveness of 3D printing technology in autologous cranioplasty.

References

1. Aydin S, Kucukyuruk B, Abuzayed B, et al. Cranioplasty: review of materials and techniques. *J Neurosci Rural Pract* 2011;2:162-7.
2. Moreira-Gonzalez A, Jackson IT, Miyawaki T, et al. Clinical outcome in cranioplasty: critical review in long-term follow-up. *J Craniofac Surg* 2003;14:144-53.
3. Gladstone HB, McDermott MW, Cooke DD. Implants for cranioplasty. *Otolaryngol Clin North Am* 1995;28:381-400.
4. Iwama T, Yamada J, Imai S, et al. The use of frozen autogenous bone flaps in delayed cranioplasty revisited. *Neurosurgery* 2003;52:591-6.
5. Dean D, Min KJ, Bond A. Computer aided design of large-format prefabricated cranial plates. *J Craniofac Surg* 2003;14:819-32.

Post-Traumatic Cutaneous Meningioma

Francisco Javier Pacheco Compañía¹, José Midón Míguez¹,
Edgar Mauricio Avellaneda Oviedo¹,
Eladio Busto Lodeiro²

Departments of ¹Plastic Surgery and ²Pathology, Complejo Hospitalario Universitario de A Coruña, A Coruña, Spain

Correspondence: Francisco Javier Pacheco Compañía
Department of Plastic Surgery, Complejo Hospitalario Universitario de A Coruña, Calle As Xubias, N° 84. CP: 15006, A Coruña, Spain
Tel: +34-651517226, Fax: +34-952702871
E-mail: javipacheco25@hotmail.com

No potential conflict of interest relevant to this article was reported.

Received: 23 Oct 2015 • Revised: 31 Jan 2016 • Accepted: 15 Feb 2016
pISSN: 2234-6163 • eISSN: 2234-6171
<http://dx.doi.org/10.5999/aps.2016.43.4.381>
Arch Plast Surg 2016;43:381-384



Copyright © 2016 The Korean Society of Plastic and Reconstructive Surgeons
This is an Open Access article distributed under the terms of the Creative Commons Attribution Non-Commercial License (<http://creativecommons.org/licenses/by-nc/4.0/>) which permits unrestricted non-commercial use, distribution, and reproduction in any medium, provided the original work is properly cited.

Neurological tumors pose considerable challenges from the point of view of diagnosis and therapeutic management. Their location makes them difficult to study and to approach surgically, especially when